

# MEDICAL TERMINOLOGY

AN INTERACTIVE APPROACH

LOUIS 

# Medical Terminology: An Interactive Approach



# MEDICAL TERMINOLOGY: AN INTERACTIVE APPROACH

An Interactive Approach

KENDRA ANSPAUGH; SARAH GONCALVES; EMILY JACKSON-OSAGIE; AND SANDRA Q. SMITH

KHALIL EL-BATHY

LOUIS: The Louisiana Library Network



*Medical Terminology: An Interactive Approach* Copyright © 2022 by LOUIS: The Louisiana Library Network is licensed under a [Creative Commons Attribution 4.0 International License](https://creativecommons.org/licenses/by/4.0/), except where otherwise noted.

# CONTENTS

Preface	xi
Introduction	1

## Part I. Introduction to Word Parts and Medical Language Rules

Identifying Word Parts in Medical Terms and Language Rules	5
Prefixes	8
Suffixes	11
References	16
Practice	17

## Part II. Directional Terms and Anatomic Planes, Regions, and Quadrants

Regional and Directional Terms	21
Planes, Regions, and Quadrants	29
Body Positions	31
References	36
Practice	37

## Part III. Body Structure, Color, and Oncology

Levels of Organization and Tissue Types	43
Body Cavities, Serous Membranes, and Tissue Membranes	51

Color and Oncology	57
References	59
Practice	60

#### Part IV. Musculoskeletal System

Basic Anatomy & Physiology of the Musculoskeletal System	63
Word Parts and Structural Terms	75
Diseases and Disorders	79
Medical, Surgical, & Viewing Terms and Abbreviations	82
References	89
Practice	91

#### Part V. Nervous System

Anatomy of the Nervous System	95
Word Parts and Structural Terms	106
Diseases and Disorders	110
Medical, Surgical, & Viewing Terms and Abbreviations	113
Practice	116
References	118

#### Part VI. Endocrine System

Basic Anatomy & Physiology of the Endocrine System	121
Word Parts and Structural Terms	126
Diseases and Disorders	128
Medical, Surgical, & Viewing Terms and Abbreviations	131

Practice	134
References	135

## Part VII. Integumentary System

Anatomy of the Integumentary System	139
Physiology of the Integumentary System	142
Word Parts and Structural Terms	148
Medical, Surgical, & Viewing Terms and Abbreviations	152
Diseases and Disorders	155
Practice	158
References	160

## Part VIII. Cardiovascular System—Part I: The Heart

Anatomy of the Heart	163
Physiology of the Heart	167
Word Parts and Structural Terms	171
Diseases and Disorders	174
Medical, Surgical, & Viewing Terms and Abbreviations	176
Practice	179
References	181

## Part IX. Cardiovascular System—Part II: Blood and Blood Vessels

Anatomy of the Blood Vessels	185
Physiology of the Blood Vessels and Blood	188
Word Parts and Structural Terms	195

Diseases and Disorders	198
Medical, Surgical, & Viewing Terms and Abbreviations	200
Practice	203
References	204

## Part X. Cardiovascular System—Part III: The Lymphatic and Immune Systems

Anatomy and Physiology of the Lymphatic System	207
Word Parts and Structural Terms	214
Diseases and Disorders	216
Medical, Surgical, & Viewing Terms and Abbreviations	217
Practice	219
References	220

## Part XI. Respiratory System

Anatomy and Physiology of the Respiratory System	223
Word Parts and Structural Terms	235
Diseases and Disorders	238
Medical, Surgical, & Viewing Terms and Abbreviations	241
Practice	245
References	246

## Part XII. Digestive System

Anatomy of the Digestive System	249
Physiology of the Digestive System	260

Word Parts and Structural Terms	262
Diseases and Disorders	265
Medical, Surgical, & Viewing Terms and Abbreviations	268
Practice	272
References	274

### Part XIII. Urinary System

Anatomy and Physiology of the Urinary System	279
Word Parts and Structural Terms	285
Diseases and Disorders	287
Medical, Surgical, & Viewing Terms and Abbreviations	289
Practice	292
References	294

### Part XIV. Male Reproductive System

Anatomy and Physiology of the Male Reproductive System	299
Word Parts and Structural Terms	303
Diseases and Disorders	306
Medical, Surgical, & Viewing Terms and Abbreviations	308
Practice	311
References	313

### Part XV. Female Reproductive System

Anatomy and Physiology of the Female Reproductive System	317
Word Parts and Structural Terms	322

Diseases and Disorders	325
Medical, Surgical, & Viewing Terms and Abbreviations	327
Practice	330
References	332

## Part XVI. Embryology, Pregnancy, and Neonatology

Fertilization and Childbirth	337
Word Parts and Obstetric & Neonatology Terms	342
Diseases and Disorders	346
Medical, Surgical, & Viewing Terms and Abbreviations	348
Practice	353
References	354

## Part XVII. Eye and Ear

Vision	357
Audition	362
Word Parts and Structural Terms	365
Diseases and Disorders	369
Medical, Surgical, & Viewing Terms and Abbreviations	372
Practice	376
References	378

Appendix A: Checklist for Accessibility	381
---	-----

# PREFACE

---

## The Creation of This Book

This textbook was created as part of the Interactive OER for Dual Enrollment project, facilitated by [LOUIS: The Louisiana Library Network](#) and funded by a \$2 million [Open Textbooks Pilot Program grant from the Department of Education](#).

This project supports the extension of access to high-quality post-secondary opportunities to high school students across Louisiana and beyond by creating materials that can be adopted for dual enrollment environments. Dual enrollment is the opportunity for a student to be enrolled in high school and college at the same time.

The cohort-developed OER course materials are released under a license that permits their free use, reuse, modification and sharing with others. This includes a corresponding course available in [MoodleNet](#) and [Canvas Commons](#) that can be imported to other Learning Management System platforms. For access/questions, contact [Affordable Learning Louisiana](#).

If you are adopting this textbook, we would be glad to know of your use via this [brief survey](#).

This textbook offers students the ability to learn basic medical terminology to prepare them for education and a profession in the medical field. This text book has been adapted from the [Building a Medical Terminology Foundation](#) OER textbook by Kimberlee Carter and Marie Rutherford, which was adapted from the [OpenStax Anatomy and Physiology](#) textbook by Betts et al. Changes were made to the *Building a Medical Terminology Foundation* textbook to better suit the needs of our specific learners. These changes include the following:

- Some anatomy and physiology content was deemed excessive relative to the goals of a medical terminology textbook and was therefore removed.
- Interactive H5P elements that corresponded to this excessive anatomy and physiology content were also removed accordingly.
- The skeletal and muscular systems are combined into a single chapter.
- Separate chapter sections were created for structural terms and word parts, diseases and disorders, and medical, surgical & viewing terms and abbreviations. The word lists in these sections were also expanded from the original text.
- Individual chapters were divided and modularized on Pressbooks to reduce the need to scroll and to allow students to leave and return to the text as they need without losing their place in the text.
- When possible, images were replaced with images that provided a more diverse representation of people.

- The term “gender” was changed to “sex” (see the [University of Texas at Austin Dell Medical School Inclusive Language Guidelines](#) for more details on this decision).
- A short comparison of the male and female pelvic bones was added to inform the learner of the distinction between the two since the male skeleton is often presented as the universal form when it is not.

Despite these changes, we thank the original authors for all of their prestigious work.

## Review Statement

This textbook and its accompanying course materials went through two review processes.

Peer reviewers, coordinated by Jared Eusea, River Parish Community College, used an online course development standard rubric for assessing the quality and content of each course to ensure that the courses developed through Interactive OER for Dual Enrollment support online learners in that environment. The evaluation framework reflects a commitment to accessibility and usability for all learners.

Reviewers:

- Constance Chemay
- Iris Henry
- Sarita James

The Institute for the Study of Knowledge Management in Education (ISKME) collaborated with LOUIS to review course materials and ensure their appropriateness for dual enrollment audiences. Review criteria were drawn from factors that apply across dual enrollment courses and subject areas, such as determining appropriate reading levels, assessing the fit of topics and examples for high school DE students; applying high-level principles for quality curriculum design, including designing for accessibility, appropriate student knowledge checks, and effective scaffolding of student tasks and prior knowledge requirements, addressing adaptability and open educational practices, and principles related to inclusion and representational social justice.

Reviewers:

- Adrienne Abel
- Eliska Davis

## Book Citations

Betts, J.G., et al. (2013). *Anatomy and Physiology*. OpenStax. <http://cnx.org/content/col11496/latest/>

Carter, K., & Rutherford, M. (2020). *Building a Medical Terminology Foundation*. eCampus Ontario. <https://ecampusontario.pressbooks.pub/medicalterminology/>



# INTRODUCTION

---

This textbook is designed to teach medical terminology, the language of medicine, in an engaging and meaningful way. Learning medical terminology will allow the learner to more easily understand the language of medicine and utilize this knowledge throughout their academic and medical-based career. While learning medical terms in this course, the learner will also learn basic anatomy and physiology, as well as basic diseases and professions dealing with each body system.

Chapters 1-3 introduce the learner to the way that word parts are put together and other relevant terminology. Chapters 4-17 review separate body systems and provide a brief overview of the anatomy and physiology of the system followed by word list sections. The body system chapters begin with a short video that will introduce the learner to the system. On some occasions, these videos are placed further in the chapter. Chapters also contain words in bold that are meant to catch the reader's eye, letting them know this is a new important term. Many of these words are mentioned later in the chapter as well. Each chapter concludes with a set of references used to create the chapter and a practice section containing interactive elements and practice exercises. The combination of word lists and their definitions with interactive content and real-world scenarios will aid the learner to understand, retain, and utilize the information within flashcards with audio options, images, drag-and-drop exercises, and more.

Upon completion of the textbook, students will be able to:

1. Analyze, build, and define medical terms correctly using knowledge of word parts
2. Demonstrate proper pronunciation and spelling of medical terminology
3. Utilize medical terminology on body systems
4. Decipher medical terms and abbreviations related to health professions
5. Select correct medical terms and basic medical terms to facilitate communication in the medical setting

In order to accomplish these outcomes, the authors recommend reading the chapter in full. Next, study the word parts and the full words related to the body system. Then complete practice exercises at the end of each chapter in order to test yourself. Creating note cards for each chapter is recommended.



## PART I

# INTRODUCTION TO WORD PARTS AND MEDICAL LANGUAGE RULES

## Learning Objectives

When completing this chapter, the learner will be able to do the following:

- Identify the various word parts in medical terminology
- Divide words into prefixes, suffixes, combining forms, and combining vowels
- Apply spelling and pronunciation rules to creating words from prefixes, word roots, combining vowels, and suffixes
- List commonly used prefixes and suffixes and their meaning

## Origins of Medical Terminology

Words used in medical terminology come from four different sources:

- Greek and Latin words
  - Examples: **osteoarthritis** from Greek; **arterial** from Latin
- Acronyms: terms that are built from the first letters of a phrase
  - Examples: **AIDS** from acquired immunodeficiency syndrome; **CT** from computed tomography
- Eponyms: terms named after a person or place
  - Examples: **Ebola virus** from the Ebola River; **Parkinson's disease** from James Parkinson, who first described the disease in medical literature

- Modern English
  - Examples: **peak flow meter; nuclear medicine scanner**

Of these four sources, the majority of words covered in this book will come from Greek and Latin word roots. As each body system is covered in this book, you will learn the important word roots for that system.

# IDENTIFYING WORD PARTS IN MEDICAL TERMS AND LANGUAGE RULES

---

Language rules are the best place to start when building a medical terminology foundation. Many medical terms are built from word parts and can be translated literally. At first, literal translations sound awkward, but once you build a medical vocabulary and become proficient at using it, translation will get much easier.

Since you are at the beginning of building your medical terminology foundation, stay literal when applicable. It should be noted that as with all language rules, there are always exceptions, and we refer to those as “rebels.” So let’s begin by analyzing the language rules for medical terminology.

## Combining Forms, Prefixes, and Suffixes

In each chapter of this book that covers a new body system, you will see lists of combining forms, prefixes, and suffixes before the new terms are introduced.

Combining forms are written with a word root followed by a slash mark (/) and combining vowel. The combining vowel is used to join word roots together and is sometimes used before suffixes to aid in pronunciation.

Examples

**gastr/o**, meaning “stomach”

Prefixes are sometimes added to the beginning of a medical term to make its meaning clear.

Examples

**sub-**, meaning “under”

Suffixes are sometimes added to the end of a medical term to make its meaning clear.

Examples

**-logy**, meaning “study of”

## Language Rules for Building Medical Terms

Rule 1: When combining two combining forms, you keep the combining vowel.

Rule 2: When combining a combining form with a suffix that begins with a consonant, you keep the combining vowel.

Example

**Gastr/o/enter/o/logy**—The study of the stomach and the intestines

- Following rule 1, when we join the combining form gastr/o (meaning stomach) with the combining form enter/o (meaning intestines), we keep the combining vowel o.
- Following rule 2, when we join the combining form enter/o (meaning intestines) with the suffix -logy (that begins with a consonant and means the study of), we keep the combining vowel o.

Rule 3: When joining a combining form with a suffix that begins with a vowel, you drop the combining vowel.

Rule 4: A prefix goes at the beginning of the word, and no combining vowel is used.

### Example

**Intra/ven/ous**—Pertaining to within the vein

- Following rule 3, notice that when joining the combining form ven/o (meaning vein) with the suffix -ous (that starts with a vowel and means pertaining to), we drop the combining vowel o.
- Following rule 4, the prefix intra- (meaning within) is at the beginning of the medical term with no combining vowel used.

Rule 5: When defining a medical word, start with the suffix first and then work left to right stating the word parts. You may need to add filler words. As long as the filler word does not change the meaning of the word, you may use it for the purpose of building a medical vocabulary. Once you begin to apply the word in the context of a sentence, deciding which filler word to use will become easier.

### Example

**Intra/ven/ous**—pertaining to within the vein or pertaining to within a vein.

- Following rule 5, notice that we start with the suffix -ous (that means pertaining to) then we work left to right starting with the prefix intra- (meaning within) and the combining form ven/o (meaning vein).
- Notice that we have used two different filler words that have the same meaning.
- In these examples, we do not have the context of a full sentence. For the purpose of building a medical terminology foundation, either definition is accepted.

# PREFIXES

---

Prefixes are located at the beginning of a medical term. The prefix alters the meaning of the medical term. It is important to spell and pronounce prefixes correctly.

Many prefixes that you find in medical terms are common English-language prefixes. A good technique to help with memorization is the following:

- Start by reviewing the most common prefixes.
- Consider common English-language words that begin with the same prefixes.
- Compare them to the examples of use in medical terms.

We will be seeing these prefixes mentioned again in this book, but they are presented here as a reference.

<b>PREFIX</b>	<b>MEANING</b>	<b>EXAMPLE OF USE IN MEDICAL TERMS</b>
a-, an	no, not, without, negates the meaning	atypical, anoxia
ab-	away from; from	abduction
ad-	toward, at, increase, on, toward	adduction
ante-	before	ante partum
anti-	against, opposing	antipsychotic
bi-, bin-	two, twice, double	bilateral, binocular
brady-	slow	bradycardia
de-	from, down, away from	dehydrate
dia-	through, complete	dialysis
dys-	painful, abnormal, difficult, labored	dysphagia
endo-	within, in	endotracheal
epi-	on, upon, over	epidermis
eu-	normal, good	eupnea
hemi-	half	hemicolectomy
hyper-	above, excessive	hyperthyroidism
inter-	between	intercostal
intra-	within, in	intramuscular
macro-	large, long	macrocephalus
meta-	after, beyond, change	metacarpals
micro-	small	microscope
multi-	many	multipara
neo-	new	neonate
nulli-	none	nulligravida
pachy-	thick, thickening, thickened	pachyderma
pan-	all, total	pancytopenia
para-	beside, beyond, around, abnormal	parathyroid glands
per-	through	percutaneous
peri-	surrounding (outer)	peripheral vision
poly-	many, much	polymyositis
post-	after	postpartum

---

<b>PREFIX</b>	<b>MEANING</b>	<b>EXAMPLE OF USE IN MEDICAL TERMS</b>
pre-	before	prenatal
pro-	before	prognosis
sub-	below, under	subcutaneous
supra-	above	suprascapular
sym-, syn-	together, joined	symphysis
tachy-	fast, rapid	tachycardia
trans-	through, across, beyond	transdermal
tri-	three	triceps
uni-	one	unilateral

---

# SUFFIXES

---

Suffixes are word parts that are located at the end of words. Suffixes can alter the meaning of medical terms. It is important to spell and pronounce suffixes correctly.

Many suffixes in medical terms are common English-language suffixes. Suffixes are not always explicitly stated in the definition of a word. It is common that suffixes will not be explicitly stated when defining a medical term in the workplace. However, when transcribing or reading medical reports, the suffix is always clearly written. In order to properly spell and pronounce medical terms, it is helpful to learn the suffixes.

We will be seeing these suffixes mentioned again in this book, but they are presented here as a reference.

SUFFIX	MEANING	EXAMPLE OF USE IN MEDICAL TERMS
-a	noun ending, no meaning	leukoderma
-ac	pertaining to	cardiac
-ad	toward	dorsad
-algia	pain	myalgia
-amnios	amnion, amniotic fluid	oligohydramnios
-apheresis	removal	plasmapheresis
-ar	pertaining to	appendicular
-ary	pertaining to	coronary
-asthenia	weakness	myasthenia gravis
-carcinoma	cancerous tumor	adenocarcinoma
-cele	hernia, protrusion, swelling	hydrocele
-centesis	surgical puncture to aspirate fluid	amniocentesis
-crine	to secrete	exocrine
-cyesis	pregnancy	pseudocyesis
-cyte	cell	leukocyte
-desis	surgical fixation, fusion	arthrodesis
-drome	run, running	syndrome
-e	noun ending, no meaning	neonate
-eal	pertaining to	esophageal
-ectasis	stretching out, dilation, expansion	bronchiectasis
-ectomy	excision, surgical removal, cut out	gastrectomy
-emesis	vomiting	hematemesis
-emia	in the blood	anemia
-esis	condition	diuresis
-gen	substance or agent that produces or causes	teratogen
-genic	producing, originating, causing	carcinogenic
-gram	the record, radiographic image	electrocardiogram
-graph	instrument used to record; the record	electrocardiograph
-graphy	process of recording, radiographic imaging	electrocardiography
-ia	condition of, diseased state, abnormal state	tachycardia

<b>SUFFIX</b>	<b>MEANING</b>	<b>EXAMPLE OF USE IN MEDICAL TERMS</b>
-iasis	condition	choledocholithiasis
-iatrist	specialist	psychiatrist
-iatry	specialty, treatment	psychiatry
-ic	pertaining to	cardiac
-ictal	seizure, attack	postictal
-ior	pertaining to	anterior
-ism	state of	hyperthyroidism
-itis	inflammation	colitis
-logist	specialist who studies and treats	oncologist
-logy	study of	cardiology
-lysis	separating, loosening, dissolution	thrombolysis
-malacia	softening	chondromalacia
-megaly	enlarged, enlargement	gastromegaly
-meter	instrument used to measure	thermometer
-metry	measuring, process of measuring	spirometry
-oid	resembling	lipoid
-oma	tumor, swelling	melanoma
-opia	vision	diplopia
-opsy	viewing, process of viewing	biopsy
-osis	abnormal condition, increased number (blood)	erythrocytosis
-ous	pertaining to	intravenous
-paresis	slight paralysis	hemiparesis
-pathy	disease	polyneuropathy
-penia	abnormal reduction in number	erythrocytopenia
-pepsia	digestion	dyspepsia
-pexy	surgical fixation, suspension	colpopexy
-phagia	swallowing, eating	dysphagia
-phobia	aversion, abnormal fear	photophobia
-physis	growth	symphysis
-plasia	formation, development, growth	hyperplasia

SUFFIX	MEANING	EXAMPLE OF USE IN MEDICAL TERMS
-plasm	growth, substance, formation	cytoplasm
-plasty	surgical repair	rhinoplasty
-plegia	paralysis	ophthalmoplegia
-pnea	breathing	dyspnea
-poiesis	formation	leukopoiesis
-ptosis	prolapse, drooping	nephroptosis
-rrhage	excessive bleeding	hemorrhage
-rrhagia	condition of excessive bleeding	rhinorrhagia
-rrhaphy	repairing, suturing	cholecystorrhaphy
-rrhea	discharge, flow	rhinorrhea
-rrhexis	rupture	amniorrhexis
-salpinx	fallopian tube, uterine tube	pyosalpinx
-sarcoma	malignant tumor	rhabdomyosarcoma
-schisis	split, fissure	cranioschisis
-sclerosis	hardening	arteriosclerosis
-scope	instrument used for visual examination	hysteroscope
-scopic	pertaining to visual examination	pelviscopic
-scopy	process of visually examining	gastroscopy
-spasm	sudden, involuntary contraction of muscle	vasospasm
-stasis	stop, control, standing	hemostasis
-stenosis	constriction, narrowing	ureterostenosis
-stomy	creation of artificial opening	nephrostomy
-thorax	chest cavity, chest	hemothorax
-tocia	labor, birth	dystocia
-tome	instrument used to cut	dermatome
-tomy	incision, cut into	laparotomy
-tripsy	surgical crushing	cholecystolithotripsy
-trophy	nourishment, development	hypertrophy
-um	no meaning	endocardium
-uria	urine, urination	nocturia

---

<b>SUFFIX</b>	<b>MEANING</b>	<b>EXAMPLE OF USE IN MEDICAL TERMS</b>
-us	no meaning	microcephalus

---

# REFERENCES

---

Unless otherwise indicated, this chapter contains material adapted from [Building a Medical Terminology Foundation](#) by Kimberlee Carter and Marie Rutherford and is used under a [CC BY 4.0 international license](#), which itself contained material adapted from [Anatomy and Physiology](#) (on OpenStax) by Betts, et al. and is used under a [CC BY 4.0 international license](#).

# PRACTICE

---

The following activity will allow you to practice what you've learned in this chapter.

## Knowledge Check

Click and drag each of the terms from the word bank to its correct place in this exercise.



*An interactive H5P element has been excluded from this version of the text. You can view it online here:*

<https://louis.pressbooks.pub/medicalterminology/?p=2086#h5p-1>



## PART II

# DIRECTIONAL TERMS AND ANATOMIC PLANES, REGIONS, AND QUADRANTS

## Learning Objectives

When completing this chapter, the learner will be able to do the following:

- Identify anatomic position and its use in medical terminology
- Define, pronounce, and spell directional terms
- Define, pronounce, and spell anatomic planes
- Define, pronounce, and spell terms used to describe abdominal regions
- Interpret the meaning of abdominal quadrant abbreviations

## Introduction

Anatomists and health care providers use terminology for the purpose of precision and to reduce medical errors. For example, is a scar “above the wrist” located on the forearm two or three inches away from the hand? Or is it at the base of the hand? Is it on the palm-side or back-side? By using precise anatomical terminology, we eliminate ambiguity. Anatomical terms derive from ancient Greek and Latin words. To further increase precision, anatomists standardize the way in which they view the body.



# REGIONAL AND DIRECTIONAL TERMS

---

## Anatomic Position

When describing anatomy, the anatomic position is used as a neutral, standard position of reference. The body is viewed standing upright, feet hip-width apart; standing on tip-toes, with hands by your side, palms facing out. The directional terms are the same whether the body is standing or lying down face up.

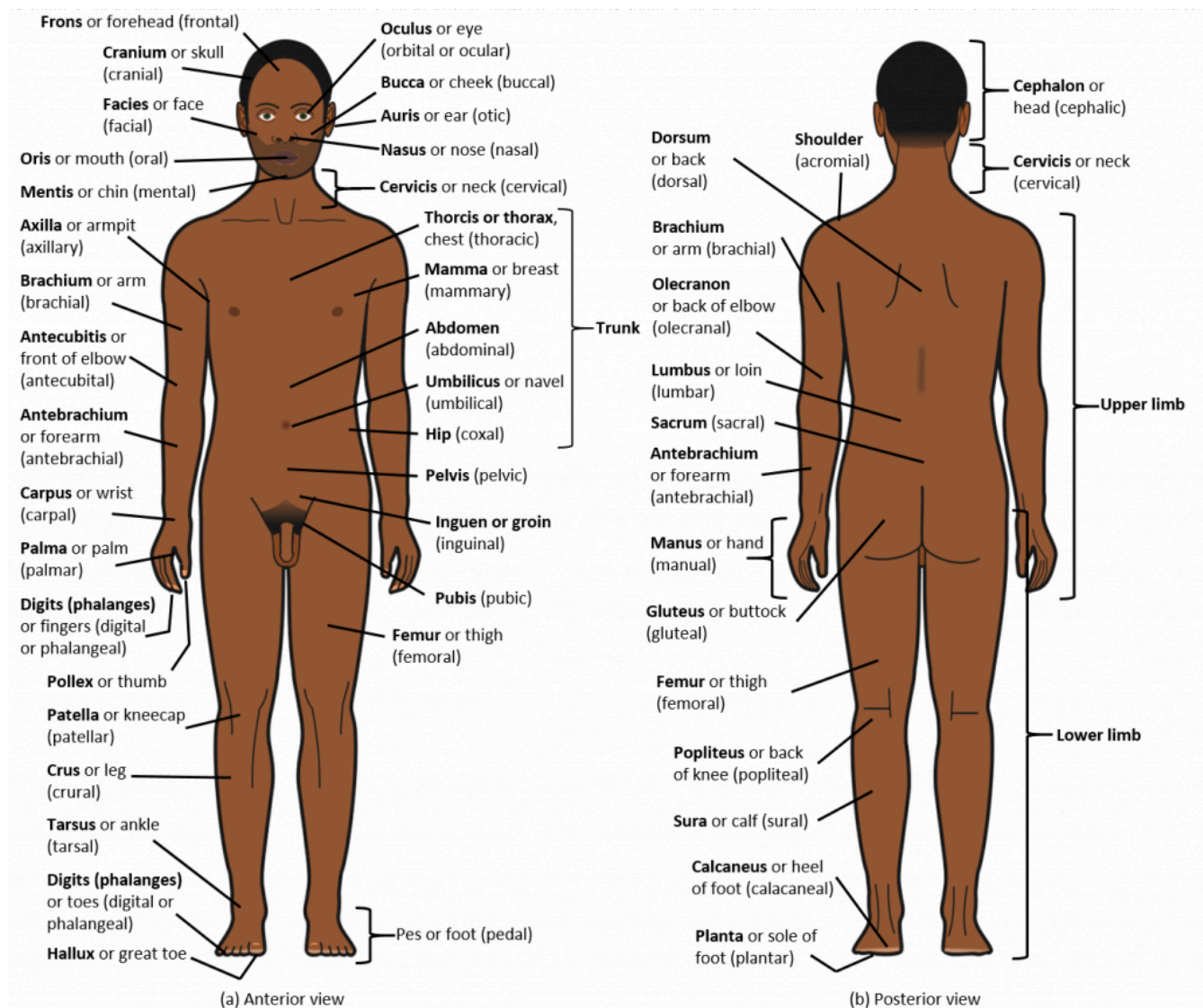


Figure 2.1 Body Parts and Regions. The human body is shown in anatomical position in an (a) anterior view and a (b) posterior view. The regions of the body are labeled in boldface. From [Jmarchn](#), 2016. Licensed under CC BY 3.0. [\[Image description.\]](#)

## Regional Terms

The human body's numerous regions have specific terms to help increase precision. Notice that the term "brachium" or "arm" is reserved for the "upper arm," and "antebrachium" or "forearm" is used rather than "lower arm." Similarly, "femur" or "thigh" is correct, and "leg" or "crus" is reserved for the portion of the lower

limb between the knee and the ankle. You will be able to describe the body's regions using the terms from the anatomical position ([Figure 2.1](#)).

## Directional Terms

Directional terms are essential for describing the relative locations of different body structures ([Figure 2.2](#)). For instance, an anatomist might describe one band of tissue as “inferior to” another, or a physician might describe a tumor as “superficial to” a deeper body structure. Below are terms, combining forms, definitions, and examples to help you learn and utilize directional terms.

### Anterior (or Ventral)

**Anter/o** or **ventr/o** describes the front or direction toward the front of the body.

Example

“The toes are anterior to the foot.”

### Posterior (or Dorsal)

**Poster/o** or **dors/o** describes the back or direction toward the back of the body.

Example

“The popliteus is posterior to the patella.”

## Superior (or Cephalad)

**Super/o** describes a position above or higher than another part of the body proper.

Example

“The orbits are superior to the oris (muscles of the mouth).”

## Inferior (or Caudal)

**Infer/o** or **caud/o** describes a position below or lower than another part of the body proper; near or toward the tail (in humans, the coccyx, or lowest part of the spinal column).

Example

“The pelvis is inferior to the abdomen.”

## Lateral

**Later/o** describes the side or direction toward the side of the body.

Example

“The thumb is lateral to the digits.”

## Medial

**Medi/o** describes the middle or direction toward the middle of the body.

Example

“The digits are medial to the thumb.”

## Proximal

**Proxim/o** describes a position in a limb that is nearer to the point of attachment or the trunk of the body.

Example

“The humerus (upper arm) is proximal to the radius and ulna (lower arm).”

## Distal

**Dist/o** describes a position in a limb that is farther from the point of attachment or the trunk of the body.

Example

“The ankle joint is distal to the hip joint.”

## Superficial

**Superficial** describes a position closer to the surface of the body or above.

Example

“The skin is superficial to the bones.”

## Deep

**Deep** describes a position farther from the surface of the body.

Example

“The brain is deep to the skull.”

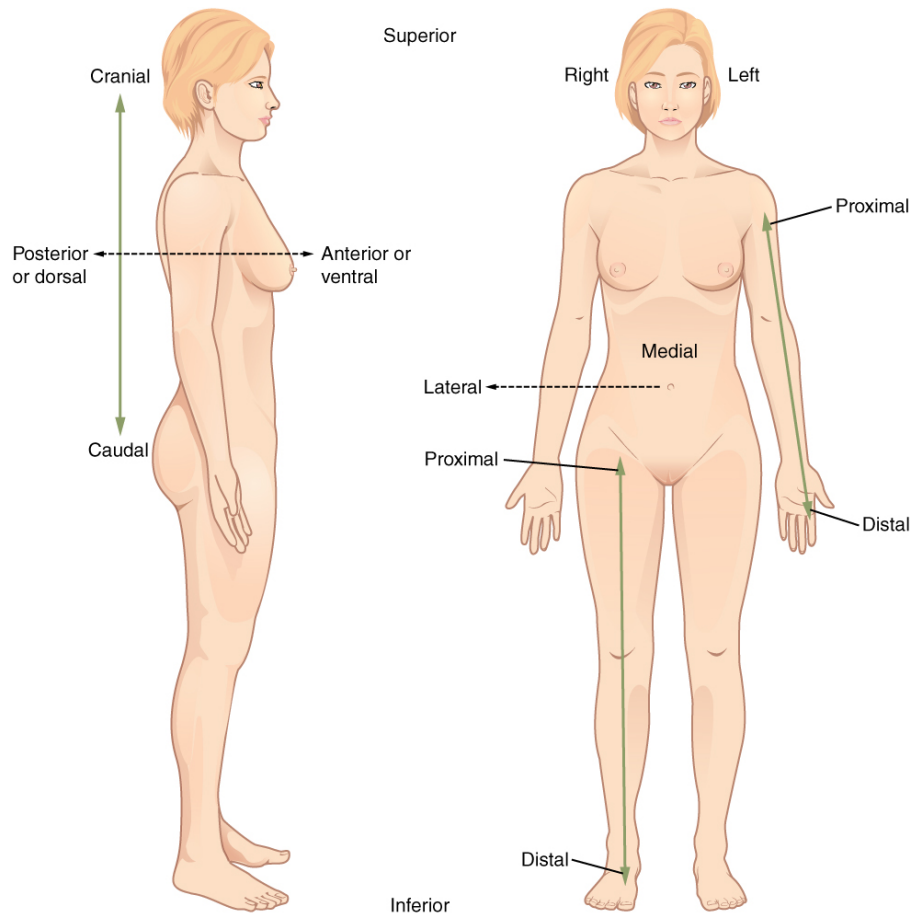


Figure 2.2 Directional Terms Applied to the Human Body. Paired directional terms are shown as applied to the human body. From Betts, et al., 2013. Licensed under [CC BY 4.0](https://creativecommons.org/licenses/by/4.0/). [\[Image description.\]](#)

## Image Descriptions

**Figure 2.1** image description: This illustration shows an anterior and posterior view of the human body. The cranial region encompasses the upper part of the head, while the facial region encompasses the lower half of the head beginning below the ears. The eyes are referred to as the ocular region. The cheeks are referred to as the buccal region. The ears are referred to as the auricle or otic region. The nose is referred to as the nasal region. The chin is referred to as the mental region. The neck is referred to as the cervical region. The trunk of the body contains, from superior to inferior, the thoracic region encompassing the chest, the mammary region encompassing each breast, the abdominal region encompassing the stomach area, the coxal region encompassing the belt line, and the pubic region encompassing the area above the genitals. The umbilicus, or naval, is located at the center of the abdomen. The pelvis and legs contain, from superior to

inferior, the inguinal or groin region between the legs and the genitals, the pubic region surrounding the genitals, the femoral region encompassing the thighs, the patellar region encompassing the knee, the crural region encompassing the lower leg, the tarsal region encompassing the ankle, the pedal region encompassing the foot, and the digital/phalangeal region encompassing the toes. The great toe is referred to as the hallux. The regions of the upper limbs, from superior to inferior, are the axillary region encompassing the armpit, the brachial region encompassing the upper arm, the antecubital region encompassing the front of the elbow, the antebrachial region encompassing the forearm, the carpal region encompassing the wrist, the palmar region encompassing the palm, and the digital/phalangeal region encompassing the fingers. The thumb is referred to as the pollux. The posterior view contains, from superior to inferior, the cervical region encompassing the neck, the dorsal region encompassing the upper back, and the lumbar region encompassing the lower back. The regions of the back of the arms, from superior to inferior, include the cervical region encompassing the neck, acromial region encompassing the shoulder, the brachial region encompassing the upper arm, the olecranal region encompassing the back of the elbow, the antebrachial region encompassing the back of the arm, and the manual region encompassing the palm of the hand. The posterior regions of the legs, from superior to inferior, include the gluteal region encompassing the buttocks, the femoral region encompassing the thigh, the popliteus region encompassing the back of the knee, the sural region encompassing the back of the lower leg, and the plantar region encompassing the sole of the foot. Some regions are combined into larger regions. These include the trunk, which is a combination of the thoracic, mammary, abdominal, naval, and coxal regions. The cephalic region is a combination of all of the head regions. The upper limb region is a combination of all of the arm regions. The lower limb region is a combination of all of the leg regions. [\[Return to Figure 2.1\].](#)

**Figure 2.2** image description: This illustration shows two diagrams: one of a side view of a female and the other of an anterior view of a female. Each diagram shows directional terms using double-sided arrows. The cranial-distal arrow runs vertically behind the torso and lower abdomen. The cranial arrow is pointing toward the head while the caudal arrow is pointing toward the tail bone. The posterior/anterior arrow is running horizontally through the back and chest. The posterior or dorsal arrow is pointing toward the back while the anterior, or ventral arrow, is pointing toward the abdomen. On the anterior view, the proximal/distal arrow is on the right arm. The proximal arrow is pointing up toward the shoulder while the distal arrow is pointing down toward the hand. The lateral-medial arrow is a horizontal arrow on the abdomen. The medial arrow is pointing toward the navel while the lateral arrow is pointing away from the body to the right. Right refers to the right side of the woman's body from her perspective while left refers to the left side of the woman's body from her perspective. [\[Return to Figure 2.2\].](#)

# PLANES, REGIONS, AND QUADRANTS

---

## Anatomic Planes

Modern medical imaging devices enable clinicians to obtain “virtual sections” of living bodies. We call these scans. Body sections and scans can be correctly interpreted, however, only if the viewer understands the plane along which the section was made. A plane is an imaginary two-dimensional surface that passes through the body. There are three planes commonly referred to in anatomy and medicine:

1. The **sagittal plane** is the plane that divides the body or an organ vertically into right and left sides.
  - If this vertical plane runs directly down the middle of the body, it is called the **midsagittal** or **median plane**.
  - If it divides the body into unequal right and left sides, it is called a **parasagittal plane**, or less commonly, a **longitudinal section**.
2. The **frontal plane** or **coronal plane** is the plane that divides the body or an organ into an anterior (front) portion and a posterior (rear) portion.
3. The **transverse plane**, **axial plane**, or **horizontal plane** is the plane that divides the body or organ horizontally into upper and lower portions.

Can you locate the planes?

## Abdominal Regions and Quadrants

To promote clear communication—for instance, about the location of a patient’s abdominal pain or a suspicious mass—health care providers typically divide up the cavity into either nine regions or four quadrants.

### Nine Regions with Pronunciations

- One **Umbilical region** around the navel (umbilicus).
- Two **Lumbar regions** to the right and left of the umbilical region, near the waist.
- One **Epigastric region** superior to the umbilical region.

- Two **Hypochondriac regions** to the right and left of the epigastric region.
- One **Hypogastric region** inferior to the umbilical region.
- Two **Iliac regions** or **inguinal regions** to the right and left of the hypogastric region, near the groin (a.k.a. inguinal regions).

## Four Quadrants with Abbreviations

- **Right Upper Quadrant (RUQ)**
- **Left Upper Quadrant (LUQ)**
- **Right Lower Quadrant (RLQ)**
- **Left Lower Quadrant (LLQ)**

# BODY POSITIONS

---

Body position terms are essential to communicate how the patient's body is placed for any medical examination, surgery, diagnostic procedure, treatment, or recovery. The most common body positions are listed below along with descriptions and accompanying images.

**Fowler position:** semi-sitting position with slight elevation of the knees

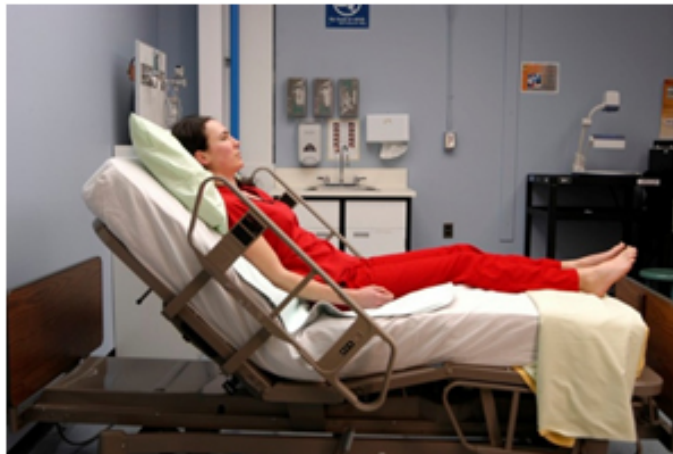

Figure 2.3 Fowler's Position. From Glynda Rees Doyle and Jodie Anita McCutcheon, 2015. Licensed under [CC BY 4.0](#).

**Lateral recumbent position:** side lying; right and left precede the term to indicate the patient's side

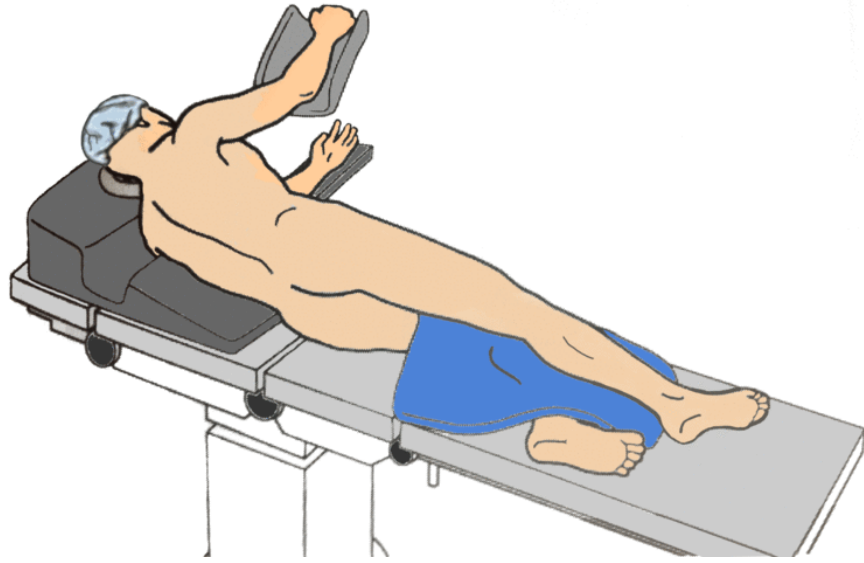


Figure 2.4 Lateral Position. From [Saltanat ebli](#), 2013. Image in the public domain.

**Lithotomy position:** lying on back with legs raised and feet in stirrups, both hips and knees flexed, and thighs abducted (away from the body) and externally rotated

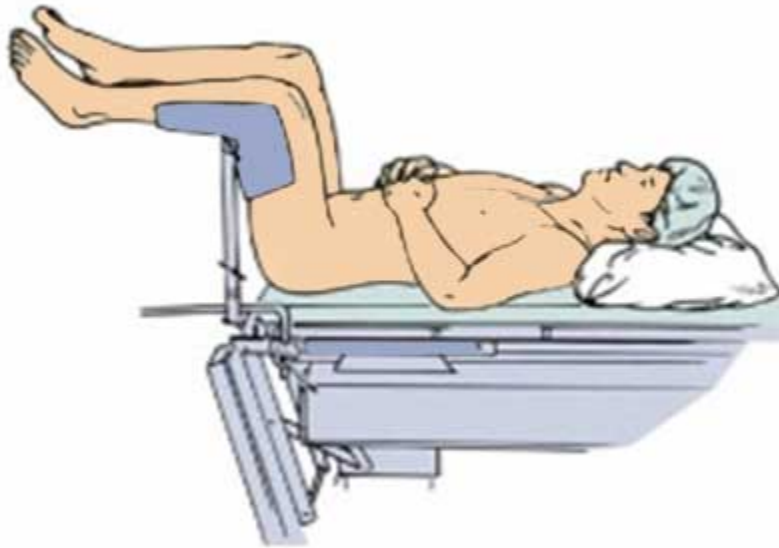


Figure 2.5 Lithotomy Position. From [Saltanat ebli](#), 2012. Image in the public domain.

**Orthopneic position:** sitting upright in a chair or in bed supported by pillows behind the back. Sometimes the patient tilts forward, resting on a pillow supported by an overbed table (also called orthopneic position).

**Prone position:** lying on abdomen, facing downward; head may be turned to one side; a.k.a. ventral recumbent

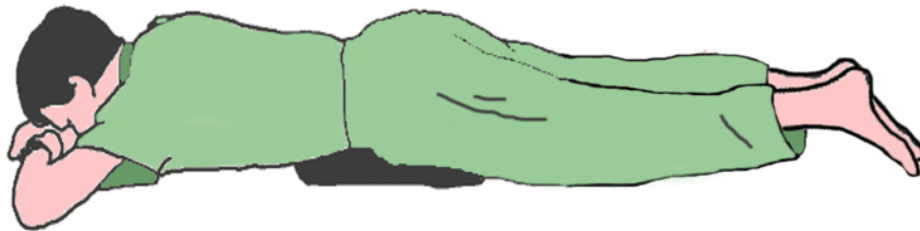

Figure 2.6 Prone Position. From [Saltanat ebli](#), 2013. Image in the public domain.

**Recumbent position:** lying down in any position; a.k.a. decubitus position

**Semi-prone position:** lying on side between a lateral and prone position with the upper knee drawn up toward the chest and the lower arm drawn behind parallel to the back. “Right” or “left” precedes the term to indicate the patient’s right or left side.

**Supine position:** lying on back, facing upward; a.k.a. dorsal recumbent position

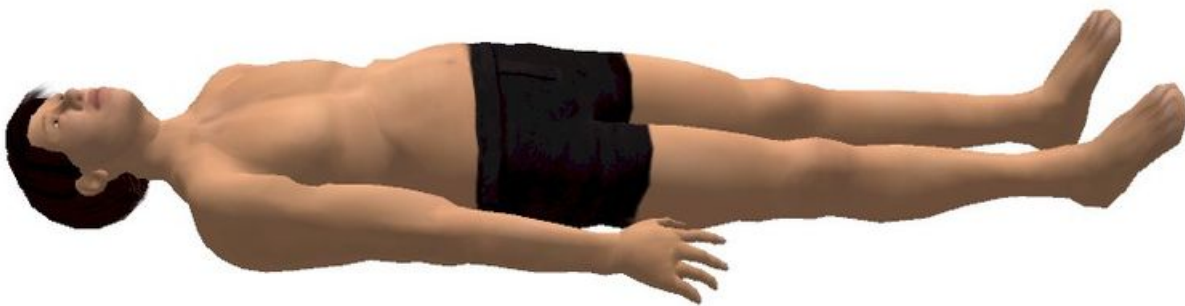

Figure 2.7 Supine Position. From [Asanagi](#), 2012. Image in the public domain.

**Trendelenburg position:** lying on back with body tilted so that the head is lower than the feet

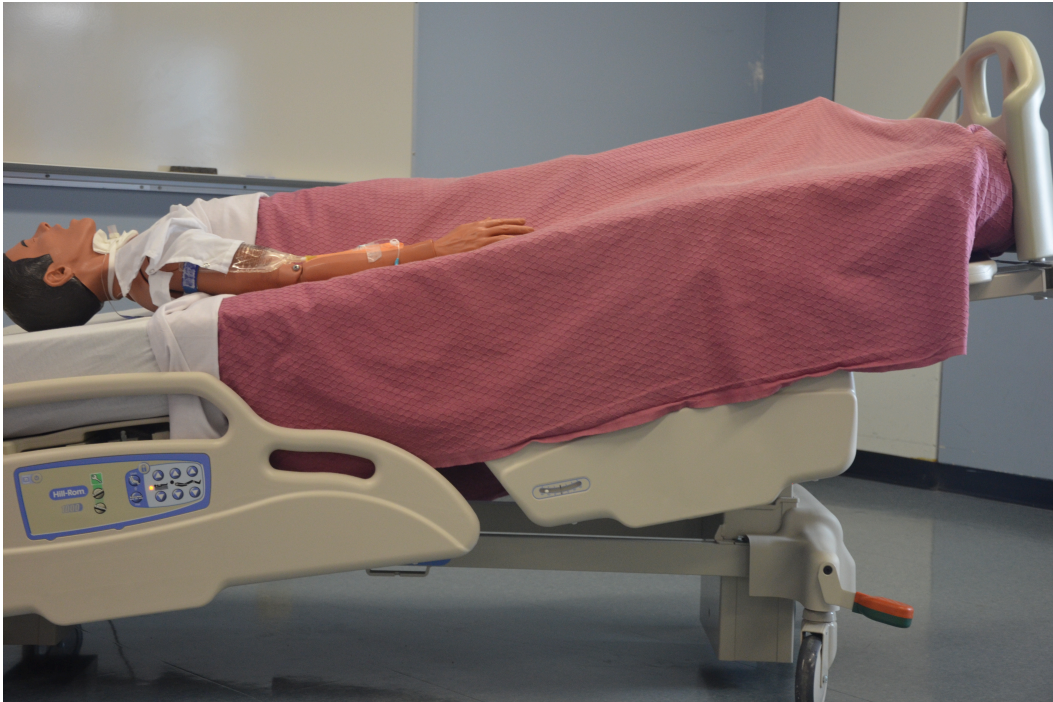

Figure 2.8 Trendelenburg Position. From Glynda Rees Doyle and Jodie Anita McCutcheon, 2015. Licensed under [CC BY 4.0](https://creativecommons.org/licenses/by/4.0/).

# REFERENCES

---

Unless otherwise indicated, this chapter contains material adapted from [Building a Medical Terminology Foundation](#) by Kimberlee Carter and Marie Rutherford and is used under a [CC BY 4.0 international license](#), which itself contained material adapted from [Anatomy and Physiology](#) (on OpenStax) by Betts, et al. and is used under a [CC BY 4.0 international license](#).

# PRACTICE

---

The following activities will allow you to practice what you've learned in this chapter.

## Locate the Planes

Click and drag each term to the box corresponding with the anatomic structure, body part, body plane, or body region for that term.



*An interactive H5P element has been excluded from this version of the text. You can view it online here:*

<https://louis.pressbooks.pub/medicalterminology/?p=2089#h5p-3>

## Locate the Abdominal Quadrant Regions

Click and drag each term to the box corresponding with the anatomic structure, body part, body plane, or body region for that term.



*An interactive H5P element has been excluded from this version of the text. You can view it online here:*

<https://louis.pressbooks.pub/medicalterminology/?p=2089#h5p-5>

## Directional Terms Reinforcement Activity

Click the term that correctly answers each question or completes each sentence.



*An interactive H5P element has been excluded from this version of the text. You can view it online here:*

<https://louis.pressbooks.pub/medicalterminology/?p=2089#h5p-6>

## PART III

# BODY STRUCTURE, COLOR, AND ONCOLOGY

## Learning Objectives

- Connect medical language learning to the context of anatomy and physiology
- Introduce the basic architecture and levels of organization of the human body
- Describe body cavities and the functions of associated membranes
- Define and spell word parts related to color
- Define and spell word parts related to oncology

## Introduction

As you memorize the language components of medical terminology, it is important to support that learning within the context of anatomy and physiology. Proceeding through the body system chapters, you will learn word parts, whole medical terms, and common abbreviations. It is important to put into context where in the body the medical term is referencing and then consider how it works within the body.

Anatomy focuses on structure, and physiology focuses on function. Much of the study of physiology centers on the body's tendency toward homeostasis.

Consider the structures of the body in terms of fundamental levels of organization that increase in complexity: subatomic particles, atoms, molecules, organelles, cells, tissues, organs, organ systems, and organisms ([Figure 3.1](#)).

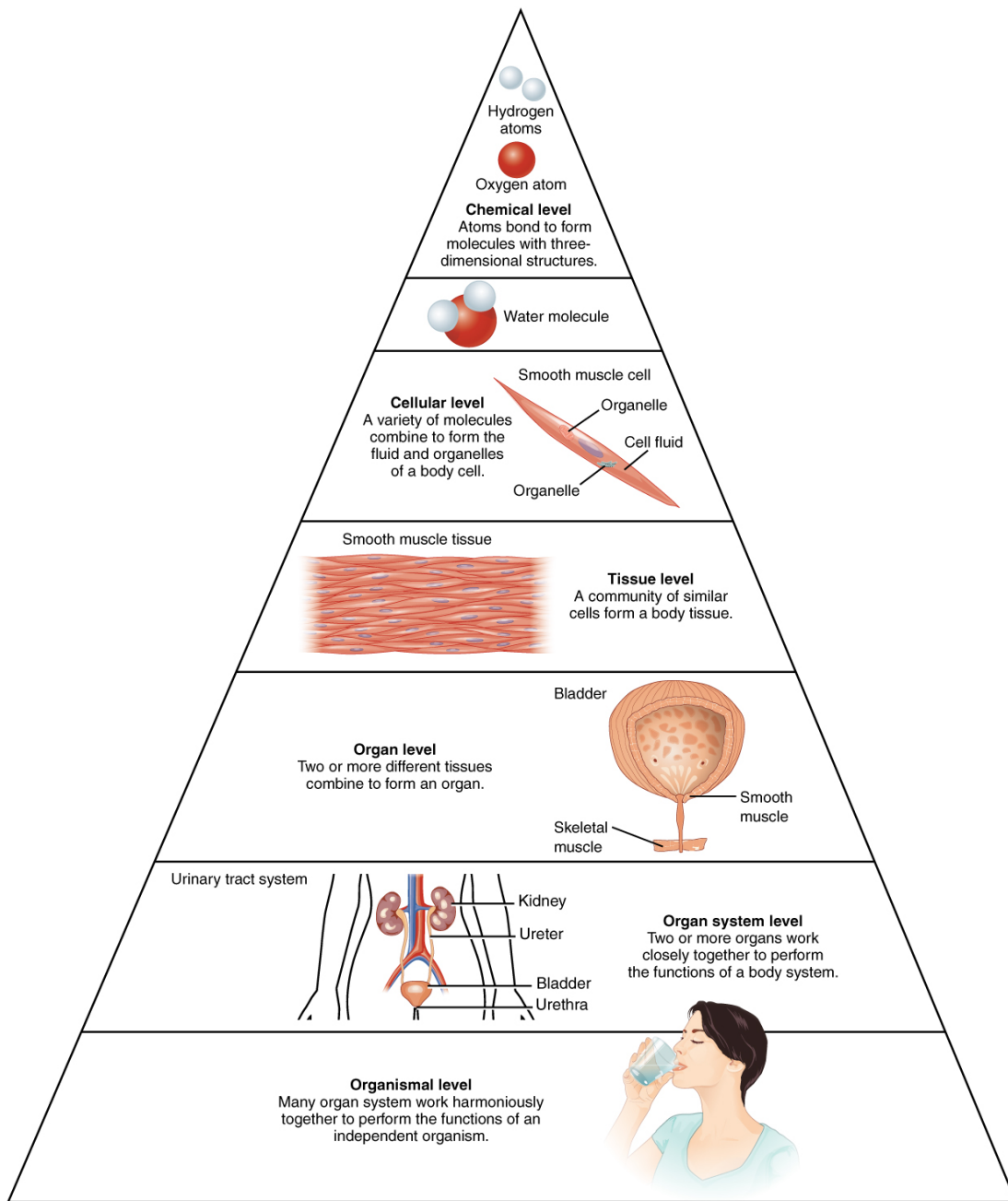


Figure 3.1 Levels of Structural Organization of the Human Body. The organization of the body often is discussed in terms of six distinct levels of increasing complexity, from the smallest chemical building blocks to a unique human organism. From Betts, et al., 2013. Licensed under [CC BY 4.0](https://creativecommons.org/licenses/by/4.0/). [\[Image description.\]](#)

## Image Description

**Figure 3.1 image description:** This illustration shows biological organization as a pyramid. The chemical level is at the apex of the pyramid where atoms bond to form molecules with three-dimensional structures. An example is shown with two white hydrogen atoms bonding to a red oxygen atom to create water. The next level down on the pyramid is the cellular level, as illustrated with a long, tapered, smooth muscle cell. At this level, a variety of molecules combine to form the interior fluid and organelles of a body cell. The next level down is the tissue level. A community of similar cells forms body tissue. The example given here is a section of smooth muscle tissue, which contains many smooth muscle cells closely bound side by side. The next level down is the organ level, as illustrated with the bladder and urethra. The bladder contains smooth muscle while the urethra contains skeletal muscle. These are both examples of muscle tissues. The next level down is the organ system level, as illustrated by the entire urinary system containing the kidney, ureters, bladder, and urethra. At this level, two or more organs work closely together to perform the functions of a body system. At the base of the pyramid is the organismal level illustrated with a woman drinking water. At this level, many organ systems work harmoniously together to perform the functions of an independent organism. [\[Return to Figure 3.1\]](#).



# LEVELS OF ORGANIZATION AND TISSUE TYPES

---

## The Levels of Organization

All matter in the universe is composed of one or more unique pure substances called elements; familiar examples are hydrogen, oxygen, carbon, nitrogen, calcium, and iron.

The smallest unit of any of these pure substances (elements) is an **atom**. Atoms are made up of **subatomic particles** such as protons, electrons, and neutrons.

Two or more atoms combine to form a **molecule**, such as the water molecules, proteins, and sugars found in living things. Molecules are the chemical building blocks of all body structures.

A **cell** is the smallest independently functioning unit of a living organism. All living structures of human anatomy contain cells, and almost all functions of human physiology are performed in cells or are initiated by cells.

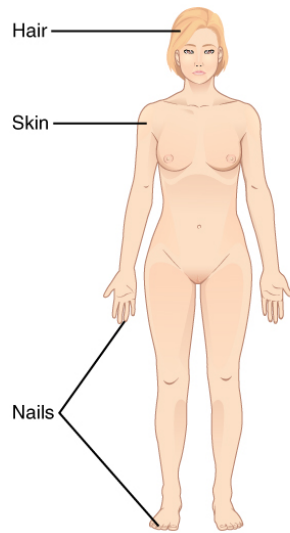
A human cell typically consists of flexible membranes that enclose cytoplasm, a water-based cellular fluid, together with a variety of tiny functioning units called organelles. In humans, as in all organisms, cells perform all functions of life.

A **tissue** is a group of many similar cells (though sometimes composed of a few related types) that work together to perform a specific function.

An **organ** is an anatomically distinct structure of the body composed of two or more tissue types. Each organ performs one or more specific physiological functions.

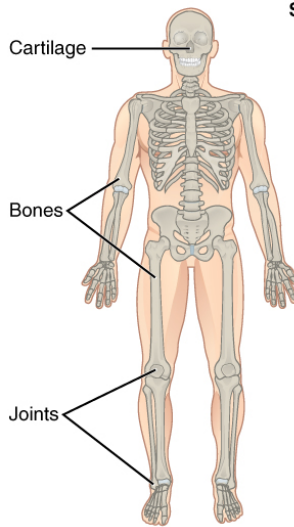
An **organ system** is a group of organs that work together to perform major functions or meet the physiological needs of the body.

Consider the breakdown of the human body into eleven distinct organ systems ([Figure 3.2](#) and [Figure 3.3](#)). Assigning organs to organ systems can be imprecise, since organs that “belong” to one system can also have functions integral to another system. In fact, most organs contribute to more than one system.



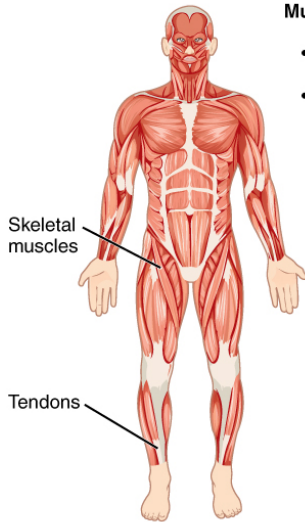
**Integumentary System**

- Encloses internal body structures
- Site of many sensory receptors



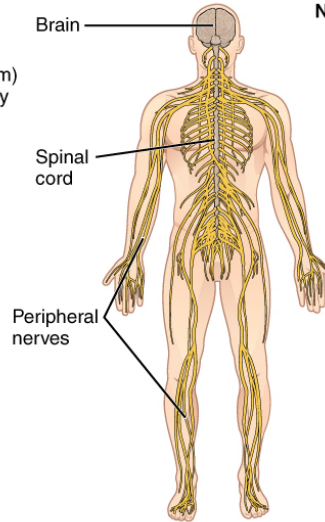
**Skeletal System**

- Supports the body
- Enables movement (with muscular system)



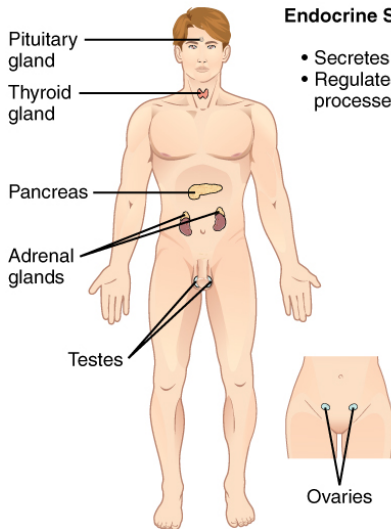
**Muscular System**

- Enables movement (with skeletal system)
- Helps maintain body temperature



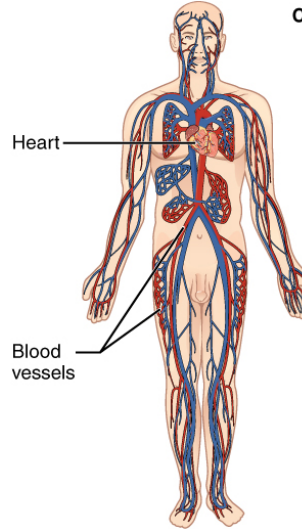
**Nervous System**

- Detects and processes sensory information
- Activates bodily responses



**Endocrine System**

- Secretes hormones
- Regulates bodily processes



**Cardiovascular System**

- Delivers oxygen and nutrients to tissues
- Equalizes temperature in the body

Figure 3.2 Organ Systems of the Human Body. Organs that work together are grouped into organ systems. From Betts, et al., 2013. Licensed under [CC BY 4.0](https://creativecommons.org/licenses/by/4.0/) [Image description.]



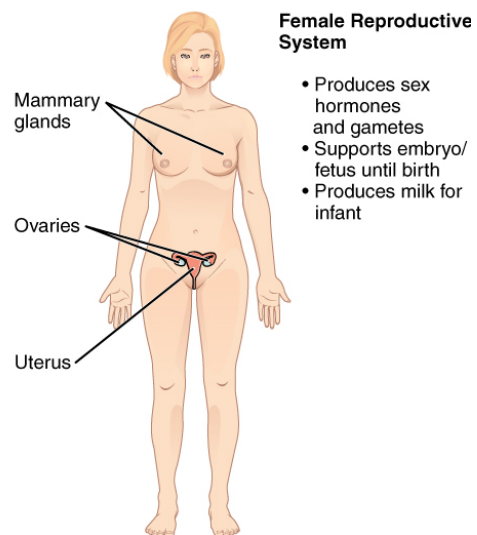
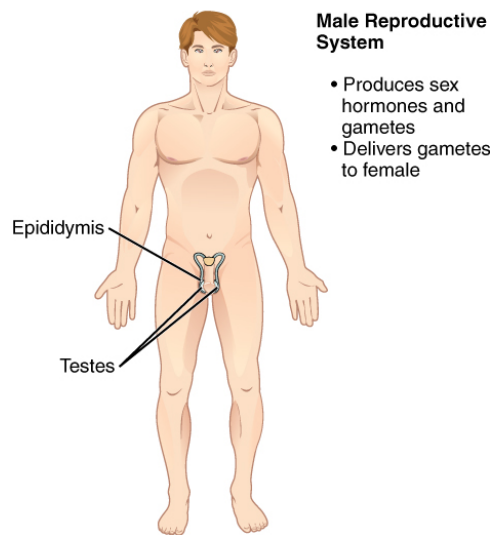
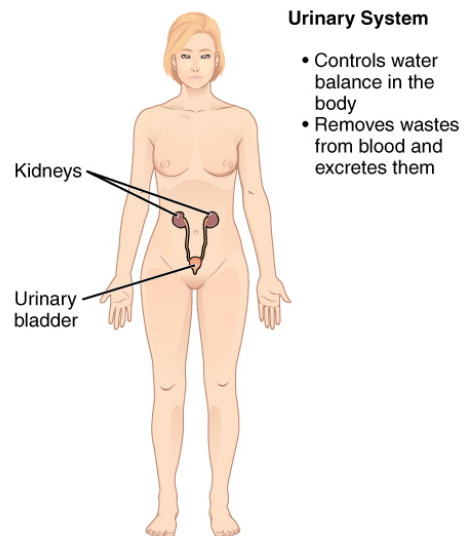
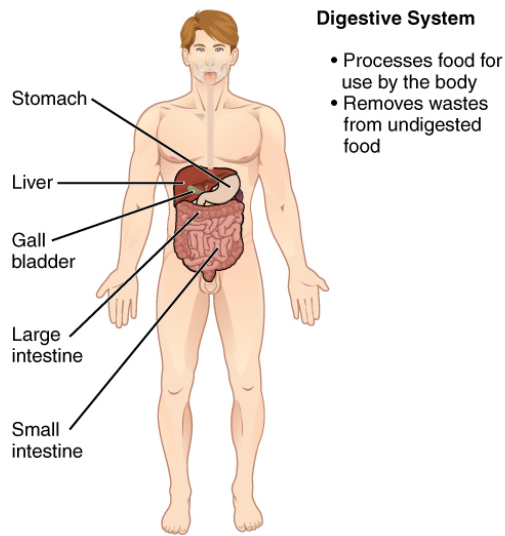
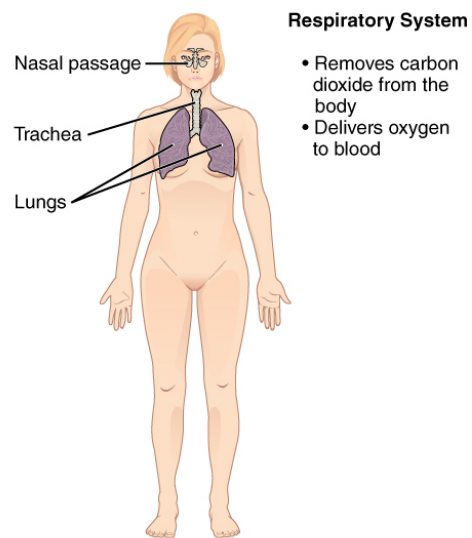
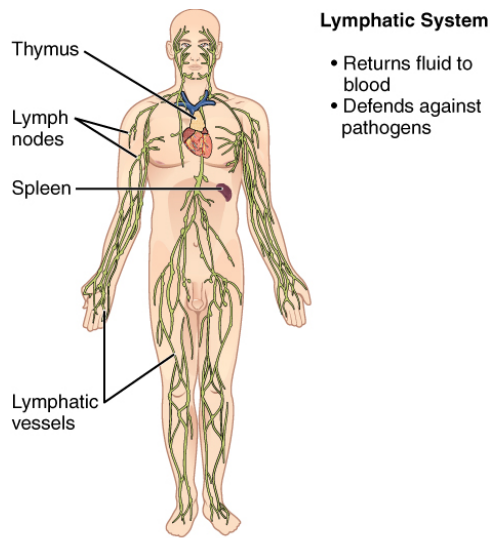


Figure 3.3 Organ Systems of the Human Body (continued). Organs that work together are grouped into organ systems. From Betts, et al., 2013. Licensed under CC BY 4.0 [Image description.]

The **organism** level is the highest level of organization. An organism is a living being that has a cellular structure and that can independently perform all physiologic functions necessary for life. In multicellular organisms, including humans, all cells, tissues, organs, and organ systems of the body work together to maintain the life and health of the organism.

## Watch this video:



One or more interactive elements has been excluded from this version of the text. You can view them online here: <https://louis.pressbooks.pub/medicalterminology/?p=1314#oembed-1>

*Media 3.1. Introduction to Anatomy & Physiology: Crash Course A&P #1 [Online video].  
Copyright 2015 by CrashCourse.*

## Tissue Types

Although there are many types of cells in the human body, they are organized into four broad categories of tissues: epithelial, connective, muscle, and nervous. Each of these categories is characterized by specific functions that contribute to the overall health and maintenance of the body. A disruption of the structure is a sign of injury or disease. Such changes can be detected through histology, the microscopic study of tissue appearance, organization, and function.

Epithelial tissue, also referred to as epithelium, refers to the sheets of cells that cover exterior surfaces of the body, line internal cavities and passageways, and form certain glands. Connective tissue, as its name implies, binds the cells and organs of the body together and functions in the protection, support, and integration of all parts of the body. Muscle tissue is excitable, responding to stimulation and contracting to provide movement, and occurs as three major types: skeletal (voluntary) muscle, smooth muscle, and cardiac muscle in the heart. Nervous tissue is also excitable, allowing the propagation of electrochemical signals in the form of nerve impulses that communicate between different regions of the body ([Figure 3.4](#)).

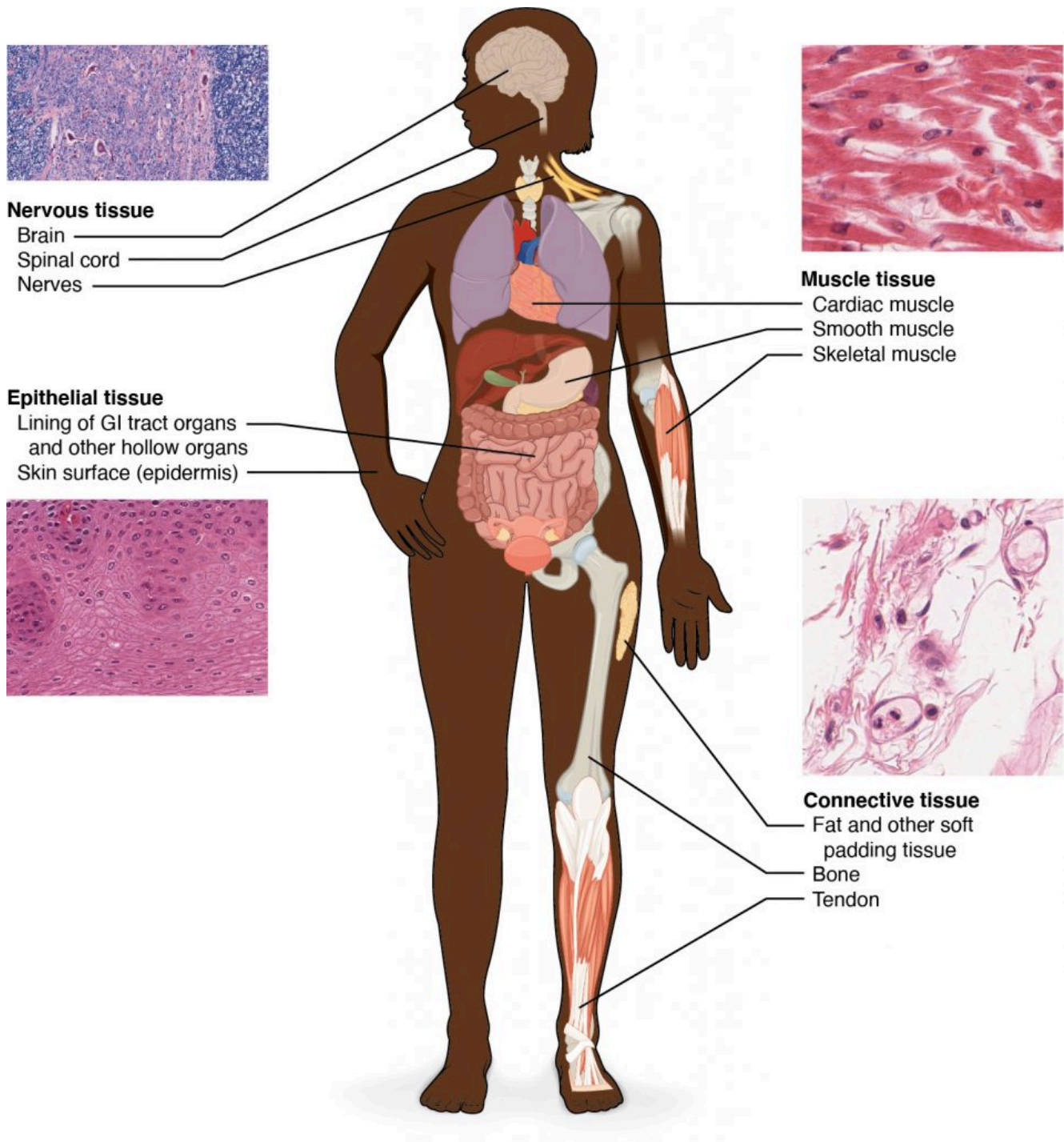


Figure 3.4 Four Types of Tissue: Body. The four types of tissues are exemplified in nervous tissue, stratified squamous epithelial tissue, cardiac muscle tissue, and connective tissue. (Micrographs provided by the Regents of University of Michigan Medical School © 2012) From Betts, et al., 2013. Licensed under [CC BY 4.0](https://creativecommons.org/licenses/by/4.0/). [Image description.]

## Image Descriptions

**Figure 3.2 image description:** This illustration shows eight silhouettes of a human female, each showing the components of a different organ system. The integumentary system encloses internal body structures and is the site of many sensory receptors. The integumentary system includes the hair, skin, and nails. The skeletal system supports the body and, along with the muscular system, enables movement. The skeletal system includes cartilage, such as that at the tip of the nose, as well as the bones and joints. The muscular system enables movement, along with the skeletal system, but also helps to maintain body temperature. The muscular system includes skeletal muscles, as well as tendons that connect skeletal muscles to bones. The nervous system detects and processes sensory information and activates bodily responses. The nervous system includes the brain, spinal cord, and peripheral nerves, such as those located in the limbs. The endocrine system secretes hormones and regulates bodily processes. The endocrine system includes the pituitary gland in the brain, the thyroid gland in the throat, the pancreas in the abdomen, the adrenal glands on top of the kidneys, and the testes in the scrotum of males as well as the ovaries in the pelvic region of females. The cardiovascular system delivers oxygen and nutrients to the tissues as well as equalizes temperature in the body. The cardiovascular system includes the heart and blood vessels. [\[Return to Figure 3.2\]](#).

**Figure 3.3 image description:** The lymphatic system returns fluid to the blood and defends against pathogens. The lymphatic system includes the thymus in the chest, the spleen in the abdomen, the lymphatic vessels that spread throughout the body, and the lymph nodes distributed along the lymphatic vessels. The respiratory system removes carbon dioxide from the body and delivers oxygen to the blood. The respiratory system includes the nasal passages, the trachea, and the lungs. The digestive system processes food for use by the body and removes wastes from undigested food. The digestive system includes the stomach, the liver, the gallbladder (connected to the liver), the large intestine, and the small intestine. The urinary system controls water balance in the body and removes and excretes waste from the blood. The urinary system includes the kidneys and the urinary bladder. The reproductive systems of males and females produce sex hormones and gametes. The male reproductive system is specialized to deliver gametes to the female while the female reproductive system is specialized to support the embryo and fetus until birth and produce milk for the infant after birth. The male reproductive system includes the two testes within the scrotum as well as the epididymis which wraps around each testis. The female reproductive system includes the mammary glands within the breasts and the ovaries and uterus within the pelvic cavity. [\[Return to Figure 3.3\]](#).

**Figure 3.4 image description:** This illustration shows the four primary tissue types in the human body. Epithelial tissue, also referred to as epithelium, refers to the sheets of cells that cover exterior surfaces of the body, line internal cavities and passageways, and form certain glands. Connective tissue, as its name implies, binds the cells and organs of the body together and functions in the protection, support, and integration of all parts of the body. Muscle tissue is excitable, responding to stimulation and contracting to provide movement, and occurs as three major types: skeletal (voluntary) muscle, smooth muscle, and cardiac muscle in the heart.

Nervous tissue is also excitable, allowing the propagation of electrochemical signals in the form of nerve impulses that communicate between different regions of the body. [\[Return to Figure 3.4\].](#)

# BODY CAVITIES, SEROUS MEMBRANES, AND TISSUE MEMBRANES

## Body Cavities and Serous Membranes

The body maintains its internal organization by means of membranes, sheaths, and other structures that separate compartments. The dorsal (posterior) cavity and the ventral (anterior) cavity are the largest body compartments (Figure 3.5). These cavities contain and protect delicate internal organs, and the ventral cavity allows for significant changes in the size and shape of the organs as they perform their functions. The lungs, heart, stomach, and intestines, for example, can expand and contract without distorting other tissues or disrupting the activity of nearby organs.

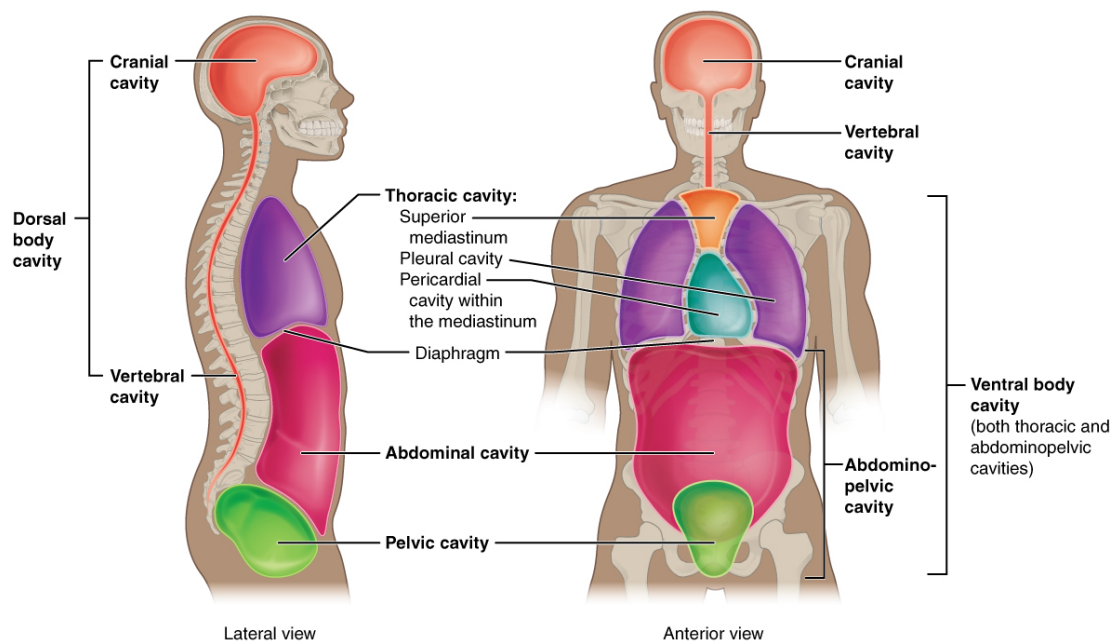


Figure 3.5 Dorsal and Ventral Body Cavities. The ventral cavity includes the thoracic and abdominopelvic cavities and their subdivisions. The dorsal cavity includes the cranial and spinal cavities. From Betts, et al., 2013. Licensed under [CC BY 4.0](https://creativecommons.org/licenses/by/4.0/). [\[Image description.\]](#)

## Subdivisions of the Posterior (Dorsal) and Anterior (Ventral) Cavities

The posterior (dorsal) and anterior (ventral) cavities are each subdivided into smaller cavities:

The posterior (dorsal) cavity has two main subdivisions:

- In the posterior (dorsal) cavity, the cranial cavity houses the brain.
  - Protected by the bones of the skull and cerebrospinal fluid
- The spinal cavity (or vertebral cavity) encloses the spinal cord.
  - Protected by the vertebral column and cerebrospinal fluid

The anterior (ventral) cavity has two main subdivisions:

- The thoracic cavity is the more superior subdivision of the anterior cavity, and it is enclosed by the rib cage.
  - The thoracic cavity contains the lungs and the heart, which is located in the mediastinum.
  - The diaphragm forms the floor of the thoracic cavity and separates it from the more inferior abdominopelvic cavity.
- The abdominopelvic cavity is the largest cavity in the body.
  - No membrane physically divides the abdominopelvic cavity.
  - The abdominal cavity houses the digestive organs.
  - The pelvic cavity is enclosed by the pelvic bones and houses some urinary organs, reproductive organs, and some structures of the digestive system.

\*\*\*Practice locating cavities.

## Tissue Membranes

A tissue membrane is a thin layer or sheet of cells that covers the outside of the body (for example, skin), the organs (for example, pericardium), internal passageways that lead to the exterior of the body (for example, abdominal mesenteries), and the lining of the movable joint cavities. There are two basic types of tissue membranes: connective tissue and epithelial membranes (Figure 3.6).

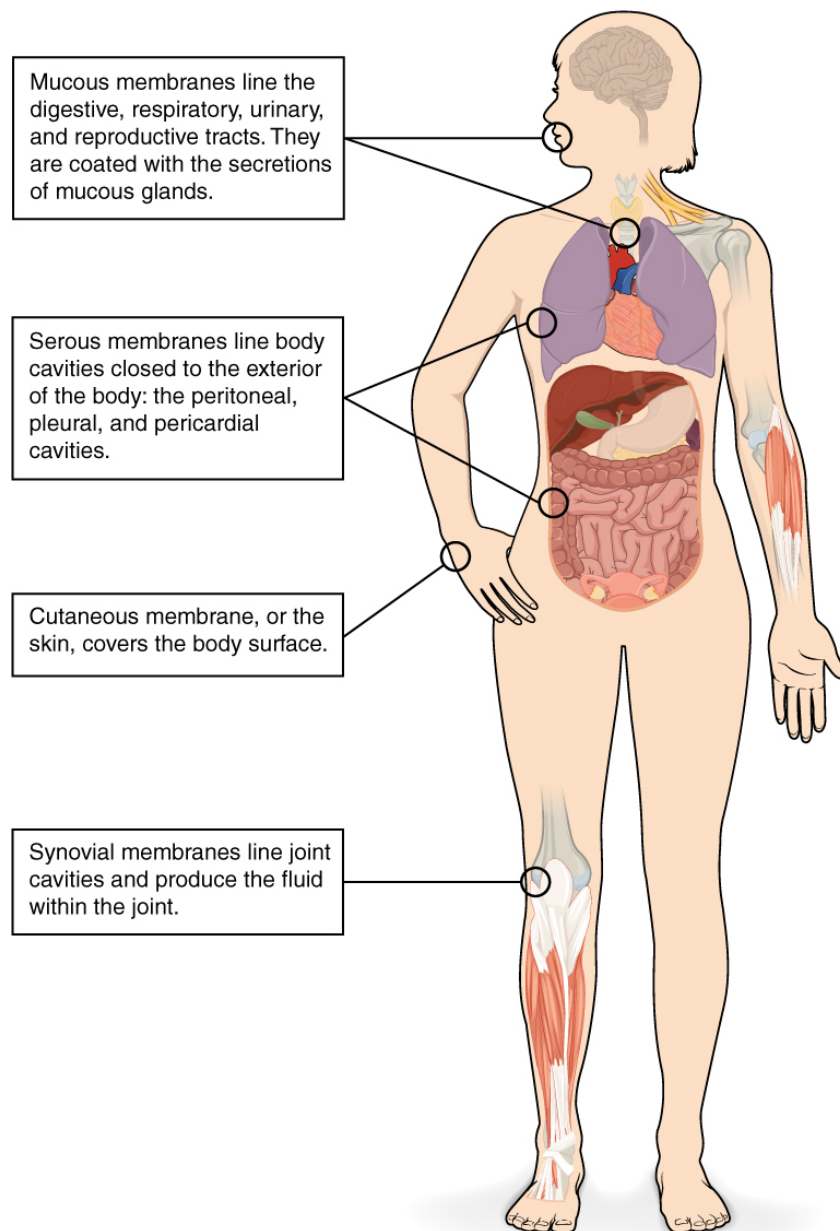


Figure 3.6 Tissue Membranes. The two broad categories of tissue membranes in the body are (1) connective tissue membranes, which include synovial membranes, and (2) epithelial membranes, which include mucous membranes, serous membranes, and the cutaneous membrane—in other words, the skin. From Betts, et al., 2013. Licensed under [CC BY 4.0](https://creativecommons.org/licenses/by/4.0/). [\[Image description.\]](#)

## Connective Tissue Membranes

- The connective tissue membrane is formed solely from connective tissue.
  - These membranes encapsulate organs, such as the kidneys, and line our movable joints.

- A synovial membrane is a type of connective tissue membrane that lines the cavity of a freely movable joint.
  - For example, synovial membranes surround the joints of the shoulder, elbow, and knee.

## Epithelial Membranes

- An epithelial membrane is composed of epithelium attached to a layer of connective tissue.
- A mucous membrane is also a composite of connective and epithelial tissues.
- Sometimes called mucosae, these epithelial membranes line the body cavities and hollow passageways that open to the external environment and include the digestive, respiratory, excretory, and reproductive tracts.
- Mucus, produced by the epithelial exocrine glands, covers the epithelial layer.
- The underlying connective tissue, called the lamina propria (literally “own layer”), helps support the fragile epithelial layer.
- The skin is an epithelial membrane also called the cutaneous membrane.
- It is a stratified squamous epithelial membrane resting on top of connective tissue. The apical surface of this membrane is exposed to the external environment and is covered with dead, keratinized cells that help protect the body from desiccation and pathogens.

## Membranes of the Anterior (Ventral) Body Cavity

A serous membrane (also referred to as serosa) is an epithelial membrane composed of mesodermally derived epithelium called the mesothelium that is supported by connective tissue.

These membranes line the coelomic cavities of the body, and they cover the organs located within those cavities. They are essentially membranous bags, with mesothelium lining the inside and connective tissue on the outside.

- Parietal layers: line the walls of the body cavity.
- Visceral layer: covers the organs (the viscera).

Between the parietal and visceral layers is a very thin, fluid-filled serous space.

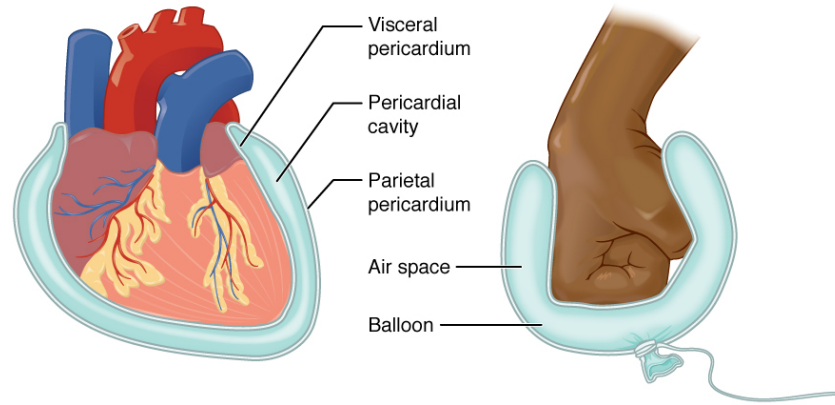


Figure 3.7 Serous Membrane. Serous membrane lines the pericardial cavity and reflects back to cover the heart—much the same way that an underinflated balloon would form two layers surrounding a fist. From Betts, et al., 2013. Licensed under [CC BY 4.0](#). [\[Image description.\]](#)

There are three serous cavities and their associated membranes. Serous membranes provide additional protection to the viscera they enclose by reducing friction that could lead to inflammation of the organs.

- Pleura: surrounds the lungs in the pleural cavity and reduces friction between the lungs and the body wall.
- Pericardium: surrounds the heart in the pericardial cavity and reduces friction between the heart and the wall of the pericardium.
- Peritoneum: surrounds several organs in the abdominopelvic cavity. The peritoneal cavity reduces friction between the abdominal and pelvic organs and the body wall.

\*\*\*Test yourself

## Image Descriptions

**Figure 3.5 image description:** This illustration shows a lateral and anterior view of the body and highlights the body cavities with different colors. The cranial cavity is a large, bean-shaped cavity filling most of the upper skull where the brain is located. The vertebral cavity is a very narrow, thread-like cavity running from the cranial cavity down the entire length of the spinal cord. Together the cranial cavity and vertebral cavity can be referred to as the dorsal body cavity. The thoracic cavity consists of three cavities that fill the interior area of the chest. The two pleural cavities are situated on both sides of the body, anterior to the spine and lateral to the breastbone. The superior mediastinum is a wedge-shaped cavity located between the superior regions of

the two thoracic cavities. The pericardial cavity within the mediastinum is located at the center of the chest below the superior mediastinum. The pericardial cavity roughly outlines the shape of the heart. The diaphragm divides the thoracic and the abdominal cavities. The abdominal cavity occupies the entire lower half of the trunk, anterior to the spine. Just under the abdominal cavity, anterior to the buttocks, is the pelvic cavity. The pelvic cavity is funnel shaped and is located inferior and anterior to the abdominal cavity. Together the abdominal and pelvic cavity can be referred to as the abdominopelvic cavity while the thoracic, abdominal, and pelvic cavities together can be referred to as the ventral body cavity. [\[Return to Figure 3.5\]](#).

**Figure 3.6 image description:** This illustration shows the silhouette of a human female from an anterior view. Several organs are showing in her neck, thorax, abdomen, left arm, and right leg. Text boxes point out and describe the mucous membranes in several different organs. The topmost box points to the mouth and trachea. It states that mucous membranes line the digestive, respiratory, urinary, and reproductive tracts. They are coated with the secretions of mucous glands. The second box points to the outside edge of the lungs as well as the large intestine and states that serous membranes line body cavities that are closed to the exterior of the body, including the peritoneal, pleural, and pericardial cavities. The third box points to the skin of the hand. It states that the cutaneous membrane, also known as the skin, covers the body surface. The fourth box points to the right knee. It states that synovial membranes line joint cavities and produce the fluid within the joint. [\[Return to Figure 3.6\]](#).

**Figure 3.7 image description:** This diagram shows the pericardium on the left next to an analogy of a hand punching a balloon on the right. The pericardium is a two-layered sac that surrounds the entire heart except where the blood vessels emerge on the heart's superior side. The pericardium has two layers because it folds over itself in the shape of the letter U. The inner layer that borders the heart is the visceral pericardium while the outer layer is the parietal pericardium. The space between the two layers is called the pericardial cavity. The heart sits in the cavity much like a fist punching into a balloon. The balloon surrounds the lower part of the fist with a two-layered sac, with the top of the balloon, where it contacts the fist, being analogous to the visceral pericardium. The bottom of the balloon, where it is tied off, is analogous to the parietal pericardium. The air within the balloon is analogous to the pericardial cavity. [\[Return to Figure 3.7\]](#).

# COLOR AND ONCOLOGY

---

## Color

You will learn words in later chapters that use color to describe a cell, a structure, or a disease state. Here are the combining forms for these colors.

**chrom/o**: color, colored

**chlor/o**: green

**cyan/o**: blue

**erythr/o**: red

**leuk/o**: white

**melan/o**: black

**xanth/o**: yellow

## Oncology

You will learn terms in later chapters for various types of tumors and cancers. These are examples of **neoplasms**, or newly grown tissue in the body.

A tumor or cancer is classified as **benign** (noncancerous, or remaining within the tissue in which it developed) or **malignant** (cancerous, or capable of spreading to other tissues). Benign tumors don't always cause major health problems, but if they compress other tissue, nerves, or blood vessels, the patient may choose to get them surgically removed. Some benign tumors are considered precancerous and may develop into malignant tumors eventually, but this is not often the case. When a malignant tumor has spread to other tissues or organs, it is said to have **metastasized**.

A tumor or cancer is named after the type of tissue in which it originated and whether it is benign or malignant.

## Word Roots

**cancer/o, carcin/o**: cancer

**onc/o**: tumor, mass

## Suffixes

- oma**: tumor, swelling (noun); when used alone, it typically refers to a benign tumor
- carcinoma**: malignant tumor that originates in epithelium (noun)
- plasia**: process of formation/growth (noun)
- plasm**: substance, formation, growth, something that has grown (noun)
- sarcoma**: malignant tumor of bone, blood vessels, cartilage, nerves, muscles, fat, joints, tendons, and ligaments (noun)

## Disease and Disorder Oncology Terms

- adenocarcinoma**: malignant tumor of glandular tissue
- adenoma**: benign tumor of glandular tissue
- epithelioma**: tumor composed of epithelial tissue
- fibroma**: benign tumor composed of fibrous tissue
- fibrosarcoma**: malignant tumor composed of fibrous tissue
- lipoma**: benign tumor composed of adipose tissue
- liposarcoma**: malignant tumor composed of adipose tissue
- myoma**: benign tumor composed of muscle tissue
- myosarcoma**: malignant tumor composed of muscle tissue
- neoplasm**: literally “new growth”; used to describe growth of abnormal tissue, either benign or malignant
- neuroma**: benign tumor composed of nerve tissue
- neurosarcoma**: malignant tumor composed of nerve tissue

## Career Terms

- oncologist**: a physician who specializes in diagnosing, treating, and studying tumors and cancers
- oncology**: the study of tumors and cancers

# REFERENCES

---

[“Tissue Types”](#) section contains material adapted from Betts, J.G., Young, K.A., Wise, J.A., Johnson, E., Poe, B., Kruse, D. H., Korol, O., Johnson, J.E., Womble, M. & DeSaix, P. (2013). *Anatomy and Physiology*. OpenStax. <http://cnx.org/content/col11496/latest/>

[CrashCourse]. (2015, January 6). [Introduction to anatomy & physiology: Crash course A&P #1](#) [Video]. YouTube. <https://youtu.be/uBG12BujkPQ>

Unless otherwise indicated, this chapter contains material adapted from [Building a Medical Terminology Foundation](#), by Kimberlee Carter and Marie Rutherford and is used under a [CC BY 4.0 international license](#), which itself contained material adapted from [Anatomy and Physiology](#) (on OpenStax), by Betts, et al. and is used under a [CC BY 4.0 international license](#).

# PRACTICE

---

The following activity will help you practice what you've learned in this chapter.

## Locate the Cavities

Click and drag each term to the box corresponding with the anatomic structure, body part, body plane, or body region for that term.



*An interactive H5P element has been excluded from this version of the text. You can view it online here:*

<https://louis.pressbooks.pub/medicalterminology/?p=2185#h5p-4>

## PART IV

# MUSCULOSKELETAL SYSTEM

## Learning Objectives

When completing this chapter, the learner will be able to do the following:

- Identify the anatomy of the musculoskeletal system
- Describe the main functions of the musculoskeletal system
- Spell the medical terms of the musculoskeletal system and use correct abbreviations
- Pronounce the medical terms of the musculoskeletal system and use correct abbreviations
- Identify the medical specialties associated with the musculoskeletal system
- Explore common diseases, disorders, and procedures related to the musculoskeletal system

## Introduction

The skeletal system forms the framework of the body. It is the body system composed of bones, cartilage, and ligaments. Each bone serves a particular function and varies in size, shape, and strength. Bones are weight-bearing structures in your body and can therefore change in thickness as you gain or lose weight. The skeletal system performs the following critical functions for the human body:

- supports the body
- facilitates movement
- protects internal organs
- produces blood cells
- stores and releases minerals and fat

When most people think of muscles, they think of the muscles that are visible just under the skin, particularly of the limbs. These are skeletal muscles, so named because most of them move the skeleton. But there are two additional types of muscles that make up the muscular system: the smooth muscle and the cardiac muscle. The body has over 600 muscles, which contribute significantly to the body's weight.

# BASIC ANATOMY & PHYSIOLOGY OF THE MUSCULOSKELETAL SYSTEM

---

## The Skeletal System

The skeletal system includes all of the bones, cartilages, and ligaments of the body that support and give shape to the body and body structures. The **skeleton** consists of the bones of the body. For adults, there are 206 bones in the skeleton. Younger individuals have higher numbers of bones because some bones fuse together during childhood and adolescence to form an adult bone. The primary functions of the skeleton are to provide a rigid, internal structure that can support the weight of the body against the force of gravity and to provide a structure upon which muscles can act to produce movements of the body.

In addition to providing for support and movements of the body, the skeleton has protective and storage functions. It protects the internal organs, including the brain, spinal cord, heart, lungs, and pelvic organs. The bones of the skeleton serve as the primary storage site for important minerals such as calcium and phosphate. The bone marrow found within bones stores fat and houses the blood-cell-producing tissue of the body.

The skeleton is subdivided into two major divisions: the **axial** and **appendicular** (see [Figure 4.1](#)).

The **axial skeleton** forms the vertical, central axis of the body and includes all bones of the head, neck, chest, and back. It serves to protect the brain, spinal cord, heart, and lungs. It also serves as the attachment site for muscles that move the head, neck, and back and for muscles that act across the shoulder and hip joints to move their corresponding limbs.

The axial skeleton of the adult consists of 80 bones, including the **skull**, the **vertebral column**, and the **thoracic cage**. The skull is formed by 22 bones. Also associated with the head are an additional seven bones, including the **hyoid bone** and the **ear ossicles** (three small bones found in each middle ear). The vertebral column consists of 24 bones, each called a **vertebra**, plus the **sacrum** and **coccyx**. The thoracic cage includes the 12 pairs of **ribs** and the **sternum**, the flattened bone of the anterior chest.

Vertebral Column with Abbreviations:

- **Cervical:** C1 to C7; the first 7 vertebrae in the neck region
- **Thoracic:** T1 to T12; the next 12 vertebrae that form the outward curvature of the spine
- **Lumbar:** L1 to L5; the next 5 vertebrae that form the inner curvature of the spine
- **Sacrum:** the triangular bone at the base of the spine
- **Coccyx:** the tailbone

The **appendicular skeleton** includes all bones of the upper and lower limbs, plus the bones that attach each limb to the axial skeleton. There are 126 bones in the appendicular skeleton of an adult.

Most bones connect to at least one other bone in the body. The areas where bones meet bones or where bones meet cartilage are called **articulations**. Joints can be classified based on their ability to move. At **movable** joints, the articulating surfaces of the adjacent bones can move smoothly against each other. However, other joints may be connected to each other by connective tissue or cartilage. These joints are designed for stability and provide for little or no movement. Importantly, joint stability and movement are related to each other. This means that stable joints allow for little or no mobility between the adjacent bones. Conversely, joints that provide the most movement between bones are the least stable.

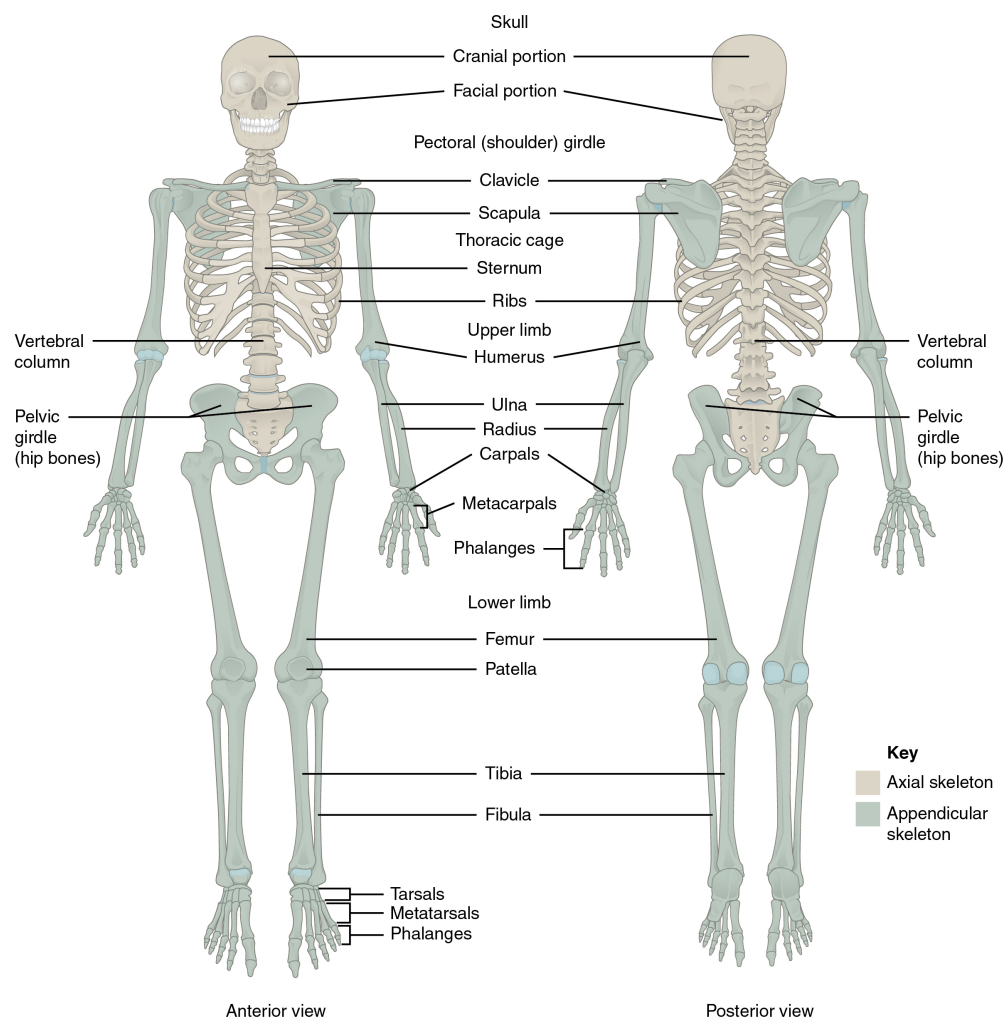


Figure 4.1 Axial and Appendicular Skeleton. The axial skeleton supports the head, neck, back, and chest and thus forms the vertical axis of the body. It consists of the skull, vertebral column (including the sacrum and coccyx), and the thoracic cage, formed by the ribs and sternum. The appendicular skeleton is made up of all bones of the upper and lower limbs. From Betts, et al., 2013. Licensed under [CC BY 4.0](https://creativecommons.org/licenses/by/4.0/). [Image description.]

It is important to note the difference between male and female anatomic structures. The pelvis is the only way to differentiate the sex of humans in the skeletal system.

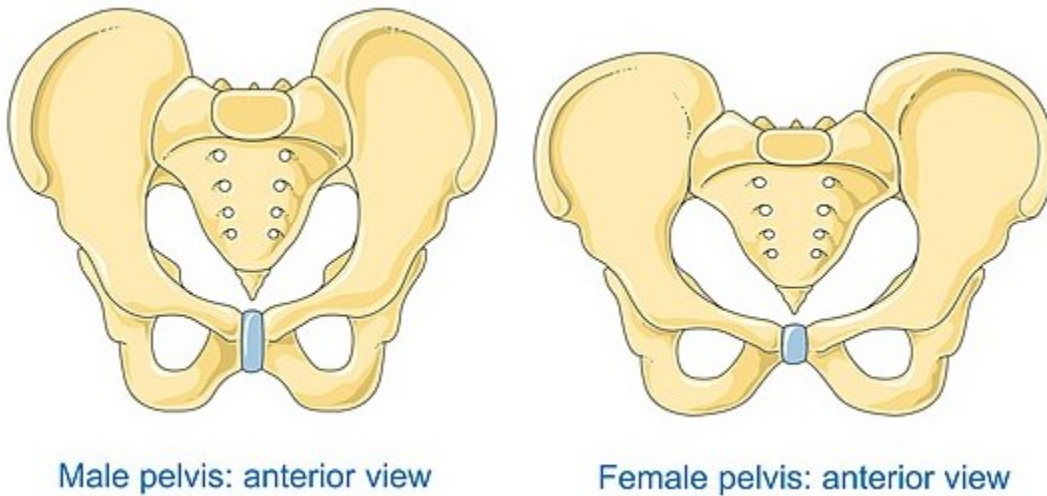


Figure 4.2 Comparison of Male and Female Pelvis. The male pelvis has a heavier bone structure, is narrower and deeper in shape, has a rounder inlet, and has a pubic arch with an acute angle. The female pelvis has a lighter bone structure, has a wider and shallower shape, has an oval-shaped inlet, and has a pubic arch with an obtuse angle. From Servier. Licensed [CC BY-SA 3.0](https://creativecommons.org/licenses/by-sa/3.0/).

## Watch this video:

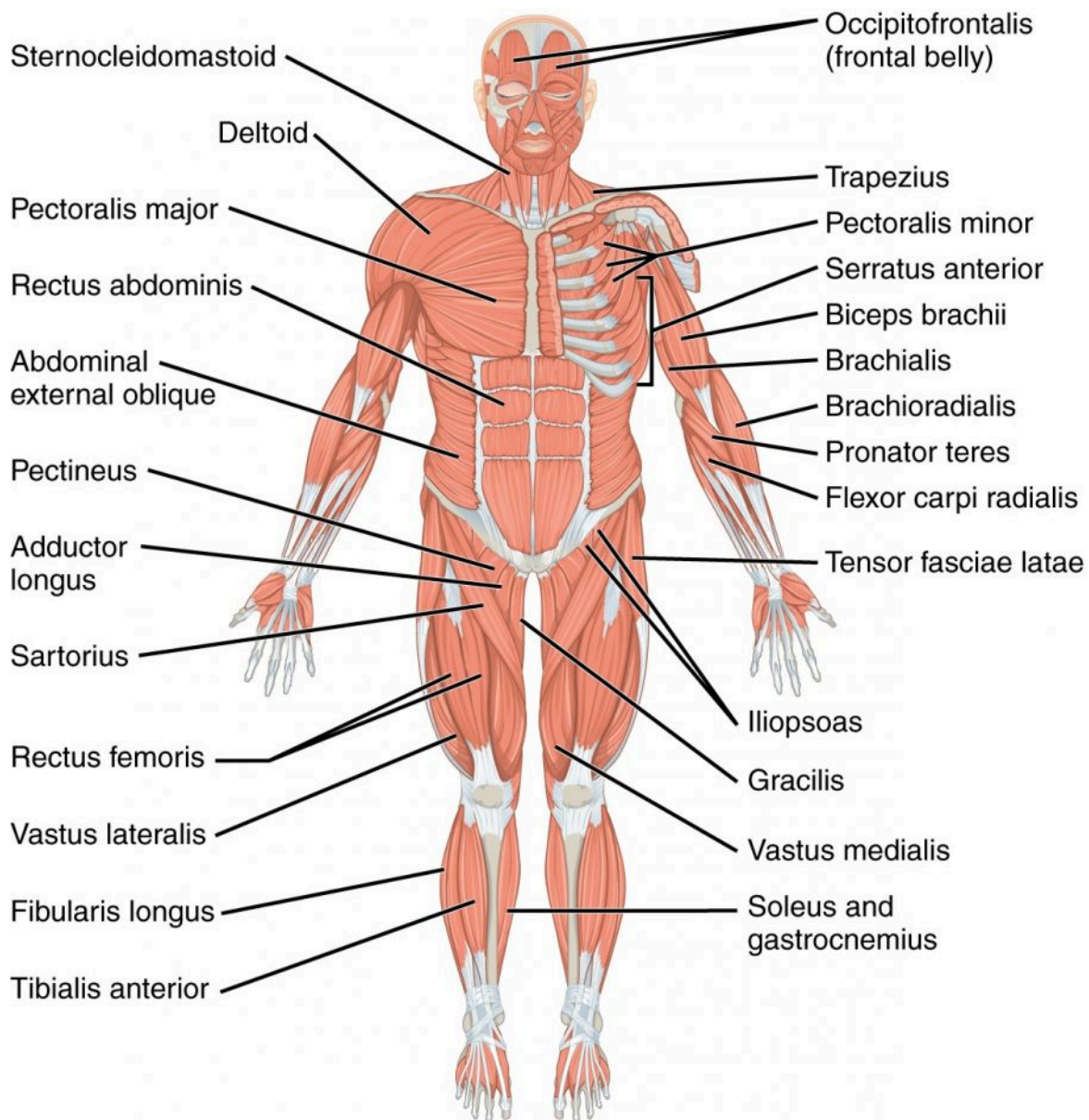


One or more interactive elements has been excluded from this version of the text. You can view them online here: <https://louis.pressbooks.pub/medicalterminology/?p=1907#oembed-1>

Media 4.1 [Bones, part 1, Crash Course A&P #19](#) [Online Video]. Copyright 2015 by [CrashCourse](#).

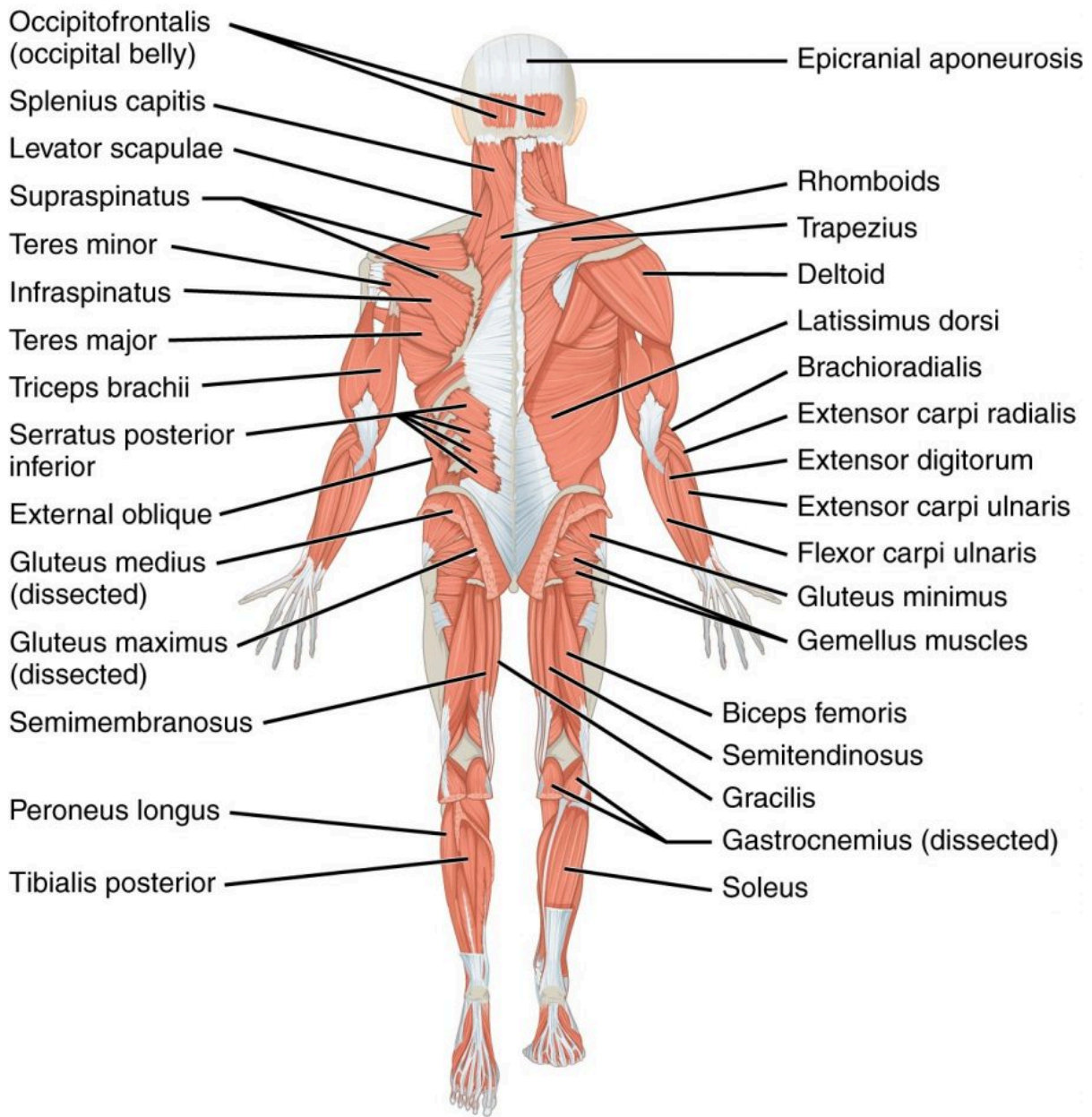
# Muscles

Muscle is one of the four primary tissue types of the body. Muscle tissue covers the entire body (see [Figure 4.3](#) and [Figure 4.4](#)) and is made up of specialized cells called fibers.



Major muscles of the body.  
Right side: superficial; left side: deep (anterior view)

Figure 4.3 Anterior View of the Muscle System. Superficial muscles (those at the surface) are shown on the right side of the body, while deep muscles (those underneath the superficial muscles) are shown on the left side of the body. Only the superficial muscles are shown for the legs in this figure. From Betts, et al., 2013. Licensed under [CC BY 4.0](#). [\[Image description.\]](#)



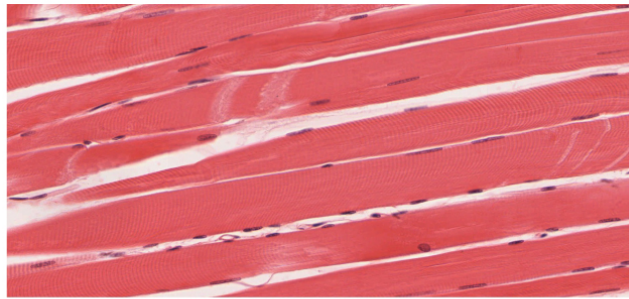
**Major muscles of the body.**  
**Right side: superficial; left side: deep (posterior view)**

Figure 4.4 Posterior View of the Muscle System. Superficial muscles (those at the surface) are shown on the right side of the body, while deep muscles (those underneath the superficial muscles) are shown on the left side of the body. Both superficial and deep muscles are shown for the legs in this figure. From Betts, et al., 2013. Licensed under [CC BY 4.0](https://creativecommons.org/licenses/by/4.0/). [Image description.]

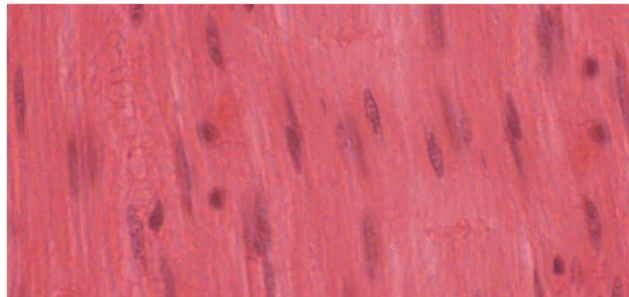
## Types of Muscle Tissue

The body contains three types of muscle tissue: **skeletal muscle**, **cardiac muscle**, and **smooth muscle** (see [Figure 4.5](#)). All three muscle tissues have some properties in common; they all exhibit a quality called **excitability**, as their plasma membranes can change their electrical states (from polarized to depolarized) and send an electrical wave called an action potential along the entire length of the membrane. **Fascia** is fibrous connective tissue that encloses muscles.

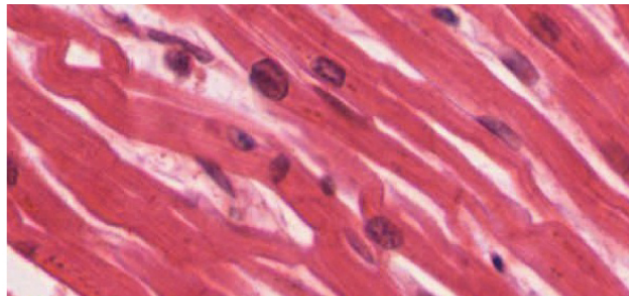
- **Skeletal**—closely associated with the skeletal system, they are striated muscles and are responsible for voluntary muscle movement—such as swallowing, etc.
- **Smooth**—mainly associated with the walls of the internal organs. Also known as visceral muscles and are responsible for involuntary muscle movement—such as breathing, etc.
- **Cardiac**—heart muscle or myocardium. Its striated appearance is similar to a skeletal muscle and is responsible for the pumping of blood. It gives the heartbeat.



(a)



(b)



(c)

Figure 4.5 The Three Types of Muscle Tissue. The body contains three types of muscle tissue: (a) skeletal muscle, (b) smooth muscle, and (c) cardiac muscle. (Micrographs provided by the Regents of University of Michigan Medical School © 2012.) From Betts, et al., 2013. Licensed under [CC BY 4.0](https://creativecommons.org/licenses/by/4.0/).

## Types of Body Movements

Body movement occurs when the bones, joints, and muscles work together (see [Figure 4.6](#) and [Figure 4.7](#)). The different types of movement are listed below:

- **abduction:** moving away from the midline
- **adduction:** moving toward the midline
- **inversion:** turning inward
- **eversion:** turning outward
- **extension:** movement in which a limb is placed in a straight position, increasing the angle between the bone and the joint
- **flexion:** movement in which a limb is bent, decreasing the angle between the bone and the joint
- **pronation:** movement that turns the palm down
- **supination:** movement that turns the palm up
- **rotation:** turning around its own axis

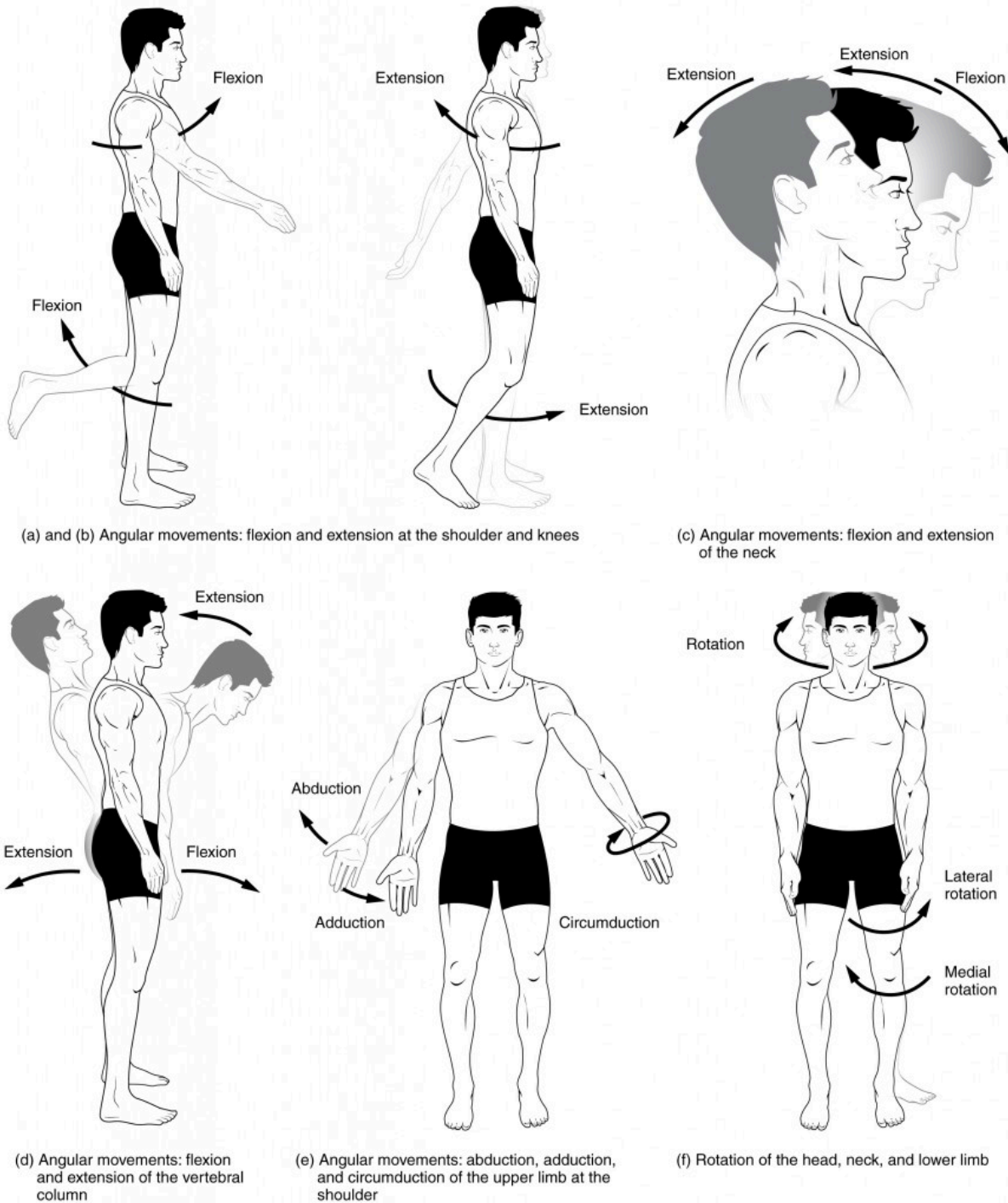


Figure 4.6 Movements of the Body, Part 1. Synovial joints give the body many ways in which to move. (a) and (b) Flexion and extension motions are in the sagittal (anterior and posterior) plane of motion. These movements take place at the shoulder, hip, elbow, knee, wrist, metacarpophalangeal, metatarsophalangeal, and interphalangeal joints. (c) and (d) Anterior bending of the head or vertebral column is flexion, while any posterior-going movement is extension. (e) Abduction and adduction are motions of the limbs, hand, fingers, or toes in the coronal (medial and lateral) plane of movement. Moving the limb or hand laterally away from the body, or spreading the fingers or toes, is abduction. Adduction brings the limb or hand toward or across the midline of the body or brings the fingers or toes together. Circumduction is the movement of the limb, hand, or fingers in a circular pattern using the sequential combination of

flexion, adduction, extension, and abduction motions. Adduction/abduction and circumduction take place at the shoulder, hip, wrist, metacarpophalangeal, and metatarsophalangeal joints. (f) Turning of the head side to side or twisting of the body is rotation. Medial and lateral rotation of the upper limb at the shoulder or lower limb at the hip involves turning the anterior surface of the limb toward the midline of the body (medial or internal rotation) or away from the midline (lateral or external rotation). From Betts, et al., 2013. Licensed under [CC BY 4.0](#). [[Image description](#).]

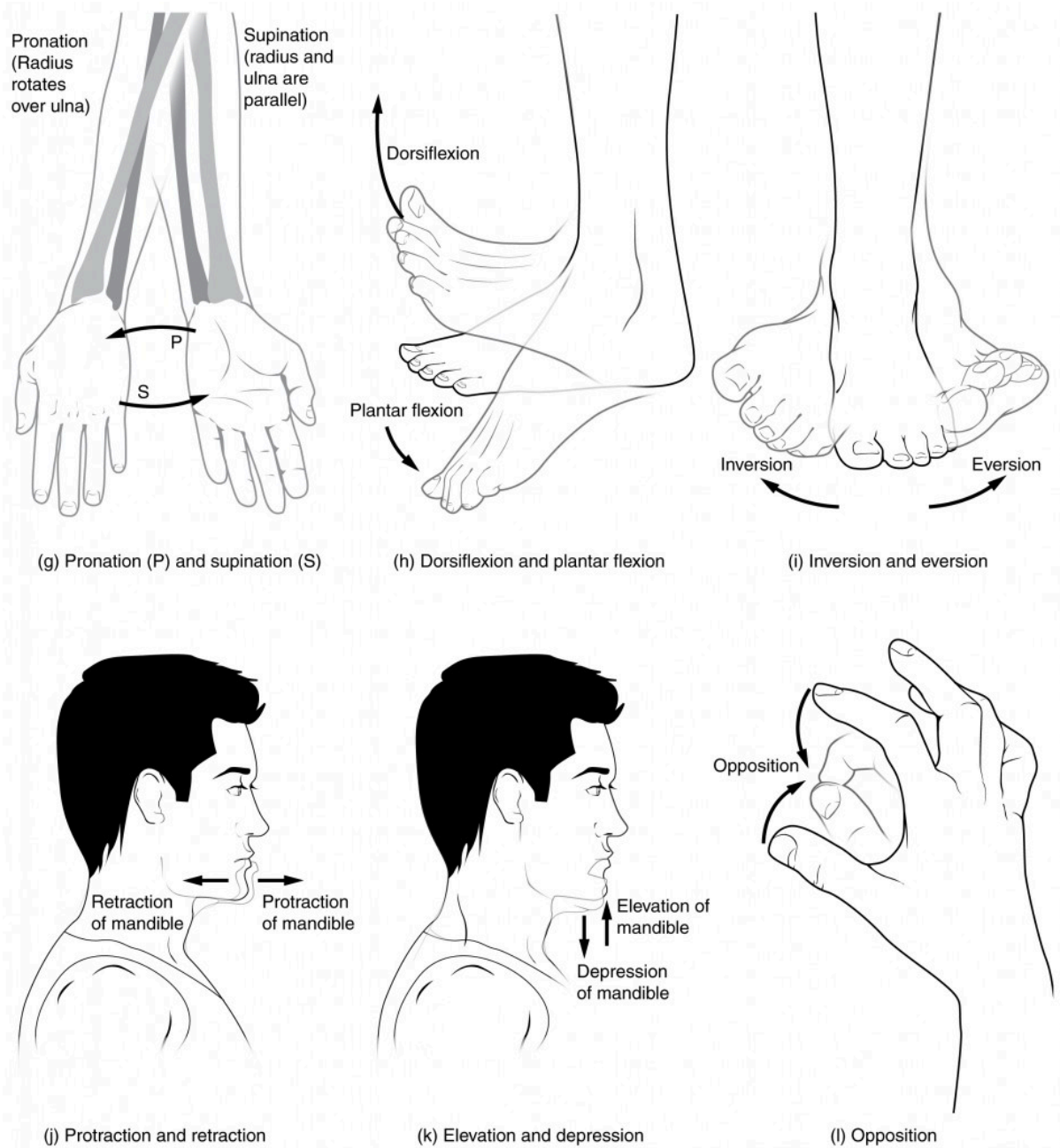


Figure 4.7 Movements of the Body, Part 2. (g) Supination of the forearm turns the hand to the palm forward position in which the radius and ulna are parallel, while forearm pronation turns the hand to the palm-backward position in which the radius crosses over the ulna to form an “X.” (h) Dorsiflexion of the foot at the ankle joint moves the top of the foot toward the leg, while plantar flexion lifts the heel and points the toes. (i) Eversion of the foot moves the bottom (sole) of the foot away from the midline of the body, while foot inversion faces the sole toward the midline. (j) Protraction of the mandible pushes the chin forward, and retraction pulls the chin back. (k) Depression of the mandible opens the mouth, while elevation closes it. (l) Opposition of the thumb brings the tip of the thumb into contact with the tip of the fingers of the same hand, and reposition brings the thumb back next to the index finger. From Betts, et al., 2013. Licensed under [CC BY 4.0](https://creativecommons.org/licenses/by/4.0/).

## Image Descriptions

**Figure 4.1 image description:** This diagram shows the human skeleton and identifies the major bones. The left panel shows the anterior view (from the front) and the right panel shows the posterior view (from the back). Labels read (from the top of skull): skull (cranial portion, facial portion), pectoral shoulder girdle, clavicle, scapula, thoracic cage (sternum, ribs), upper limb (humerus, ulna, radius, carpals, metacarpals, phalanges), vertebral column, pelvic girdle (hip bones), lower limb (femur, patella, tibia, fibula, tarsals, metatarsals, phalanges). [\[Return to Figure 4.1\]](#).

**Figure 4.3 image description:** This diagram shows an anterior view of the muscle system. Labels on the right side of the body read (from top to bottom): sternocleidomastoid, deltoid, pectoralis major, rectus abdominis, abdominal external oblique, pectineus, adductor longus, sartorius, rectus femoris, vastus lateralis, fibularis longus, tibialis anterior. Labels for left side of the body read (from top to bottom): occipitofrontalis (frontal belly), trapezius, pectoralis minor, serratus anterior, biceps brachii, brachialis, brachioradialis, pronator teres, flexor carpi radialis, tensor fasciae latae, iliopsoas, gracilis, vastus medialis, soleus, and gastrocnemius. [\[Return to Figure 4.3\]](#).

**Figure 4.4 image description:** This diagram shows an anterior view of the muscle system. Labels on the left side of the body read (from top to bottom): occipitofrontalis (occipital belly), splenius capitis, levator scapulae, supraspinatus, teres minor, infraspinatus, teres major, triceps brachii, serratus posterior inferior, external oblique, gluteus medius (dissected), gluteus maximus (dissected) semimembranosus, peroneus longus, tibialis posterior. Labels for right side of the body read (from top to bottom): epicranial aponeurosis, rhomboids, trapezius, deltoid, latissimus dorsi, brachioradialis, extensor carpi radialis, extensor digitorum, extensor carpi ulnaris, flexor carpi ulnaris, gluteus minimus, gemellus muscles, biceps femoris, semitendinosus, gracilis, gastrocnemius (dissected), soleus. [\[Return to Figure 4.4\]](#).

**Figure 4.6 image description:** This multi-part image shows different types of movements that are possible by different joints in the body. Labels read (from top, left): (a) and (b) angular movements: flexion and extension at the shoulders and knees, (c) angular movements: flexion and extension of the neck (arrows pointing left and right to indicate movement). Labels (from bottom, left) read: (d) angular movements: flexion and extension of the vertical column, (e) angular movements: abduction, adduction, and circumduction of the upper limb at the shoulder, (f) rotation of the head, neck, and lower limb. [\[Return to Figure 4.6\]](#).

# WORD PARTS AND STRUCTURAL TERMS

---

## Combining Forms

**ankyl/o:** stiff, bent

**aponeur/o:** aponeurosis

**arthr/o:** joint

**burs/o:** bursa

**carp/o:** carpals, wrist

**chondr/o:** cartilage

**clavic/o:** clavicle, collarbone

**clavicul/o:** clavicle, collarbone

**cost/o:** ribs

**crani/o:** cranium

**disk/o:** intervertebral disk

**femor/o:** femur, upper leg bone

**fibul/o:** fibula, lower leg bone

**humer/o:** humerus, upper arm bone

**ili/o:** ilium

**ischi/o:** ischium

**kinesi/o:** movement, motion

**kyph/o:** increased convexity of the spine

**lord/o:** bent forward, increased concavity of the spine

**lumb/o:** loin, lumbar region of the spine

**mandibul/o:** mandible, lower jawbone

**maxill/o:** maxilla, upper jawbone

**menisc/o:** meniscus, crescent

**myel/o:** spinal cord

**oste/o:** bone

**patell/o:** patella, kneecap

**pelv/i:** pelvis, pelvic bone

**pelv/o:** pelvis, pelvic bone

**petr/o:** stone

**phalang/o:** phalanges, bones of finger and toes

**pub/o:** pubis

**rachi/o:** vertebral spine, vertebral column

**radi/o:** nerve root

**scapul/o:** scapula, shoulder blade

**scoli/o:** crooked, curved

**spondyl/o:** vertebra, spine, vertebral column

**stern/o:** sternum, breastbone

**tars/o:** tarsals, ankle bones

**ten/o:** tendon

**tendin/o:** tendon

**tend/o:** tendon

**tibi/o:** tibia, lower leg bone

**uln/o:** ulna, lower arm bone

**vertebr/o:** vertebra, spine, vertebral column

## Prefixes

**a-:** absence of, without

**ab-:** away from

**ad-:** toward

**brady-:** slow

**dys-:** painful, difficult, abnormal, labored

**hyper-:** above, excessive

**inter-:** between

**intra-:** within, in

**poly-:** many, much

**sub-:** below, under

**supra-:** above

**sym-:** together, joined

**syn-:** together, joined

## Suffixes

**-al:** pertaining to

- algia**: pain
- ar**: pertaining to
- asthenia**: weakness
- centesis**: surgical puncture to aspirate fluid
- clasia**: break
- clasis**: break
- clast**: break
- desis**: surgical fixation, fusion
- ectomy**: excision, surgical removal, cutting out
- gram**: the record, radiographic image
- graphy**: process of recording, radiographic imaging
- ic**: pertaining to
- itis**: inflammation
- lysis**: loosening, separating, dissolution
- malacia**: softening
- oid**: resembling
- oma**: tumor
- osis**: abnormal condition
- penia**: abnormal reduction
- physis**: growth
- plasty**: surgical repair
- rrhaphy**: suturing, repairing
- sarcoma**: malignant tumor
- schisis**: split, fissure
- scopy**: process of viewing, visual examination
- tomy**: incision, cut into
- trophy**: nourishment, development

## Structural Terms Built from Word Parts

**skull**: bones of head, made up of cranium and facial bones

**maxilla**: upper jaw

**mandible**: lower jaw

**vertebral column**: made up of bones called vertebrae (pl.) or vertebra (s.) through which the spinal cord runs. The vertebral column protects the spinal cord, supports the head, and provides points of attachment for ribs and muscles.

**clavicle:** collarbone

**scapula:** shoulder blade

**acromion process:** extension of the scapula, which forms the superior point of the shoulder

**sternum:** breastbone

**xiphoid process:** lowest portion of sternum

**ribs:** 12 sets contained in the thoracic cage that protect the heart and lungs

**humerus:** bone in upper arm

**radius:** bone that runs thumb-side of the forearm

**ulna:** bone that runs on the side of the little finger of the forearm

**carpals:** wrist bones

**metacarpals:** bones in the palm of hand

**phalanges:** finger and toe bones

**ilium:** largest part of the hip bone; upper, wing-shaped part on each side of the pelvis

**ischium:** lower, posterior portion of the pelvis on which one sits

**pubis:** anterior portion of pelvis

**pelvis:** made up of three bones fused together (also called pelvic bones and hip bones)

**acetabulum:** large socket in the pelvic bones that holds the head of the femur

**femur:** thigh bone, also referred to as the upper leg bone; the longest and strongest bone in the human body

**patella:** kneecap

**tibia:** medial bone and main weight-bearing bone of the lower leg

**fibula:** lateral, smaller of the lower leg bone

**metatarsals:** foot bones

**tarsals:** ankle bones

**calcaneus:** heel bone of foot

# DISEASES AND DISORDERS

---

## Disease and Disorder Terms Built from Word Parts

**ankylosis:** abnormal condition of stiffness (often referring to fusion of a joint, such as the result of chronic rheumatoid arthritis)

**arthritis:** inflammation of the joint

**bursitis:** inflammation of the bursae

**chondromalacia:** softening of cartilage

**chondrosarcoma:** malignant tumor of cartilage

**cranioschisis:** fissure (split) of the cranium (congenital)

**discitis:** inflammation of the disc

**fasciitis:** inflammation of the fascia (connective tissue enclosing and separating muscle layers)

**fibromyalgia:** pain in the fibrous tissues and muscles (a common condition characterized by widespread pain and stiffness of muscles, fatigue, and disturbed sleep)

**kyphosis:** abnormal condition of a hump (in the thoracic spine; also called swayback)

**lordosis:** abnormal condition of bending forward (in the lumbar spine; also called swayback)

**meniscitis:** inflammation of the meniscus

**myasthenia:** muscle weakness

**myeloma:** tumor of the bone marrow (malignant)

**osteitis:** inflammation of the bone

**osteoarthritis:** inflammation of the bone and joint

**osteocondritis:** inflammation of the bone and cartilage

**osteochondroma:** tumor composed of bone and cartilage (benign)

**osteomalacia:** softening of the bone

**osteomyelitis:** inflammation of the bone and marrow (caused by bacterial infection)

**osteonecrosis:** abnormal condition of bone death (due to lack of blood supply)

**osteopenia:** abnormal reduction of bone mass (caused by inadequate replacement of bone lost to normal bone lysis and can lead to osteoporosis)

**osteopetrosis:** abnormal condition of stonelike bones (very dense bones caused by defective resorption of bone)

**osteosarcoma:** malignant tumor of the bone

**polymyositis:** inflammation of many muscles

**rachischisis:** fissure (split) of the vertebral column (congenital; also called spina bifida)

**rhabdomyolysis:** dissolution of striated muscle (caused by trauma, extreme exertion, or drug toxicity; in severe cases, renal failure can result)

**sarcopenia:** abnormal reduction of connective tissue (such as a loss of skeletal muscle mass in the elderly)

**scoliosis:** abnormal condition of (lateral) curved spine

**spondyloarthritis:** inflammation of the vertebral joints (also called spondyloarthropathy)

**spondylosis:** abnormal condition of the vertebrae (a general term used to describe changes to the spine from osteoarthritis or ankylosis)

**synoviosarcoma:** malignant tumor of the synovial membrane

**tendinitis:** inflammation of the tendon (also spelled tendonitis)

**tenosynovitis:** inflammation of the tendon and synovial membrane

## Disease and Disorder Terms Not Built from Word Parts

**ankylosing spondylitis:** form of arthritis that first affects the spine and adjacent structures and that, as it progresses, causes a forward bend of the spine (also called Strümpell-Marie arthritis or disease or rheumatoid spondylitis)

**bunion:** abnormal prominence of the joint at the base of the great toe, the metatarsal phalangeal joint. It is a common problem, often hereditary or caused by poorly fitted shoes (also called hallux valgus).

**carpal tunnel syndrome:** common nerve entrapment disorder of the wrist caused by compression of the median nerve; symptoms include pain and tingling in portions of the hand and fingers

**compartment syndrome:** painful condition caused by increased pressure within a muscle that can lead to ischemia; acute compartment syndrome is a medical emergency and is caused by severe injury

**dislocation:** displacement of bones in a joint from their normal alignment (also called luxation)

**exostosis:** abnormal benign growth on the surface of a bone (also called spur)

**fracture:** broken bone

**ganglion cyst:** collection of jellylike fluid forming a benign mass arising from joints, most commonly appearing in the wrist, hand, and ankle

**gout:** disease in which an excessive amount of uric acid in the blood causes sodium urate crystals (tophi) to be deposited in the joints, producing arthritis. The great toe is frequently affected.

**herniated disk:** rupture of the intervertebral disk cartilage, which allows the contents to protrude through it, putting pressure on the spinal nerve roots (also called slipped disk, ruptured disk, herniated intervertebral disk, or herniated nucleus pulposus [HNP])

**Lyme disease:** infection caused by a bite from a deer tick infected with *Borrelia burgdorferi*. This bacterium provokes an immune response in the body, the symptoms of which can mimic several musculoskeletal diseases.

Patients may experience fever, headache, and joint pain. A rash (target lesion) may initially arise at the site of the tick bite.

**muscular dystrophy:** group of hereditary diseases characterized by degeneration of muscle and weakness

**myasthenia gravis:** chronic disease characterized by muscle weakness and thought to be caused by a defect in the transmission of impulses from nerve to muscle cell. The face, larynx, and throat are frequently affected; no true paralysis of the muscles exists.

**osteoporosis:** abnormal loss of bone density that may lead to an increase in fractures of the ribs, thoracic and lumbar vertebrae, hips, and wrists after slight trauma (occurs predominantly in postmenopausal women)

**plantar fasciitis:** inflammation of the connective tissue of the sole of the foot (plantar fascia) due to repetitive injury; common cause of heel pain

**repetitive strain injury:** cumulative damage to joint, muscle, or other tissue caused by movements performed over and over again; characterized by pain, swelling, numbness, and lack of strength and flexibility, most commonly affecting the hands, wrists, elbows, and shoulders

**rheumatoid arthritis:** chronic systemic disease characterized by autoimmune inflammatory changes in the connective tissue throughout the body

**rotator cuff disease:** damage to one or more of the four tendons stabilizing the shoulder joint due to injury or degeneration; symptoms may include pain, limited range of motion, and muscle weakness

**spinal stenosis:** narrowing of the spinal canal with compression of nerve roots. The condition is either congenital or due to spinal degeneration. Symptoms are pain radiating to the thigh or lower legs and numbness or tingling in the lower extremities.

**spondylolisthesis:** forward slipping of one vertebra over another

**sprain:** abnormal stretching or tearing of a ligament that supports a joint

**strain:** abnormal stretching and tearing of a muscle or tendon

**subluxation:** partial dislocation of bones and joints

**tarsal tunnel syndrome:** painful foot disorder caused by compression of the posterior tibial nerve as it passes through the ankle

# MEDICAL, SURGICAL, & VIEWING TERMS AND ABBREVIATIONS

---

## Medical Careers & Professional Terminology

**radiologic technologist (RT):** Creates images of patients' bodies using medical equipment. The images help doctors diagnose and treat diseases and injuries. Technologists assist physicians in procedures as well as prepare and administer contrast agents in order to better visualize the anatomy of interest. Rad Techs need to be licensed in many states in order to administer x-rays (x-radiation). Many schools offer degrees or certificates to achieve before taking your registry in order to become licensed.

**specialized radiologic technologist:** Radiologic technologists can specialize in Computed Tomography (CT); Magnetic Resonance Imaging (MRI); Bone Densitometry (D); Positron Emission Tomography (PET); Nuclear Medicine (NM); and Radiation Therapy (RT). These specialties could be completed while on the job or with an additional year of education depending on the area chosen. Technologists can become certified in multiple modalities by completing requirements and passing the registry for the specified modality of interest.

**radiologist:** A medical doctor that specializes in diagnosing and treating injuries and diseases using medical imaging procedures, or exams, from the Radiology Department. Procedures could include x-rays, Computed Tomography (CT), Magnetic Resonance Imaging (MRI), Nuclear Medicine (NM), Positron Emission Tomography (PET), and Ultrasound (Sonography). Radiologists complete at least 13 years of training, including medical school, a four-year residency, and most often, an additional one- or two-year fellowship of very specialized training, such as radiation oncology, pediatric radiology, or interventional radiology. They are certified by the American Board of Radiology, and they have exacting requirements for continuing medical education throughout their practicing years.

**physical therapist assistant (PTA):** Provides physical therapist services under the direction and supervision of a physical therapist. PTAs implement components of patient care, obtain data related to the treatments provided, and collaborate with the PT to modify care as necessary. They assist patients in recovery after injuries, postoperative care, and pain management through strategic exercises and therapeutic methods. PTAs have completed a minimal associate-level degree and passed a licensing exam.

**physical therapist (PT):** Physicians who diagnose and treat patients by prescribing exercises, hands-on care, and patient education. PTs are required to obtain a doctorate in physical therapy. This typically takes 3 years, and graduates must also pass a state licensure exam.

**orthopedic surgeon:** A medical doctor who completes an additional 5 years of specialized training in the prevention, diagnosis, treatment, and surgery of disorders and diseases related to the musculoskeletal systems.

**neurologist:** A medical doctor who completes an additional 5 years of specialized training in the prevention, diagnosis, and treatment of disorders and conditions related to the brain, spinal cord, nerves, and muscles.

**kinesiologist:** A regulated health care professional with a 4-year degree in kinesiology or a related discipline. Kinesiologists work in a variety of settings that assist people with pain management, injury prevention, and health promotion through biomechanics.

**rheumatologist:** A medical doctor who has additional training as an internist with a subspecialty in rheumatology. These doctors have special interests in autoimmune disorders and their impact on the musculoskeletal system.

**doctor of chiropractic (DC)/chiropractor:** A health care practitioner with 7 years of education, supervised internships, and national examinations. They are trained in prevention, assessment, and treatment of the spine, muscular system, and nervous system. Chiropractors focus on spinal adjustments, nutrition, and preventing injury without the use of pharmaceuticals or surgical procedures.

## Imaging Techniques/Procedures for the Organ System Built from Word Parts

**arthrography:** radiographic imaging of a joint (with contrast media)

**myelography:** radiographic imaging of the spinal cord (with contrast media)

**arthroscopy:** visual examination of a joint

**electromyogram:** record of the (intrinsic) electrical activity in the (skeletal) muscle

## Imaging Techniques/Procedures for the Organ System Not Built from Word Parts

**dual x-ray absorptiometry (DXA):** radiographic imaging, usually of the lumbar spine and hips, to measure bone loss and bone mineral density; the procedure utilizes low doses of radiation and is used in the diagnosis of osteoporosis and monitoring of treatment (also called dual-energy x-ray absorptiometry [DEXA], bone densitometry, and bone density test)

**bone markers:** blood and urine tests to determine the rate of bone turnover (resorption and formation); often used with DXA to diagnose and monitor treatment of osteoporosis and other bone disorders

**muscle biopsy:** removal of muscle tissue using a needle or small incision; used to assess musculoskeletal abnormalities involving weakness or pain such as muscular dystrophy, myasthenia gravis, and polymyositis

## Diagnostic Imaging Procedures

**bone densitometry:** a method of determining the density of bone by radiographic techniques used to diagnose osteoporosis; dual x-ray absorptiometry (DXA) is commonly used for this test

**bone scan:** (nuclear medicine test) used to detect the presence of metastatic disease of the bone and to monitor degenerative bone disease

**magnetic resonance:** used to evaluate the bones and soft tissue of the shoulders, hips, elbows, knees, ankles, feet, and spinal cord for stenosis, spinal cord defects, and degenerative disk changes

**radiography:** (radiographic imaging) of the bones and joints is used to identify fractures or tumors, monitor healing, or identify abnormal structures.

**single-photon emission computed tomography (SPECT):** of the bone is an even more sensitive nuclear method for detecting bone abnormalities

## Surgical Techniques/Procedures Used in the Organ System

**arthrocentesis:** surgical puncture to aspirate fluid from a joint

**arthrodesis:** surgical fixation of a joint (a.k.a. joint fusion)

**arthroplasty:** surgical repair of a joint

**bursectomy:** excision of a bursa

**carpectomy:** excision of a carpal bone

**chondrectomy:** excision of cartilage

**chondroplasty:** surgical repair of cartilage

**costectomy:** excision of a rib

**cranioplasty:** surgical repair of the skull

**craniotomy:** incision into the cranium (as for surgery of the brain)

**discectomy:** excision of an intervertebral disk (a portion of the herniated disk is removed to relieve pressure on nerve roots; uses a larger incision than microdiscectomy)

**fasciotomy:** incision into fascia (to relieve tension or pressure)

**laminectomy:** excision of a lamina (often performed to relieve pressure on the nerve roots in the lower spine caused by a herniated disk and other conditions)

**maxillectomy:** excision of the maxilla

**meniscectomy:** excision of a meniscus (performed for a torn cartilage)

**microdiscectomy:** small excision of an intervertebral disk (minimally invasive surgery to remove a portion of the herniated disk to relieve pressure on nerve roots)

**myorrhaphy:** suturing of a muscle

**osteotomy:** incision into the bone

**phalangectomy:** excision of a finger or toe bone

**rachiotomy:** incision into the vertebral column

**spondylosyndesis:** fusing together of the vertebrae (also called spinal fusion)

**synovectomy:** excision of the synovial membrane (of a joint)

**tarsectomy:** excision of (one or more) tarsal bones

**tenomyoplasty:** surgical repair of the tendon and muscle

**tenorrhaphy:** suturing of a tendon

**vertebroplasty:** surgical repair of a vertebra (usually performed for compression fractures due to osteoporosis)

## Abbreviations Commonly Used with the Organ System

### Disease and Disorders

**CTS:** carpal tunnel syndrome

**Fx:** fracture

**HNP:** herniated nucleus pulposus

**MD:** muscular dystrophy

**MG:** myasthenia gravis

**OA:** osteoarthritis

**PM:** polymyositis

**RA:** rheumatoid arthritis

**RSI:** repetitive strain injury

### Diagnostic

**DEXA:** (spoken as a whole word): dual-energy x-ray absorptiometry

**DXA:** (spoken as a whole word): dual x-ray absorptiometry

**EMG:** electromyogram

### Treatment

**THA:** total hip arthroplasty

**TKA:** total knee arthroplasty

## Medical Specialties

**DC:** Doctor of Chiropractic

**DO:** Doctor of Osteopathy

**Ortho:** Orthopedics

## Descriptive

**C1-C7:** cervical vertebrae

**T1-T12:** thoracic vertebrae

**L1-L5:** lumbar vertebrae

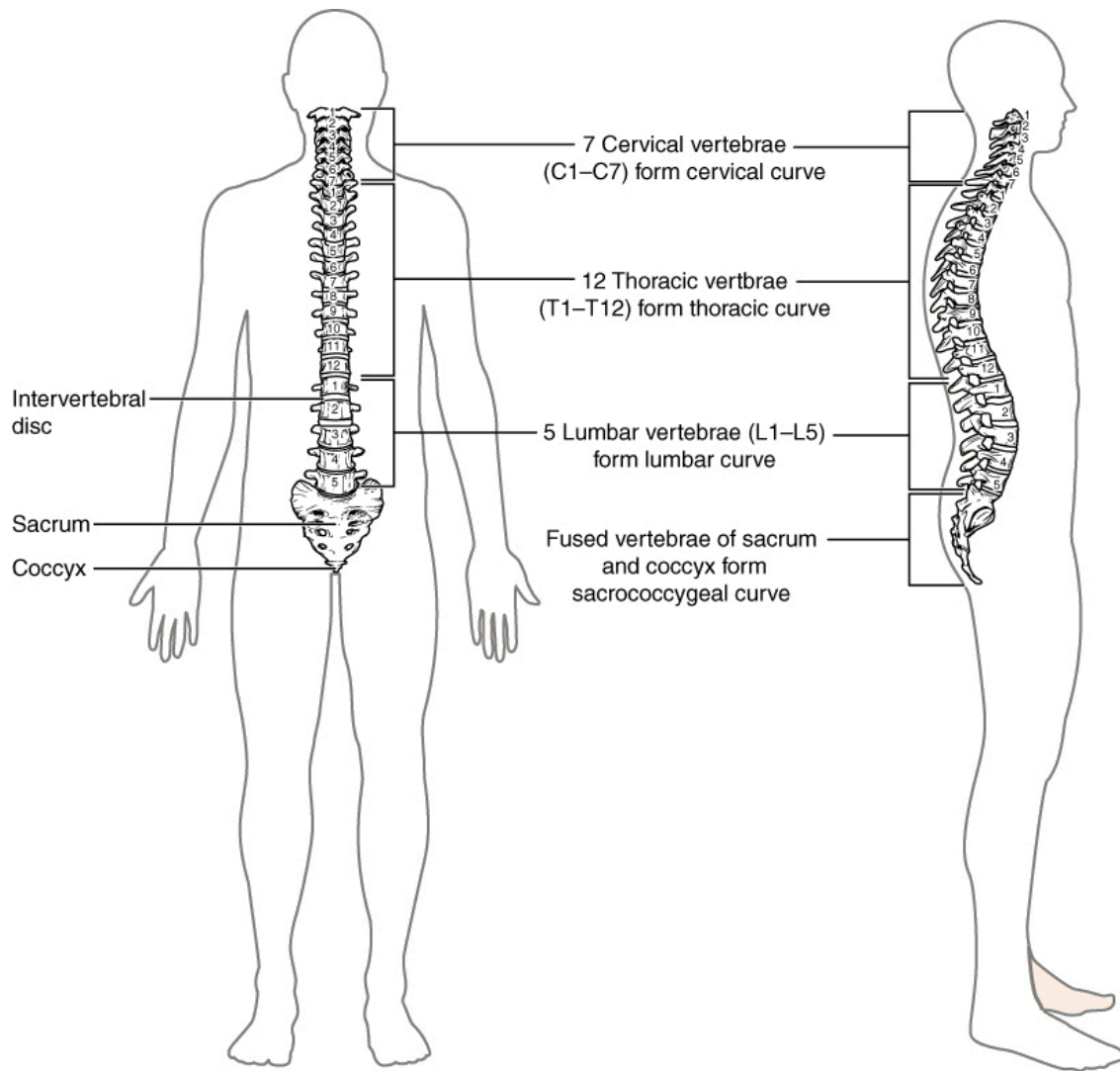


Figure 4.6 Vertebral Column. The adult vertebral column consists of 24 vertebrae, plus the sacrum and coccyx. The vertebrae are divided into three regions: cervical C1–C7 vertebrae, thoracic T1–T12 vertebrae, and lumbar L1–L5 vertebrae. The vertebral column is curved, with two primary curvatures (thoracic and sacrococcygeal curves) and two secondary curvatures (cervical and lumbar curves). From Betts, et al., 2013. Licensed under CC BY 4.0. [\[Image description.\]](#)

## Medical Terms Practice

For each card, click the speaker icon to hear the correct pronunciation of the listed term. Practice saying the term to yourself, then attempt to define the term from memory. Click “Turn” to flip the card and see the definition. Use the right and left arrows to toggle through the cards in each set.



*An interactive H5P element has been excluded from this version of the text. You can view it online here:*

<https://louis.pressbooks.pub/medicalterminology/?p=1918#h5p-87>



*An interactive H5P element has been excluded from this version of the text. You can view it online here:*

<https://louis.pressbooks.pub/medicalterminology/?p=1918#h5p-89>



*An interactive H5P element has been excluded from this version of the text. You can view it online here:*

<https://louis.pressbooks.pub/medicalterminology/?p=1918#h5p-94>

## Image Description

**Figure 4.6 image description:** This image shows the structure of the vertebral column. The left panel shows the front view of the vertebral column. Labels and the right panel show the side view of the vertebral column. labels read (from top): 7 cervical vertebrae (C1-C7) form cervical curve, 12 thoracic vertebrae (T1-T12) form thoracic curve, intervertebral disc, 5 lumbar vertebrae (L1-L5) form lumbar curve, Fused vertebrae of sacrum and coccyx form sacrococcygeal curve, sacrum, coccyx. [\[Return to Figure 4.6\].](#)

# REFERENCES

---

- Arthritis Society. (2020). [Osteoarthritis](https://arthritis.ca/about-arthritis/arthritis-types-(a-z)/types/osteoarthritis). [https://arthritis.ca/about-arthritis/arthritis-types-\(a-z\)/types/osteoarthritis](https://arthritis.ca/about-arthritis/arthritis-types-(a-z)/types/osteoarthritis)
- Body Restoration. (2020). [Electromyography \(EMG\) test: Diagnosing nerve and muscle injuries](https://bodyrestoration.ca/electromyography-test-edmonton-2/). <https://bodyrestoration.ca/electromyography-test-edmonton-2/>
- Canadian Chiropractic Association. (2020). [Regulation and education](https://www.chiropractic.ca/about-chiropractic/canadian-chiropractors/regulation-and-education/). <https://www.chiropractic.ca/about-chiropractic/canadian-chiropractors/regulation-and-education/>
- Canadian Chiropractic Association. (2020a). [How our experts can help](https://www.chiropractic.ca/about-chiropractic/how-our-experts-can-help/). <https://www.chiropractic.ca/about-chiropractic/how-our-experts-can-help/>
- Canadian Medical Association. (2018, August). [Orthopedic surgery profile](https://www.cma.ca/sites/default/files/2019-01/orthopedic-surgery-e.pdf). CMA Specialty Profiles. <https://www.cma.ca/sites/default/files/2019-01/orthopedic-surgery-e.pdf>
- Canadian Medical Association. (2018a, August). [Rheumatology profile](https://www.cma.ca/sites/default/files/2019-01/rheumatology-e.pdf). CMA Specialty Profiles. <https://www.cma.ca/sites/default/files/2019-01/rheumatology-e.pdf>
- Canadian Medical Association. (2018b, August). [Neurology profile](https://www.cma.ca/sites/default/files/2019-01/neurology-e.pdf). CMA Specialty Profiles. <https://www.cma.ca/sites/default/files/2019-01/neurology-e.pdf>
- Canadian Orthopaedic Foundation. (n.d.). [Long bone fractures](https://whenithurtstomove.org/about-orthopaedics/conditions-and-ailments/long-bone-fractures/). <https://whenithurtstomove.org/about-orthopaedics/conditions-and-ailments/long-bone-fractures/>
- Canadian Physiotherapy Association. (2020). [Physiotherapy in Canada](https://physiotherapy.ca/physiotherapy-canada). <https://physiotherapy.ca/physiotherapy-canada>
- Canadian Women's Health Network. (2012). [Fibromyalgia](http://www.cwhn.ca/node/40784). <http://www.cwhn.ca/node/40784>
- Centers for Disease Control and Prevention. (2019). [Arthritis basics](https://www.cdc.gov/arthritis/basics/index.html). CDC Arthritis Program. <https://www.cdc.gov/arthritis/basics/index.html>
- Centers for Disease Control and Prevention. (2019, April 30). [What is cerebral palsy?](https://www.cdc.gov/ncbddd/cp/facts.html) CDC. <https://www.cdc.gov/ncbddd/cp/facts.html>
- Centers for Disease Control and Prevention. (2020). [Rheumatoid arthritis](https://www.cdc.gov/arthritis/basics/rheumatoid-arthritis.html). CDC Arthritis Program. <https://www.cdc.gov/arthritis/basics/rheumatoid-arthritis.html>
- College of Kinesiologists of Ontario. (n.d.). [About kinesiology](https://www.coko.ca/patients-and-clients/about-kinesiology/). <https://www.coko.ca/patients-and-clients/about-kinesiology/>
- [CrashCourse]. (2015, May 18). [The Skeletal System: Crash course A&P #19](https://youtu.be/rDGqkMHPDqE) [Video]. YouTube. <https://youtu.be/rDGqkMHPDqE>
- [CrashCourse]. (2015, July 15). [Muscles, part 2—organismal level: Crash course A&P #22](https://youtu.be/I80Xx7pA9hQ) [Video]. YouTube. <https://youtu.be/I80Xx7pA9hQ>

- Choy, G., & MacMullan, P. (2017). *Gout*. Arthritis Society. [https://arthritis.ca/about-arthritis/arthritis-types-\(a-z\)/types/gout](https://arthritis.ca/about-arthritis/arthritis-types-(a-z)/types/gout)
- Government of Canada. (2013). *Bone cancer*. Public Health Agency of Canada. <https://www.canada.ca/en/public-health/services/chronic-diseases/cancer/bone-cancer.html>
- Government of Canada. (2018). *Osteoporosis*. Public Health Agency of Canada. <https://www.canada.ca/en/public-health/services/chronic-diseases/osteoporosis.html>
- Healthwise Staff. (2018, September 20). *Carpal tunnel syndrome: Topic overview*. HealthLink BC. <https://www.healthlinkbc.ca/health-topics/hw213308>
- Leung, J. (2016, November 25). *Magnetic resonance imaging patterns of muscle involvement in genetic muscle diseases: a systematic review*. *Journal of Neurology*, 264(7), 1320-1333. <https://dx.doi.org/10.1007%2Fs00415-016-8350-6>
- Mayo Clinic Staff. (2019, May 21). *Electromyography (EMG)*. Mayo Clinic Patient Care and Information. <https://www.mayoclinic.org/tests-procedures/emg/about/pac-20393913>
- Mayo Clinic Staff. (2018). *Osteomyelitis*. Mayo Clinic Patient Care and Health Information. <https://www.mayoclinic.org/diseases-conditions/osteomyelitis/symptoms-causes/syc-20375913>
- Mayo Clinic Staff. (2018a). *Arthroscopy*. Mayo Clinic Patient Care and Health Information. <https://www.mayoclinic.org/tests-procedures/arthroscopy/about/pac-20392974>
- Muscular Dystrophy Canada. (2020). *About Neuromuscular disorders: Duchenne muscular dystrophy*. <https://muscle.ca/discover-md/types-of-neuromuscular-disorders/>
- Office of Communications and Public Liaison. (2020). *Myasthenia gravis fact sheet*. National Institute of Neurological Disorders and Stroke. <https://www.ninds.nih.gov/Disorders/Patient-Caregiver-Education/Fact-Sheets/Myasthenia-Gravis-Fact-Sheet>
- Ontario Association of Radiologists. (2020). *X-ray*. <https://oarinfo.ca/patient-info/radiology-medical-services/x-ray>
- Ontario Federation for Cerebral Palsy. (2018). *About cerebral palsy*. OFCP. <https://www.ofcp.ca/about-cerebral-palsy>
- National Cancer Institute. *Dual x-ray absorptiometry*. National Institutes of Health. <https://www.cancer.gov/publications/dictionaries/cancer-terms/def/dual-x-ray-absorptiometry>

Unless otherwise indicated, this chapter contains material adapted from [Building a Medical Terminology Foundation](#), by Kimberlee Carter and Marie Rutherford and is used under a [CC BY 4.0 international license](#), which itself contained material adapted from [Anatomy and Physiology](#) (on OpenStax), by Betts, et al. and is used under a [CC BY 4.0 international license](#).

# PRACTICE

---

The following activities will help you practice what you've learned in this chapter.

## Skeletal System Anatomy

Click and drag each term to the box corresponding with the anatomic structure, body part, body plane, or body region for that term.



*An interactive H5P element has been excluded from this version of the text. You can view it online here:*

<https://louis.pressbooks.pub/medicalterminology/?p=2159#h5p-88>

## Operative Report—1



*An interactive H5P element has been excluded from this version of the text. You can view it online here:*

<https://louis.pressbooks.pub/medicalterminology/?p=2159#h5p-90>

## Operative Report—2



*An interactive H5P element has been excluded from this version of the text. You can view it*



online here:

<https://louis.pressbooks.pub/medicalterminology/?p=2159#h5p-91>

## Referral Letter



*An interactive H5P element has been excluded from this version of the text. You can view it online here:*

<https://louis.pressbooks.pub/medicalterminology/?p=2159#h5p-96>

## Vocabulary Reinforcement Activities

Click the term that correctly answers each question or completes each sentence.



*An interactive H5P element has been excluded from this version of the text. You can view it online here:*

<https://louis.pressbooks.pub/medicalterminology/?p=2159#h5p-92>



*An interactive H5P element has been excluded from this version of the text. You can view it online here:*

<https://louis.pressbooks.pub/medicalterminology/?p=2159#h5p-97>

# PART V

# NERVOUS SYSTEM

## Learning Objectives

When completing this chapter, the learner will be able to do the following:

- Identify the anatomy of the nervous system
- Describe the main functions of the nervous system
- Spell the medical terms of the nervous system and use correct abbreviations
- Identify the medical specialties associated with the nervous system
- Explore common diseases, disorders, and procedures related to the nervous system

## Introduction

The picture you have in your mind of the nervous system probably includes the brain, the nervous tissue contained within the cranium, and the spinal cord, the extension of nervous tissue within the vertebral column. That suggests it is made of two organs—and you may not even think of the spinal cord as an organ—but the nervous system is a very complex structure. Within the brain, many different and separate regions are responsible for many different and separate functions. It is as if the nervous system is composed of many organs that all look similar and can only be differentiated using tools such as the microscope or electrophysiology.

## Watch this Video:



One or more interactive elements has been excluded from this version of the text. You can view them online here: <https://louis.pressbooks.pub/medicalterminology/?p=1248#oembed-1>

Media 5.1 [The Nervous System, Part 1: Crash Course A&P #8](#) [Online video]. Copyright 2015 by [CrashCourse](#).

# ANATOMY OF THE NERVOUS SYSTEM

---

## The Central and Peripheral Nervous Systems

The nervous system can be divided into two major regions: the central and peripheral nervous systems. The central nervous system (CNS) is the brain and spinal cord, and the peripheral nervous system (PNS) is everything else (see [Figure 5.1](#)). The brain is contained within the cranial cavity of the skull, and the spinal cord is contained within the vertebral cavity of the vertebral column. The peripheral nervous system is so named because it is on the periphery—meaning beyond the brain and spinal cord.

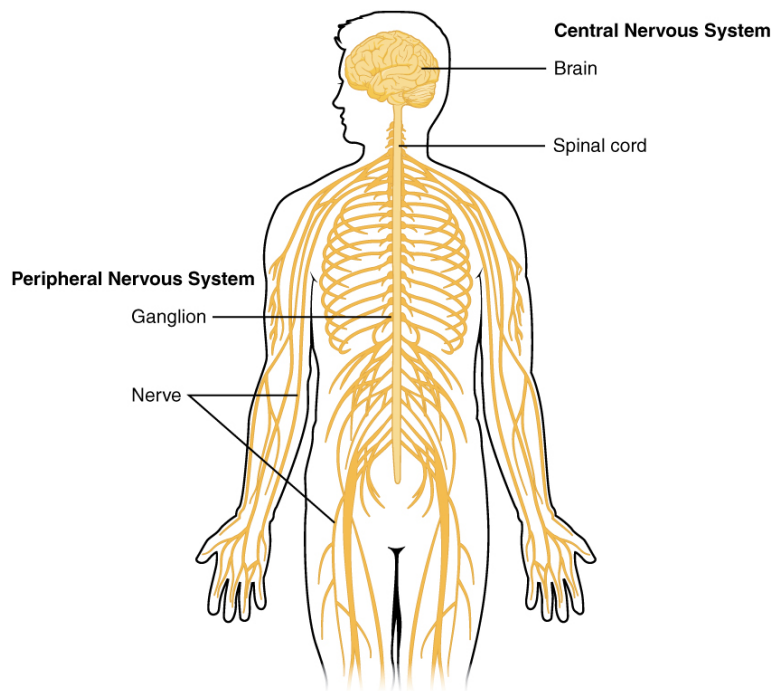


Figure 5.1 Central and Peripheral Nervous System. The structures of the PNS are referred to as ganglia and nerves, which can be seen as distinct structures. The equivalent structures in the CNS are not obvious from this overall perspective and are best examined in prepared tissue under the microscope. From Betts, et al., 2013. Licensed under [CC BY 4.0](#). [[Image description.](#)]

Nervous tissue, present in both the CNS and PNS, contains two basic types of cells: neurons and glial cells. Neurons are the primary type of cell that most anyone associates with the nervous system. They are electrically

active and release chemical signals to target cells. A glial cell is one of a variety of cells that provide a framework of tissue that supports the neurons and their activities.

Neurons are cells and therefore have a soma, or cell body, but they also have extensions of the cell; each extension is generally referred to as a process. There is one important process that every neuron has called an axon, which is the fiber that connects a neuron with its target. Another type of process that branches off from the soma is the dendrite. Dendrites are responsible for receiving most of the input from other neurons.

Looking at nervous tissue, there are regions that predominantly contain cell bodies and regions that are largely composed of just axons. These two regions within nervous system structures are often referred to as gray matter (the regions with many cell bodies and dendrites) or white matter (the regions with many axons). [Figure 5.2](#) demonstrates the appearance of these regions in the brain and spinal cord.

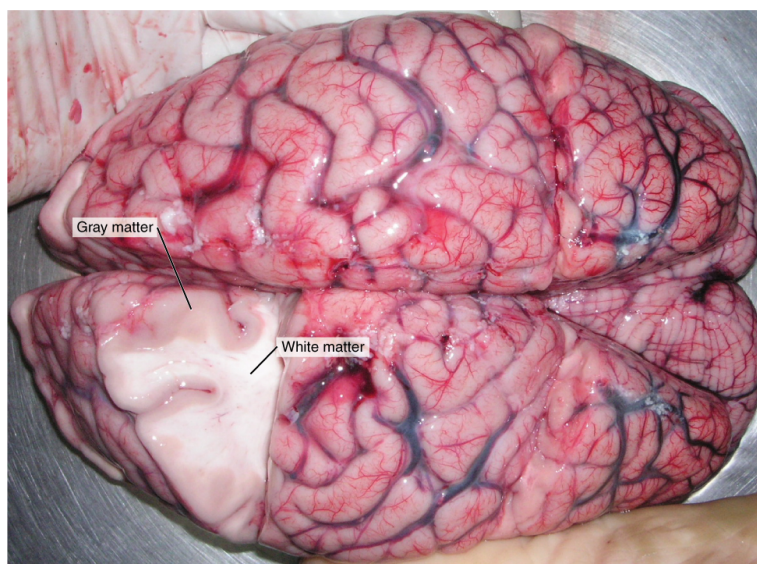


Figure 5.2 Gray Matter and White Matter. A brain removed during an autopsy, with a partial section removed, shows white matter surrounded by gray matter. Gray matter makes up the outer cortex of the brain. (Credit: modification of work by “Suseno”/Wikimedia Commons.) From Betts, et al., 2013. Licensed under [CC BY 4.0](#). [\[Image description.\]](#)

## The Adult Brain

The adult brain is separated into four major regions: the cerebrum, the diencephalon, the brain stem, and the cerebellum.

## The Cerebrum

The iconic gray mantle of the human brain, which appears to make up most of the mass of the brain, is the cerebrum (see [Figure 5.3](#)). The wrinkled portion is the cerebral cortex, and the rest of the structure is beneath that outer covering. There is a large separation between the two sides of the cerebrum called the longitudinal fissure. It separates the cerebrum into two distinct halves, a right and left cerebral hemisphere. Deep within the cerebrum, the white matter of the corpus callosum provides the major pathway for communication between the two hemispheres of the cerebral cortex.

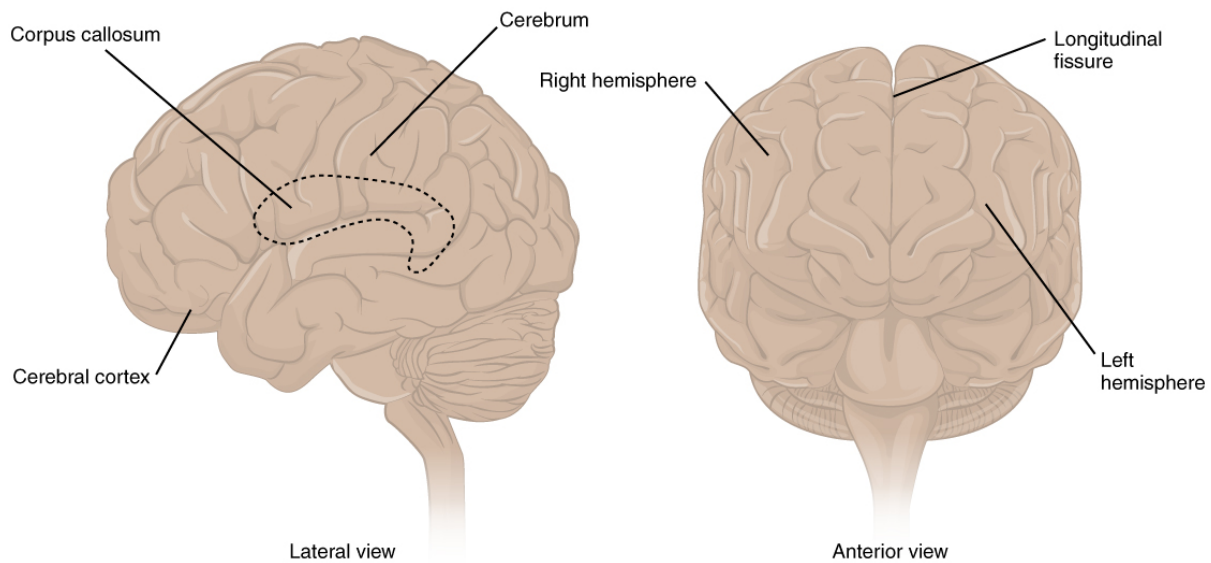


Figure 5.3 The Cerebrum. The cerebrum is a large component of the CNS in humans, and the most obvious aspect of it is the folded surface called the cerebral cortex. From Betts, et al., 2013. Licensed under [CC BY 4.0](#). [[Image description.](#)]

Many of the higher neurological functions, such as memory, emotion, and consciousness, are the result of cerebral function. In mammals, the cerebrum comprises the outer gray matter that is the cortex (from the Latin word meaning “bark of a tree”).

## Cerebral Cortex

The cerebrum is covered by a continuous layer of gray matter that wraps around either side of the forebrain—the cerebral cortex. This thin, extensive region of wrinkled gray matter is responsible for the higher functions of the nervous system. A gyrus (plural = gyri) is the ridge of one of those wrinkles, and a sulcus (plural = sulci) is the groove between two gyri. The pattern of these folds of tissue indicates specific regions of the cerebral cortex.

Extensive folding in the cerebral cortex enables more gray matter to fit into this limited space. If the gray matter of the cortex were peeled off of the cerebrum and laid out flat, its surface area would be roughly equal to one square meter.

Using these landmarks (the largest gyri and sulci), the cortex can be separated into four major regions, or lobes (see [Figure 5.4](#)).

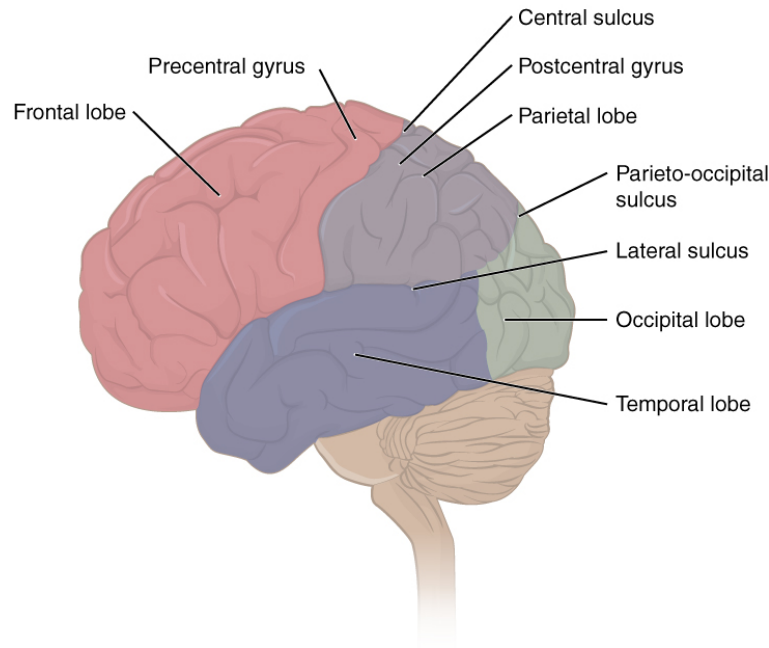


Figure 5.4 Lobes of the Cerebral Cortex. The cerebral cortex is divided into four lobes. Extensive folding increases the surface area available for cerebral functions. From Betts, et al., 2013. Licensed under [CC BY 4.0](#). [\[Image description\]](#)

## The Diencephalon

The diencephalon is deep beneath the cerebrum and constitutes the walls of the third ventricle. The two major regions of the diencephalon are the thalamus itself and the hypothalamus (see [Figure 5.5](#)).

### Thalamus

The thalamus is a collection of nuclei that relay information between the cerebral cortex and the periphery, spinal cord, or brain stem. All sensory information, except for the sense of smell, passes through the thalamus before being processed by the cortex.

## Hypothalamus

Inferior and slightly anterior to the thalamus is the hypothalamus, the other major region of the diencephalon. The hypothalamus is a collection of nuclei that are largely involved in regulating homeostasis. The hypothalamus is the executive region in charge of the autonomic nervous system and the endocrine system through its regulation of the anterior pituitary gland. Other parts of the hypothalamus are involved in memory and emotion as part of the limbic system.

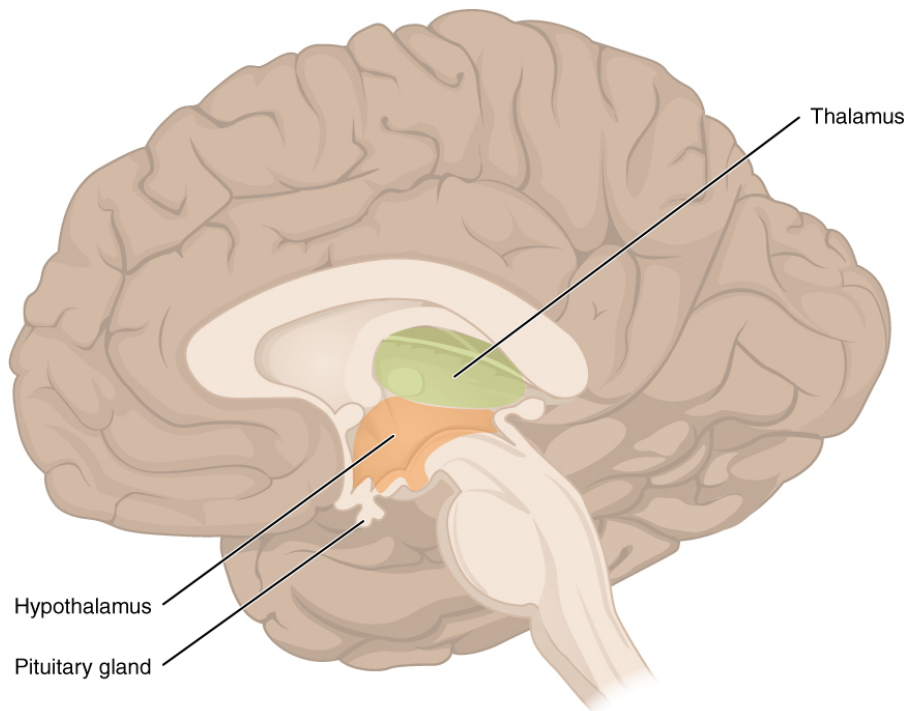


Figure 5.5 The Diencephalon. The diencephalon is composed primarily of the thalamus and hypothalamus, which together define the walls of the third ventricle. The thalami are two elongated, ovoid structures on either side of the midline that make contact in the middle. The hypothalamus is inferior and anterior to the thalamus, culminating in a sharp angle to which the pituitary gland is attached. From Betts, et al., 2013. Licensed under [CC BY 4.0](https://creativecommons.org/licenses/by/4.0/). [\[Image description.\]](#)

The midbrain and hindbrain (composed of the pons and the medulla) are collectively referred to as the brain stem (see [Figure 5.6](#)). The structure emerges from the ventral surface of the forebrain as a tapering cone that connects the brain to the spinal cord. The midbrain coordinates sensory representations of the visual, auditory, and somatosensory perceptual spaces. The pons is the main connection with the cerebellum. The pons and the medulla regulate several crucial functions, including the cardiovascular and respiratory systems and rates. The major ascending and descending pathways between the spinal cord and brain, specifically the cerebrum, pass through the brain stem.

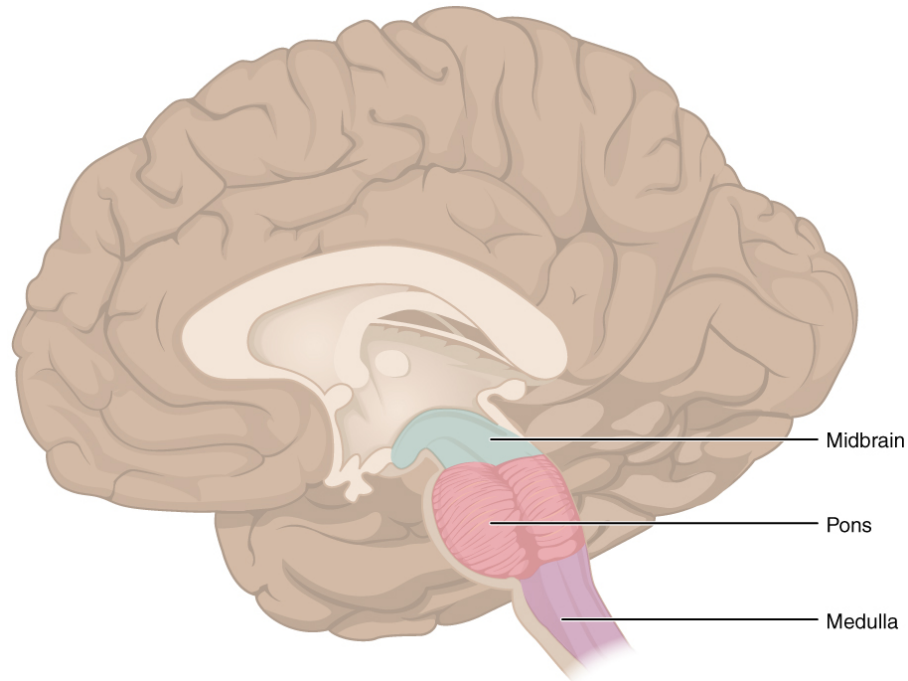


Figure 5.6 The Brain Stem. The brain stem comprises three regions: the midbrain, the pons, and the medulla. From Betts, et al., 2013. Licensed under [CC BY 4.0](https://creativecommons.org/licenses/by/4.0/). [\[Image description.\]](#)

## The Cerebellum

The cerebellum, as the name suggests, is the “little brain.” It is covered in gyri and sulci like the cerebrum and looks like a miniature version of that part of the brain (see [Figure 5.7](#)). The cerebellum is largely responsible for comparing information from the cerebrum with sensory feedback from the periphery through the spinal cord. It accounts for approximately 10 percent of the mass of the brain.

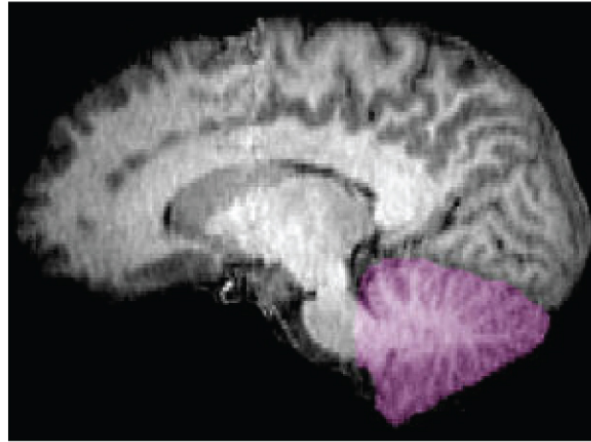
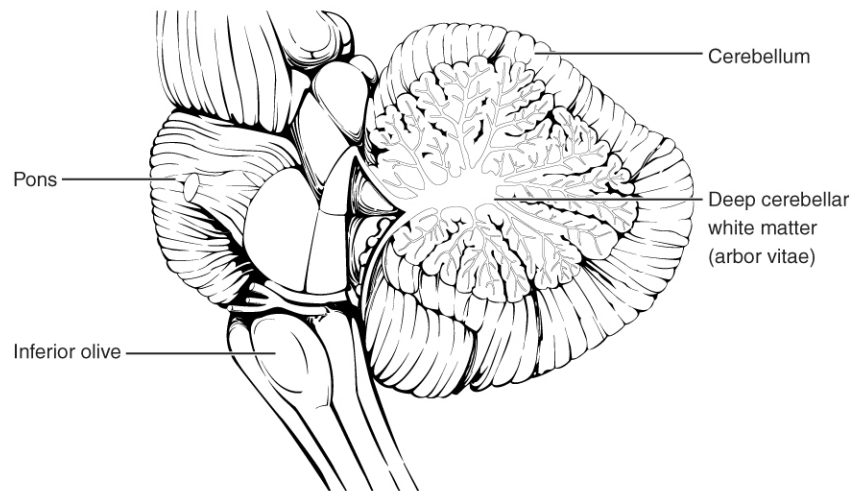


Figure 5.7 The Cerebellum. The cerebellum is situated on the posterior surface of the brain stem. Descending input from the cerebellum enters through the large white matter structure of the pons. Ascending input from the periphery and spinal cord enters through the fibers of the inferior olive. Output goes to the midbrain, which sends a descending signal to the spinal cord. From Betts, et al., 2013. Licensed under [CC BY 4.0](https://creativecommons.org/licenses/by/4.0/). [\[Image description.\]](#)

## The Spinal Cord

The description of the CNS is concentrated on the structures of the brain, but the spinal cord is another major organ of the system.

The length of the spinal cord is divided into regions that correspond to the regions of the vertebral column.

The name of a spinal cord region corresponds to the level at which spinal nerves pass through the intervertebral foramina. Immediately adjacent to the brain stem are the following divisions of the spinal cord:

- cervical region
- thoracic region
- lumbar region
- sacral region

The spinal cord is not the full length of the vertebral column because the spinal cord does not grow significantly longer after the first or second year, but the skeleton continues to grow. The nerves that emerge from the spinal cord pass through the intervertebral foramina at the respective levels. As the vertebral column grows, these nerves grow with it and result in a long bundle of nerves that resembles a horse's tail and is named the cauda equina. The sacral spinal cord is at the level of the upper lumbar vertebral bones. The spinal nerves extend from their various levels to the proper level of the vertebral column.

## Neurons

Neurons are the cells considered to be the basis of nervous tissue. They are responsible for the electrical signals that communicate information about sensations and that produce movements in response to those stimuli, along with inducing thought processes within the brain.

## Parts of a Neuron

As you learned in the first section, the main part of a neuron is the cell body, which is also known as the soma (soma = “body”). The cell body contains the nucleus and most of the major organelles. But what makes neurons special is that they have many extensions of their cell membranes, which are generally referred to as processes. Neurons are usually described as having one, and only one, axon—a fiber that emerges from the cell body and projects to target cells. That single axon can branch repeatedly to communicate with many target cells. It is the axon that propagates the nerve impulse, which is communicated to one or more cells. The other processes of the neuron are dendrites, which receive information from other neurons at specialized areas of contact called synapses. The dendrites are usually highly branched processes, providing locations for other neurons to communicate with the cell body. Information flows through a neuron from the dendrites, across the cell body, and down the axon.

[Figure 5.8](#) shows the relationship of these parts to one another.

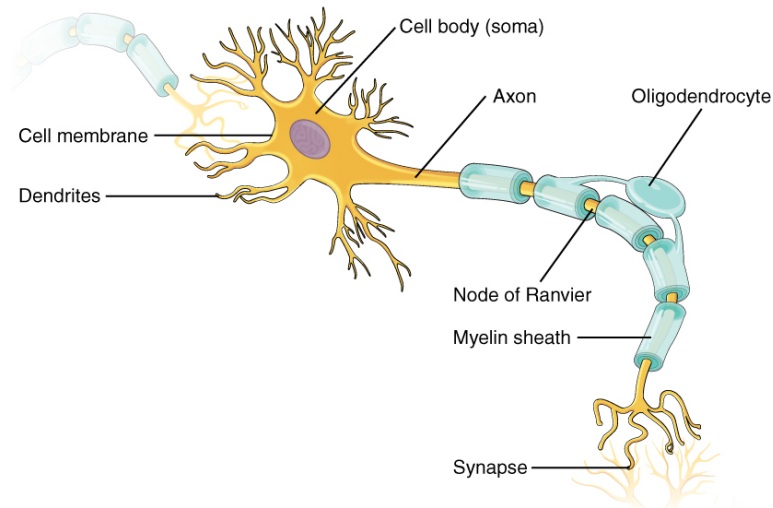


Figure 5.8 Parts of a Neuron. The major parts of the neuron are labeled on a multipolar neuron from the CNS. From Betts, et al., 2013. Licensed under [CC BY 4.0](https://creativecommons.org/licenses/by/4.0/). [\[Image description.\]](#)

Many axons are wrapped by an insulating substance called myelin, which is actually made from glial cells. Myelin acts as insulation, much like the plastic or rubber that is used to insulate electrical wires. A key difference between myelin and the insulation on a wire is that there are gaps in the myelin covering of an axon. Each gap is called a node of Ranvier and is important to the way that electrical signals travel down the axon. At the end of the axon is the axon terminal, where there are usually several branches extending toward the target cell, each of which ends in an enlargement called a synaptic end bulb. These bulbs are what make the connection with the target cell at the synapse.

## Glial Cells

Glial cells, or neuroglia or simply glia, are the other type of cell found in nervous tissue. They are considered to be supporting cells, and many functions are directed at helping neurons complete their function for communication. The name glia comes from the Greek word that means “glue.”

There are six types of glial cells. Four of them are found in the CNS, and two are found in the PNS. [Table 5.1](#) outlines some common characteristics and functions.

## Table 5.1: Glial Cell Types by Location and Basic Function

CNS GLIA	PNS GLIA	BASIC FUNCTION
Astrocyte	Satellite cell	Support
Oligodendrocyte	Schwann cell	Insulation, myelination
Microglia	–	Immune surveillance and phagocytosis
Ependymal cell	–	Creating CSF

From Betts, et al., 2013. Licensed under CC BY 4.0.

## Image Descriptions

**Figure 5.1 image description:** This diagram shows a silhouette of a human highlighting the nervous system. The central nervous system is composed of the brain and spinal cord. The brain is a large mass of ridged and striated tissue within the head. The spinal cord extends down from the brain and travels through the torso, ending in the pelvis. Pairs of enlarged nervous tissue, labeled ganglia, flank the spinal cord as it travels through the rib area. The ganglia are part of the peripheral nervous system, along with the many thread-like nerves that radiate from the spinal cord and ganglia through the arms, abdomen, and legs. [\[Return to Figure 5.1\].](#)

**Figure 5.2 image description:** This photo shows an enlarged view of the dorsal side of a human brain. The right side of the occipital lobe has been shaved to reveal the white and gray matter beneath the surface blood vessels. The white matter branches through the shaved section like the limbs of a tree. The gray matter branches and curves on the outside of the white matter, creating a buffer between the outer edges of the occipital lobe and the internal white matter. [\[Return to Figure 5.2\].](#)

**Figure 5.3 image description:** This figure shows the lateral view on the left panel and anterior view on the right panel of the brain. The major parts including the cerebrum are labeled. Lateral view labels (clockwise from top) read: cerebrum, cerebral cortex, corpus callosum (located on the interior of the brain). Anterior view labels indicate the right and left hemispheres and the longitudinal fissure between them. [\[Return to Figure 5.3\].](#)

**Figure 5.4 image description:** This figure shows the lateral view of the brain and the major lobes are labeled. From the front of the brain (left) labels read: frontal lobe, precentral gyrus, central sulcus, postcentral gyrus, parietal lobe, lateral sulcus, occipital lobe, temporal lobe. [\[Return to Figure 5.4\].](#)

**Figure 5.5 image description:** This figure shows the location of the thalamus, hypothalamus, and pituitary gland in the brain. Each part is labeled respectively. The thalamus is located in the midsection of the

brain. The hypothalamus is located below the thalamus and the pituitary gland below that. [\[Return to Figure 5.5\]](#).

**Figure 5.6 image description:** This figure shows the location of the midbrain, pons, and the medulla in the brain that make up the brain stem. The midbrain is located at the top, the pons is located beneath that, and the medulla is the lowest most point of the brain stem. [\[Return to Figure 5.6\]](#).

**Figure 5.7 image description:** This figure shows the location of the cerebellum in the brain which is located on the posterior surface of the brain stem. Labels read (top, left): pons, inferior olive, (top, right) cerebellum, deep cerebellar white matter (arbor vitae). In the top panel, a lateral view labels the location of the cerebellum and the deep cerebellar white matter. In the bottom panel, a photograph of a brain, with the cerebellum in pink is shown. [\[Return to Figure 5.7\]](#).

**Figure 5.8 image description:** This illustration shows the anatomy of a neuron. The neuron has a very irregular cell body (soma) containing a purple nucleus. There are six projections protruding from the top, bottom, and left side of the cell body. Each of the projections branches many times, forming small, tree-shaped structures protruding from the cell body. The right side of the cell body tapers into a long cord called the axon. The axon is insulated by segments of myelin sheath, which resemble a semitransparent toilet paper roll wound around the axon. The myelin sheath is not continuous but is separated into equally spaced segments. The bare axon segments between the sheath segments are called nodes of Ranvier. An oligodendrocyte is reaching its two arm-like projections onto two myelin sheath segments. The axon branches many times at its end, where it connects to the dendrites of another neuron. Each connection between an axon branch and a dendrite is called a synapse. The cell membrane completely surrounds the cell body, dendrites, and its axon. The axon of another nerve is seen in the upper left of the diagram connecting with the dendrites of the central neuron. [\[Return to Figure 5.8\]](#).

# WORD PARTS AND STRUCTURAL TERMS

---

## Combining Forms

**arachn/o:** spider

**astr/o:** star

**cephal/o:** head

**cerebell/o:** cerebellum

**cerebr/o:** cerebrum

**cortic/o:** outer layer or covering

**crani/o:** cranium, head

**dur/o:** dura mater, hard

**encephal/o:** brain

**esthesi/o:** sensation, sensitivity, feeling

**gangli/o:** ganglion

**ganglion/o:** ganglion

**gli/o:** glia, gluey substance

**heme/o:** blood

**hydr/o:** water

**mening/o:** meninges

**meningi/o:** meninges

**ment/o:** mind

**mon/o:** one, single

**myel/o:** spinal cord

**neur/o:** nerve

**pariet/o:** wall

**phas/o:** speech

**poli/o:** gray matter

**psych/o:** mind

**quadr/i:** four

**radic/o:** nerve root

**radicul/o:** nerve root

**rhiz/o:** nerve root

**somat/o:** body

**thromb/o:** clot

## Prefixes

**a-:** absence of, without, no, not

**an-:** absence of, without, no, not

**dys-:** painful, abnormal, difficult, labored

**hemi-:** half

**hyper-:** above, excessive

**hypo-:** below, deficient

**inter-:** between

**intra-:** within

**pan-:** all, total

**para-:** beside, beyond, around, abnormal

**poly-:** many, much

**post-:** after

**pre-:** before

**sub-:** below, under

**syn-:** together

## Suffixes

**-al:** pertaining to (adjective)

**-algia:** pain (noun)

**-cele:** hernia, protrusion (noun)

**-cyte:** cell (noun)

**-ectomy:** excision, surgical removal, cutting out (noun)

**-genic:** producing, originating, causing (adjective)

**-gram:** the record, radiographic image (noun)

**-graph:** instrument used to record (noun)

**-graphy:** process of recording, radiographic imaging (noun)

**-ia:** condition of, diseased state or abnormal state (adjective)

**-ic:** pertaining to (adjective)

**-iatrist:** specialist, physician (noun)

**-atry:** specialty, treatment (noun)

**-ictal:** seizure, attack

- itis**: inflammation
- logist**: specialist, physician
- logy**: study of
- lysis**: loosening, dissolution, separating
- malacia**: softening
- oid**: resembling
- oma**: tumor
- osis**: abnormal condition
- paresis**: slight paralysis
- pathy**: disease
- peri**: around or about
- phasia**: speech
- plasty**: surgical repair
- plegia**: paralysis
- rrhaphy**: suture
- sclerosis**: hardening
- rrhaphy**: suturing, repairing
- tomy**: incision, cut into

## Structural Terms Built from Word Parts

- arachnoid**: resembling a spider
- astrocyte**: star-shaped cell; a type of glial cell
- cephalgia**: pain in the head
- cephalic**: pertaining to the head
- cerebellar**: pertaining to the cerebellum
- cerebral**: pertaining to the cerebrum
- cortical**: pertaining to the gray matter of the cerebrum
- cranial**: pertaining to the cranium or skull cap
- craniocerebral**: pertaining to the cranium and cerebrum
- dendrite**: tree-like structure; receptive process of the neuron
- diencephalon**: thalamus and hypothalamus
- ganglial**: pertaining to a localized collection of neuron cell bodies
- glial**: pertaining to neuroglia
- gliocyte**: glial cell
- hypothalamic**: pertaining to the hypothalamus

**hypothalamus:** structure below the thalamus; part of the diencephalon

**intracerebral:** pertaining to within the cerebrum

**medulla oblongata:** innermost, oblong-shaped part of the brain stem

**meningeal:** pertaining to the membranes protecting the brain

**mental:** pertaining to the brain

**microglia:** small neuroglial cell

**myelin:** a fatty sheath around an axon of some neurons

**neuroglia:** “nerve glue”; supportive cells of nerve tissue

**neuroid:** resembling a nerve

**parietal:** pertaining to the wall

**parietal lobe:** one of the cerebral lobes; named for the cranial bone it is situated beneath

**peripheral:** pertaining to around the center

**peripheral nervous system:** the division of the nervous system outside of the central nervous system

**psychogenic:** originating in the mind

**somatic:** pertaining to the body

**somatic nervous system:** pertaining to peripheral nervous system sections that carry impulses to the skeletal muscles

**subarachnoid space:** space under the middle layer of the meninges where cerebrospinal fluid flows

# DISEASES AND DISORDERS

---

## Disease and Disorder Terms Built from Word Parts

**amnesia:** without memory; a sudden loss of memory

**amyotrophic lateral sclerosis:** hardening and breakdown of neurons supplying skeletal muscles causing muscle wasting

**aphasia:** condition of without speaking; inability to speak

**astrocytoma:** tumor of the star-shaped glial cells; can be in the brain or spinal cord

**cephalgia:** pain in the head

**cerebellitis:** inflammation of the cerebellum

**cerebral thrombosis:** abnormal condition of blood clotting in the brain

**cerebrovascular accident:** a clot or bleeding in the vessels of the brain; a stroke

**dementia:** impairment in thinking; can affect memory, personality, reasoning, and processing

**duritis:** inflammation of the dura mater

**dysphasia:** difficult speech; impaired ability to speak

**encephalitis:** inflammation of the brain

**encephalomalacia:** softening of the brain

**encephalomyeloradiculitis:** inflammation of the brain, spinal cord, and nerve roots

**encephalosclerosis:** hardening of the brain tissue

**epidural hematoma:** collection of blood between the skull and the dura mater

**gangliitis:** inflammation of the ganglion

**glioblastoma:** tumor of developing glial tissue

**glioma:** tumor of the glial tissue

**hemiparesis:** partial paralysis of one side of the body

**hemiplegia:** paralysis of one side of the body

**hydrocephalus:** “water on the brain”; excessive cerebrospinal fluid in and around the brain

**hyperesthesia:** excessive sensitivity to stimuli

**ictal:** pertaining to between seizures

**interictal:** pertaining to during a seizure

**meningioma:** noncancerous tumor of the meninges

**meningitis:** inflammation of the meninges

**meningomyelocele:** protrusion of the meninges and spinal cord

**microcephaly:** small head; congenital condition where the brain and skull are too small

**monoparesis:** mild paralysis of one (limb)

**mononeuropathy:** disease affecting a single nerve

**multiple sclerosis:** disease of plaques (hardened areas) in the brain and demyelination

**myelitis:** inflammation of the spinal cord

**myelomalacia:** softening of the spinal cord

**myelomeningocele:** protrusion (herniation) of the membranes of the brain or spinal cord through a hole in the skull or vertebrae

**neuralgia:** pain in a nerve

**neuritis:** inflammation of the nerves

**neuroarthropathy:** disease of the nerves and joints

**neuroma:** tumor of nerve tissue

**neuropathy:** disease of nerve fibers

**panplegia:** total paralysis

**paralysis:** destruction of nerves in the spinal cord; loss of muscle functions

**paraplegia:** paralysis of the lower extremities and often the lower body trunk

**paresthesia:** loss of sensation, numbness

**plegia:** paralysis

**polyneuritis:** inflammation of many nerves

**polyneuropathy:** disease of many nerves

**poliomyelitis:** inflammation of the gray matter in the spinal cord and brain

**preictal:** occurs before a seizure or attack

**psychopathy:** disease of the mind

**psychosis:** abnormal condition of the mind

**psychosomatic:** pertaining to the mind and body

**psychotic disorder:** a disorder pertaining to the mind

**quadriplegia:** paralysis of four limbs; can also include the trunk

**radicotomy:** incision into a nerve root

**radiculitis:** inflammation of the nerve roots

**radiculopathy:** disease of the nerve roots

**ryizomeningomyelitis:** inflammation of the nerve root, meninges, and spinal cord

**subarachnoid hemorrhage:** bleeding into the area between the arachnoid mater and the pia mater

**subdural hematoma:** blood-filled tumor pertaining to below the dura mater

## Disease and Disorder Terms Not Built from Word Parts

**Alzheimer's disease:** a dementia disorder caused by plaques and degeneration of the myelin in the central nervous system

**Guillain-Barre syndrome:** disease causing demyelination of the peripheral nerves

**Parkinson's disease:** central nervous system disease causing dopamine deficiency

# MEDICAL, SURGICAL, & VIEWING TERMS AND ABBREVIATIONS

---

## Medical Careers & Professional Terminology

**neurologist:** specialist in the prevention, diagnosis, and treatment of disorders of the nervous system

**neurology:** study of nerves

**neurosurgeon:** surgeon who specializes in operations on the nervous system

**psychiatrist:** medical doctor who specializes in the diagnosis and treatment of mental disorders

**psychiatry:** specialty of the mind

**psychologist:** nonmedical doctor who specializes in the diagnosis and treatment of mental disorders

## Imaging Techniques/Diagnostic Procedures/ Procedures for the Organ System

**cerebral angiography:** process of recording vessels in the cerebrum

**CT myelography:** process of recording the spinal cord with computed tomography

**electroencephalogram:** the record of electrical activity of the brain

**electromyography:** test that measures the electrical activity between the brain and spinal cord and the peripheral nerves innervating the skeletal muscles

**lumbar puncture:** procedure used to test cerebrospinal fluid

**myelography:** radiography of the spinal cord and nerve roots

**tensilon test:** test used to diagnose myasthenia gravis

## Surgical Techniques/Procedures Used in the Organ System

**craniotomy:** removal of part of the skull to relieve pressure in the brain tissue

**ganglionectomy:** excision of a ganglion

**lobotomy:** incision into a lobe of the brain

**neurectomy:** excision of the nerves

**neurotomy:** incision into a nerve

**neurolysis:** dissolution of nerve (for pain management)

**neuroplasty:** surgery to repair a nerve

**neurorrhaphy:** suturing of a nerve

**rhizotomy:** incision into a nerve root

## Abbreviations Commonly Used with the Organ System

**AD:** Alzheimer's disease

**ADHD:** attention deficit hyperactivity disorder

**ALS:** amyotrophic lateral sclerosis

**CNS:** central nervous system

**CP:** cerebral palsy

**CSF:** cerebrospinal fluid

**CTE:** chronic traumatic encephalopathy

**CVA:** cerebrovascular accident

**EEG:** electroencephalogram

**EMG:** electromyography

**EP studies:** evoked potential studies

**LP:** lumbar puncture

**MRI:** magnetic resonance imaging

**MS:** multiple sclerosis

**OCD:** obsessive-compulsive disorder

**PD:** Parkinson's disease

**PET:** positron emission tomography

**PNS:** peripheral nervous system

**PTSD:** post-traumatic stress disorder

**SAH:** subarachnoid hemorrhage

**TIA:** transient ischemic attack

## Medical Terms Practice

For each card, click the speaker icon to hear the correct pronunciation of the listed term. Practice saying the

term to yourself, then attempt to define the term from memory. Click “Turn” to flip the card and see the definition. Use the right and left arrows to toggle through the cards in each set.



*An interactive H5P element has been excluded from this version of the text. You can view it online here:*

<https://louis.pressbooks.pub/medicalterminology/?p=1258#h5p-109>

# PRACTICE

---

The following activities will allow you to practice what you've learned in this chapter.

## Anatomy Labeling Activity

Click and drag each term to the box corresponding with the anatomic structure, body part, body plane, or body region for that term.



*An interactive H5P element has been excluded from this version of the text. You can view it online here:*

<https://louis.pressbooks.pub/medicalterminology/?p=2038#h5p-110>

## History and Physical Examination

Click and drag each term from the word bank to its correct place in this exercise.



*An interactive H5P element has been excluded from this version of the text. You can view it online here:*

<https://louis.pressbooks.pub/medicalterminology/?p=2038#h5p-112>

## Consultation Report

Click and drag each term from the word bank to its correct place in this exercise.



*An interactive H5P element has been excluded from this version of the text. You can view it online here:*

<https://louis.pressbooks.pub/medicalterminology/?p=2038#h5p-113>

## Follow-Up Report

Click and drag each term from the word bank to its correct place in this exercise.



*An interactive H5P element has been excluded from this version of the text. You can view it online here:*

<https://louis.pressbooks.pub/medicalterminology/?p=2038#h5p-114>

## Vocabulary Reinforcement Activity

Click the term that correctly answers each question or completes each sentence.



*An interactive H5P element has been excluded from this version of the text. You can view it online here:*

<https://louis.pressbooks.pub/medicalterminology/?p=2038#h5p-115>

# REFERENCES

---

- Bergen, T. (2018). [Tensilon test](https://www.healthline.com/health/tensilon-test). Healthline. <https://www.healthline.com/health/tensilon-test>
- Canadian Cancer Society. (2020). [Lumbar puncture](https://www.cancer.ca/en/cancer-information/diagnosis-and-treatment/tests-and-procedures/lumbar-puncture/?region=on). <https://www.cancer.ca/en/cancer-information/diagnosis-and-treatment/tests-and-procedures/lumbar-puncture/?region=on>
- Centers for Disease Control and Prevention. (2018). [Mental health](https://www.cdc.gov/mentalhealth/learn/index.htm). CDC. <https://www.cdc.gov/mentalhealth/learn/index.htm>
- Centers for Disease Control and Prevention. (2019). [TBI: Get the facts](https://www.cdc.gov/conjunctivitis/about/causes.html). CDC. <https://www.cdc.gov/conjunctivitis/about/causes.html>
- Centers for Disease Control and Prevention. (2020). [Cerebral palsy \(CP\)](https://www.cdc.gov/conjunctivitis/about/causes.html). CDC. <https://www.cdc.gov/conjunctivitis/about/causes.html>
- Cherney, K. & De Pietro, M. (2019). [Neurologist](https://www.healthline.com/find-care/articles/neurologists/neurologist). Healthline. <https://www.healthline.com/find-care/articles/neurologists/neurologist>
- [CrashCourse]. (2015, February 23). [The nervous system, part 1: Crash course A&P #8](https://www.youtube.com/watch?v=qPix_X-9t7E) [Video]. YouTube. [https://www.youtube.com/watch?v=qPix\\_X-9t7E](https://www.youtube.com/watch?v=qPix_X-9t7E)
- Merriam-Webster. (n.d.). [Neurologist](https://www.merriam-webster.com/dictionary/neurologist). In *Merriam-Webster.com dictionary*. <https://www.merriam-webster.com/dictionary/neurologist>
- Moore, D., & Cirino, E. (2018). [Electromyography \(EMG\)](https://www.healthline.com/health/electromyography). Healthline. <https://www.healthline.com/health/electromyography>
- Ontario Federation for Cerebral Palsy. (2018). [About cerebral palsy](https://www.ofcp.ca/about-cerebral-palsy). <https://www.ofcp.ca/about-cerebral-palsy>
- Taylor, G. (2019, June 3). [Brain injury awareness month—June 2019](https://www.canada.ca/en/public-health/news/2019/05/brain-injury-awareness-month-june-2019.html). Public Health Agency of Canada. <https://www.canada.ca/en/public-health/news/2019/05/brain-injury-awareness-month-june-2019.html>

Unless otherwise indicated, this chapter contains material adapted from [Building a Medical Terminology Foundation](#), by Kimberlee Carter and Marie Rutherford and is used under a [CC BY 4.0 international license](#), which itself contained material adapted from [Anatomy and Physiology](#) (on OpenStax), by Betts, et al. and is used under a [CC BY 4.0 international license](#).

## PART VI

# ENDOCRINE SYSTEM

### Learning Objectives

When completing this chapter, the learner will be able to do the following:

- Identify the anatomy of the endocrine system
- Describe the main functions of the endocrine system
- Spell the medical terms of the endocrine system and use correct abbreviations
- Pronounce the medical terms of the endocrine system and use correct abbreviations
- Identify the medical specialties associated with the endocrine system
- Explore common diseases, disorders, and procedures related to the endocrine system

## Introduction

You may never have thought of it this way, but when you send a text message to two friends to meet you at the dining hall at six, you're sending digital signals that (you hope) will affect their behavior—even though they are some distance away. Similarly, certain cells send chemical signals to other cells in the body that influence their behavior. This long-distance intercellular communication, coordination, and control is critical to maintain equilibrium (homeostasis). This intercellular activity is the fundamental function of the endocrine system.

## Watch This Video:



One or more interactive elements has been excluded from this version of the text. You can view them online here: <https://louis.pressbooks.pub/medicalterminology/?p=1403#oembed-1>

Media 6.1. [Endocrine System, Part 1—Glands & Hormones: Crash Course A&P #23](#) [Online video].  
Copyright 2015 by [CrashCourse](#).

# BASIC ANATOMY & PHYSIOLOGY OF THE ENDOCRINE SYSTEM

The endocrine system is composed of endocrine glands distributed throughout the body. These glands are pituitary, thyroid, parathyroid, adrenal, pineal, pancreas, gonads (ovaries and testes), and thymus ([Figure 6.1](#)).

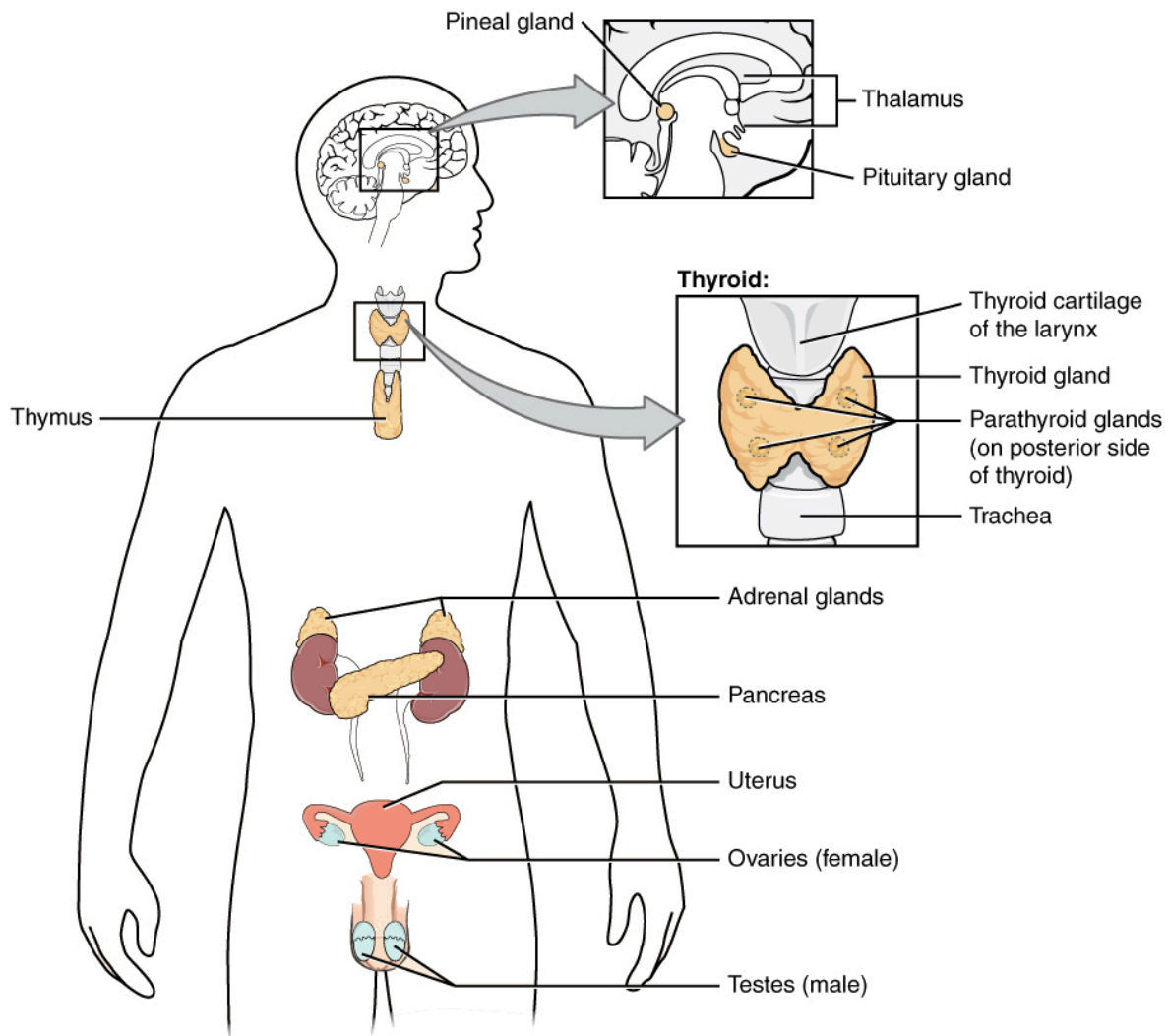


Figure 6.1 Endocrine System. Endocrine glands and cells are located throughout the body and play an important role in maintaining equilibrium (homeostasis). From Betts, et al., 2013. Licensed under CC BY 4.0. [\[Image description.\]](#)

The endocrine system consists of cells, tissues, and organs that secrete hormones as a primary or secondary

function. The primary function of the **endocrine glands** is to secrete **hormones** into the bloodstream. Hormones are chemical messengers that will influence metabolic activities, growth, and development. Some glands have both endocrine and nonendocrine functions. For example, the pancreas contains cells that function in digestion as well as cells that secrete the endocrine hormones like insulin and glucagon, which regulate blood glucose levels. The hypothalamus, thymus, heart, kidneys, stomach, small intestine, liver, skin, female ovaries, and male testes are other organs that contain cells with endocrine function. Moreover, fat (adipose) tissue has long been known to produce hormones, and recent research has revealed that even bone tissue has endocrine functions. The ductless endocrine glands are not to be confused with the body's **exocrine system**, whose glands release their secretions through ducts. Examples of exocrine glands include the sebaceous and sweat glands of the skin. As just noted, the pancreas also has an exocrine function: most of its cells secrete pancreatic juice through the pancreatic and accessory ducts to the lumen of the small intestine.

## Endocrine Signaling

The **endocrine system** uses one method of communication called chemical signaling. These chemical signals are sent by the endocrine organs. The endocrine organs secrete chemicals—called hormones—into the fluid outside of the tissue cells (extracellular fluid). Hormones are then transported primarily via the bloodstream throughout the body, where they bind to receptors on target cells, creating a particular response. For example, the hormones released when you are presented with a dangerous or a frightening situation, called the fight-or-flight response, occur through the release of hormones from the adrenal gland—epinephrine and norepinephrine—within seconds. In contrast, it may take up to 48 hours for target cells to respond to certain reproductive hormones.

In addition, endocrine signaling is typically less specific than neural (nerve) signaling. The same hormone may also play a role in a variety of different physiological processes depending on the target cells involved. For example, the hormone oxytocin generates uterine contractions in women who are in labor. This hormone is also important in generating the milk-release reflex during breastfeeding and may be involved in the sexual response and in feelings of emotional attachment in both males and females.

Generally, the nervous system involves quick responses to rapid changes in the external environment, and the endocrine system is usually slower acting—taking care of the internal environment of the body, maintaining equilibrium (homeostasis), and controlling reproduction (see [Table 6.1](#)). So how does the fight-or-flight response, mentioned earlier, happen so quickly if hormones are usually slower acting? It is because the two systems are connected. It is the fast action of the nervous system in response to the danger in the environment that stimulates the adrenal glands to secrete their hormones, epinephrine and norepinephrine. As a result, the nervous system can cause rapid endocrine responses to keep up with sudden changes in both the external and internal environments when necessary.

## Table 6.1: Endocrine and Nervous Systems

<b>Characteristic</b>	<b>Endocrine System</b>	<b>Nervous System</b>
Signaling mechanism(s)	Chemical	Chemical/electrical
Primary chemical signal	Hormones	Neurotransmitters
Distance traveled	Long or short	Always short
Response time	Fast or slow	Always fast
Environment targeted	Internal	Internal and external

From Betts, et al., 2013. Licensed under CC BY 4.0.

**Table 6.2: Endocrine Glands and Their Major Hormones**

<b>Endocrine Gland</b>	<b>Associated Hormones</b>	<b>Chemical Class</b>	<b>Effect</b>
Pituitary (anterior)	Growth hormone (GH)	Protein	Promotes growth of body tissues
Pituitary (anterior)	Prolactin (PRL)	Peptide	Promotes milk production
Pituitary (anterior)	Thyroid-stimulating hormone (TSH)	Glycoprotein	Stimulates thyroid hormone release
Pituitary (anterior)	Adrenocorticotropic hormone (ACTH)	Peptide	Stimulates hormone release by adrenal cortex
Pituitary (anterior)	Follicle-stimulating hormone (FSH)	Glycoprotein	Stimulates gamete production
Pituitary (anterior)	Luteinizing hormone (LH)	Glycoprotein	Stimulates androgen production by gonads
Pituitary (posterior)	Antidiuretic hormone (ADH)	Peptide	Stimulates water reabsorption by kidneys
Pituitary (posterior)	Oxytocin	Peptide	Stimulates uterine contractions during childbirth
Thyroid	Thyroxine (T <sub>4</sub> ), triiodothyronine (T <sub>3</sub> )	Amine	Stimulate basal metabolic rate
Thyroid	Calcitonin	Peptide	Reduces blood Ca <sup>2+</sup> levels
Parathyroid	Parathyroid hormone (PTH)	Peptide	Increases blood Ca <sup>2+</sup> levels
Adrenal (cortex)	Aldosterone	Steroid	Increases blood Na <sup>+</sup> levels
Adrenal (cortex)	Cortisol, corticosterone, cortisone	Steroid	Increases blood glucose levels
Adrenal (medulla)	Epinephrine, norepinephrine	Amine	Stimulates fight-or-flight response
Pineal	Melatonin	Amine	Regulates sleep cycles
Pancreas	Insulin	Protein	Reduces blood glucose levels
Pancreas	Glucagon	Protein	Increases blood glucose levels
Testes	Testosterone	Steroid	Stimulates development of male secondary sex characteristics and sperm production
Ovaries	Estrogens and progesterone	Steroid	Stimulates development of female secondary sex characteristics and prepares the body for childbirth

From Betts, et al., 2013. Licensed under CC BY 4.0.

## Hormone Receptors

The message a hormone sends is received by a hormone **receptor**, a protein located either inside the cell or within the cell membrane. The receptor will process the message by initiating other signaling events or cellular mechanisms that result in the target cell's response. Hormone receptors recognize molecules with specific shapes and side groups and respond only to those hormones that are recognized. The same type of receptor may be located on cells in different body tissues and trigger somewhat different responses. Thus, the response triggered by a hormone depends not only on the hormone but also on the target cell.

## Image Descriptions

**Figure 6.1 image description:** This diagram shows the endocrine glands and cells that are located throughout the body. The endocrine system organs include the pineal gland and pituitary gland in the brain. The pituitary is located on the anterior side of the thalamus, while the pineal gland is located on the posterior side of the thalamus. The thyroid gland is a butterfly-shaped gland that wraps around the trachea within the neck. Four small, disc-shaped parathyroid glands are embedded into the posterior side of the thyroid. The adrenal glands are located on top of the kidneys. The pancreas is located at the center of the abdomen. In females, the two ovaries are connected to the uterus by two long, curved tubes in the pelvic region. In males, the two testes are located in the scrotum below the penis. [\[Return to Figure 6.1\]](#).

# WORD PARTS AND STRUCTURAL TERMS

---

## Combining Forms

**acr/o:** extremities, height

**aden/o:** gland

**adren/o:** adrenal glands

**adrenal/o:** adrenal glands

**calc/i:** calcium

**cortic/o:** cortex, outer layer of a body organ

**dips/o:** thirst

**glyc/o:** sugar

**endocrin/o:** endocrine

**kal/i:** potassium

**natr/o:** sodium

**parathyroid/o:** parathyroid gland

**pituitar/o:** pituitary gland

**thyr/o:** thyroid gland

**thyroid/o:** thyroid gland

## Prefixes

**eu-:** normal, good

**hypo-:** below, under, deficient

**hyper-:** above, excessive

**para-:** around, beside, beyond, abnormal

**poly-:** many, much

**syn-:** joined, together

**pan-:** all, total

## Suffixes

- al**: pertaining to
- drome**: run, running together
- ectomy**: excision, cut out
- emia**: in the blood
- ia**: condition of, abnormal state, diseased state
- ism**: state of
- itis**: inflammation
- logist**: specialist or physician who studies and treats
- logy**: study of
- megaly**: enlarged, enlargement
- oid**: resembling
- oma**: tumor
- pathy**: disease
- plasia**: condition of, formation, development, growth
- tomy**: incision, cut into

## Structural Terms Built from Word Parts

**pituitary gland**: approximately the size of a pea and located at the base of the brain. The pituitary is divided into two lobes. It is often referred to as the master gland because it produces hormones that stimulate the function of other endocrine glands.

**hypothalamus**: located superior to the pituitary gland in the brain. The hypothalamus secretes “releasing” hormones that function to stimulate or inhibit the release of pituitary gland hormones.

**thyroid gland**: largest endocrine gland. It is located anteriorly in the neck below the larynx and comprises bilateral lobes connected by an isthmus. The thyroid gland secretes the hormones triiodothyronine (T<sub>3</sub>) and thyroxine (T<sub>4</sub>), which require iodine for their production. Thyroxine is necessary for body cell metabolism.

**parathyroid glands**: four small bodies embedded in the posterior aspect of the lobes of the thyroid gland. Parathyroid hormone (PTH), the hormone produced by the glands, helps maintain the level of calcium in the blood by its effects on bone and kidneys.

**islets of Langerhans**: clusters of endocrine tissue found throughout the pancreas, made up of different cell types that secrete various hormones, including insulin and glucagon. Nonendocrine cells found throughout the pancreas produce enzymes that facilitate digestion.

**adrenal glands**: paired glands, one of which is located superior to each kidney. The outer portion is called the adrenal cortex, and the inner portion is called the adrenal medulla.

# DISEASES AND DISORDERS

---

## Disease and Disorder Terms Built from Word Parts

**acromegaly:** enlargement of the extremities (and face due to increased soft tissue, bone, and cartilage; caused by excessive production of the growth hormone by the pituitary gland after puberty)

**adrenitis:** inflammation of the adrenal glands

**adrenomegaly:** enlargement (of one or both) of the adrenal glands

**endocrinopathy:** any disease of the endocrine system

**hypercalcemia:** excessive calcium in the blood

**hyperglycemia:** excessive sugar in the blood

**hyperkalemia:** excessive potassium in the blood

**hyperparathyroidism:** state of excessive parathyroid gland activity (resulting in hypercalcemia and leading to osteoporosis, as well as symptoms of muscle weakness, abdominal pain, nausea, vomiting, and drowsiness)

**hyperpituitarism:** state of excessive pituitary gland activity (characterized by excessive secretion of pituitary hormones)

**hyperthyroidism:** state of excessive thyroid gland activity (characterized by excessive secretion of thyroid hormones; signs and symptoms include tachycardia, weight loss, irritability, and heat intolerance)

**hypocalcemia:** deficient calcium in the blood

**hypoglycemia:** deficient sugar in the blood

**hypokalemia:** deficient potassium in the blood

**hyponatremia:** deficient sodium in the blood

**hypopituitarism:** state of deficient pituitary gland activity (characterized by decreased secretion of one or more of the pituitary hormones, which can affect the function of the target endocrine gland; for example, hypothyroidism can result from decreased secretion of thyroid-stimulating hormone by the pituitary gland)

**hypothyroidism:** state of deficient thyroid gland activity (characterized by decreased secretion of thyroid hormones; signs and symptoms include fatigue, weight gain, and cold intolerance)

HYPOTHYROIDISM results in decreased production of the thyroid hormone called thyroxine. A severe form of hypothyroidism in adults is called myxedema and in infants is called congenital hypothyroidism.

**panhypopituitarism:** state of total deficient pituitary gland activity (characterized by decreased secretion of all the anterior pituitary hormones; a more serious condition than hypopituitarism in that it affects the function of all the other endocrine glands)

PANHYPOPITUITARISM contains two prefixes: pan-meaning total and hypo-meaning deficient.

**parathyroidoma:** tumor of a parathyroid gland

**thyroiditis:** inflammation of the thyroid gland

## Disease and Disorder Terms Not Built from Word Parts

**Addison disease:** chronic syndrome resulting from a deficiency in the hormonal secretion of the adrenal cortex. Signs and symptoms may include weakness, weight loss, hypotension, darkening of skin, and loss of appetite.

ADDISON DISEASE was named in 1855 for Thomas Addison, an English physician and pathologist. He described the disease as a “morbid state with feeble heart action, anemia, irritability of the stomach, and a peculiar change in the color of the skin.”

**congenital hypothyroidism:** condition caused by congenital absence or atrophy (wasting away) of the thyroid gland, resulting in hypothyroidism. The disease is characterized by puffy features, mental deficiency, large tongue, and short stature.

**Cushing syndrome:** group of signs and symptoms attributed to the excessive production of cortisol by the adrenal cortices (pl. of cortex). This syndrome may be the result of a pituitary tumor that produces ACTH or a primary adrenal cortex hypersecretion. Signs include abnormally pigmented skin, “moon face,” pads of fat on the chest and abdomen, “buffalo hump” (fat on the upper back), wasting away of muscle, and hypertension.

CUSHING SYNDROME was named for an American neurosurgeon, Harvey Williams Cushing (1869–1939), after he described adrenocortical hyperfunction.

**diabetes insipidus (DI):** result of decreased secretion of antidiuretic hormone by the posterior lobe of the pituitary gland. Symptoms include excessive thirst (polydipsia), large amounts of urine (polyuria), and water being excreted from the body.

**diabetes mellitus (DM):** chronic disease involving a disorder of carbohydrate metabolism caused by underactivity of the insulin-producing islets of Langerhans and characterized by elevated blood sugar (hyperglycemia). DM can cause chronic renal disease, retinopathy, and neuropathy. In extreme cases the patient may develop ketosis, acidosis, and finally coma.

**gigantism:** condition brought about by hypersecretion of growth hormone by the pituitary gland before puberty

GIGANTISM AND ACROMEGALY are both caused by overproduction of growth hormone. Gigantism occurs before puberty and before the growing ends of the bones have closed. If untreated, an individual may reach 8 feet tall in adulthood. Acromegaly occurs after puberty. The body parts most affected are those in the hands, feet, and jaw.

**graves disease:** autoimmune disorder of the thyroid gland characterized by the production of more thyroid hormone than the body needs (hyperthyroidism), goiter, and exophthalmos (abnormal protrusion of the eyeballs)

**Hashimoto thyroiditis:** disease in which thyroid gland cells are destroyed by autoimmune processes. Characterized by hypothyroidism and goiter; more common in females.

**ketoacidosis:** serious condition resulting from uncontrolled diabetes mellitus in which acid ketones accumulate from fat metabolism in the absence of adequate insulin. If not promptly controlled by adequate insulin and hydration, can progress to coma and death.

**metabolic syndrome:** group of signs and symptoms including insulin resistance, obesity characterized by excessive fat around the area of the waist and abdomen, hypertension, hyperglycemia, elevated triglycerides, and low levels of the “good” cholesterol HDL. Risks include development of type 2 diabetes mellitus, coronary heart disease, or stroke (also called syndrome X and insulin resistance syndrome).

**myxedema:** condition resulting from an extreme deficiency of the thyroid hormone thyroxine; a severe form of hypothyroidism in an adult. Signs include puffiness of the face and hands, coarse and thickened skin, enlarged tongue, slow speech, and anemia.

**neuroblastoma:** malignant cancer that often starts in the adrenal medulla, composed of immature nerve cells. Primarily affects children.

**pheochromocytoma:** tumor of the adrenal medulla, which is usually nonmalignant and characterized by hypertension, headaches, palpitations, diaphoresis, chest pain, and abdominal pain. Surgical removal of the tumor is the most common treatment. Though usually curable with early detection, it can be fatal if untreated.

**thyrotoxicosis:** condition caused by excessive thyroid hormones

## Watch this video:



One or more interactive elements has been excluded from this version of the text. You can view them online here: <https://louis.pressbooks.pub/medicalterminology/?p=1755#oembed-1>

Media 6.2 [Endocrine System, part 2—Hormone Cascades](#) [Online video]. Copyright 2015 by [CrashCourse](#).

# MEDICAL, SURGICAL, & VIEWING TERMS AND ABBREVIATIONS

---

## Medical Careers & Professional Terminology

**endocrinology:** a specialization in the field of medicine that focuses on the treatment of endocrine system disorders.

**endocrinologist:** medical doctors who specialize in this field are experts in treating diseases associated with hormonal systems, ranging from thyroid disease to diabetes.

**endocrine surgeons:** treat endocrine disease through the removal of the affected endocrine gland or tissue.

Some patients experience health problems as a result of the normal decline in hormones that can accompany aging. These patients can consult with an endocrinologist to weigh the risks and benefits of hormone replacement therapy intended to boost their natural levels of reproductive hormones. In addition to treating patients, endocrinologists may be involved in research to improve the understanding of endocrine system disorders and develop new treatments for these diseases (Betts, et al., 2013).

**thyroid specialist:** an endocrinologist whose subspecialty is focused on the treatment and disorders of the thyroid gland such as hypothyroidism (too low secretion) and hyperthyroidism (too high secretion).

**diabetes specialist:** an endocrinologist whose subspecialty is focused on the treatment of diabetic conditions.

## Imaging Techniques/Procedures for the Organ System

**thyroid scan:** This procedure is designed to check the status of the thyroid. In a thyroid scan, a radioactive compound is given and localized in the thyroid gland (Giorgi & Cherney, 2018).

**radioactive iodine uptake:** Thyroid function evaluated by injecting radioactive iodine and then measuring how much is removed from the blood by the thyroid (MedlinePlus, 2020).

**blood serum testing:** Blood testing to determine the concentration and the presence of various endocrine hormones in the blood. These tests include the following levels: calcium, cortisol, electrolytes, FSH, GH, glucose, insulin, parathyroid hormones, T3, T4, testosterone, and TSH. All of these can be evaluated with blood serum tests (Betts, et al., 2013).

## Surgical Techniques/Procedures Used in the Organ System

Most of the surgeries and procedures performed on the endocrine system involve removal of a gland or an incision into the gland. Once an endocrine gland is surgically removed, due to a tumor or enlargement, hormone replacement treatment is required. Medication is required to artificially or synthetically replace the hormone produced by the gland and the function it regulates (Betts, et al., 2013).

## Abbreviations Commonly Used with the Organ System

**ACTH:** adrenocorticotrophic hormone

**ADH:** antidiuretic hormone

**DI:** diabetes insipidus

**DKA:** diabetic ketoacidosis

**DM:** diabetes mellitus

**FBS:** fasting blood sugar

**FNA:** fine needle aspiration

**FSH:** follicle-stimulating hormone

**GH:** growth hormone

**HbA1C:** glycosylated hemoglobin

**LH:** luteinizing hormone

**PRL:** prolactin

**RAIU:** radioactive iodine uptake

**TSH:** thyroid-stimulating hormone

**Thyroid profile:** T<sub>4</sub>, T<sub>3</sub>, and TSH

**T<sub>4</sub>:** thyroxine level

**T<sub>3</sub>:** triiodothyronine level

**TSH:** thyroid-stimulating hormone

## Medical Terms Practice

For each card, click the speaker icon to hear the correct pronunciation of the listed term. Practice saying the

term to yourself, then attempt to define the term from memory. Click “Turn” to flip the card and see the definition. Use the right and left arrows to toggle through the cards in each set.



*An interactive H5P element has been excluded from this version of the text. You can view it online here:*

<https://louis.pressbooks.pub/medicalterminology/?p=1758#h5p-117>

# PRACTICE

---

The following activities will allow you to practice what you've learned in this chapter.

## Endocrine System Labeling Activity

Click and drag each term from the word bank to its correct place in this exercise.



*An interactive H5P element has been excluded from this version of the text. You can view it online here:*

<https://louis.pressbooks.pub/medicalterminology/?p=2041#h5p-118>

## Vocabulary Reinforcement Activity

Click the term that correctly answers each question or completes each sentence.



*An interactive H5P element has been excluded from this version of the text. You can view it online here:*

<https://louis.pressbooks.pub/medicalterminology/?p=2041#h5p-122>

# REFERENCES

---

Giorgi, A., & Cherney, K. (2018). [Thyroid scan](https://www.healthline.com/health/thyroid-scan). Healthline. <https://www.healthline.com/health/thyroid-scan>  
MedlinePlus. (2020). [Radioactive iodine uptake](https://medlineplus.gov/ency/article/003689.htm). US National Library of Medicine. <https://medlineplus.gov/ency/article/003689.htm>

Media 6.1 [CrashCourse]. (2015, June 22). [Endocrine system, part 1—glands & hormones: Crash course A&P #23](https://www.youtube.com/watch?v=eWHH9je2zG4) [Video]. YouTube. <https://www.youtube.com/watch?v=eWHH9je2zG4>

Media 6.2 [CrashCourse]. (2015, June 29). [Endocrine system, part 2—hormone cascade: Crash course A&P #24](https://www.youtube.com/watch?v=SCV_m91mN-Q) [Video]. YouTube. [https://www.youtube.com/watch?v=SCV\\_m91mN-Q](https://www.youtube.com/watch?v=SCV_m91mN-Q)

Unless otherwise indicated, this chapter contains material adapted from [Building a Medical Terminology Foundation](#), by Kimberlee Carter and Marie Rutherford and is used under a [CC BY 4.0 international license](#), which itself contained material adapted from [Anatomy and Physiology](#) (on OpenStax), by Betts, et al. and is used under a [CC BY 4.0 international license](#).



## PART VII

# INTEGUMENTARY SYSTEM

## Learning Objectives

When completing this chapter, the learner will be able to do the following:

- Identify the basic anatomy of the integumentary system
- Describe the main functions of the integumentary system
- Spell the integumentary system medical terms and use correct abbreviations
- Identify the medical specialties associated with the integumentary system
- Explore common diseases, disorders, and procedures related to the integumentary system

## Introduction

The integumentary system refers to the skin and its accessory structures. In the adult human body, the skin makes up about 16 percent of body weight and covers an area of 1.5 to 2 m<sup>2</sup>. In fact, the skin and accessory structures are the largest organ systems in the human body. The skin protects your inner organs and it is in need of daily care and protection to maintain its health.

## Watch this video:



One or more interactive elements has been excluded from this version of the text. You can view them online here: <https://louis.pressbooks.pub/medicalterminology/?p=1303#oembed-1>

Media 5.1 [The Integumentary System, Part 1—Skin Deep: Crash Course A&P #6](#) [Online video].  
Copyright 2015 by [CrashCourse](#).

# ANATOMY OF THE INTEGUMENTARY SYSTEM

---

## Basic Anatomy of the System

The skin and its accessory structures make up the **integumentary system**, which provides the body with overall protection. The skin is made of multiple layers of cells and tissues, which are held to underlying structures by connective tissue ([Figure 7.1](#)). The deeper layer of skin is well **vascularized**. It also has numerous sensory and **autonomic** nerve fibers ensuring communication to and from the brain.

The skin is composed of two main layers:

1. The **epidermis**
2. The **dermis**
  - Beneath the dermis lies the **hypodermis** (subcutaneous).

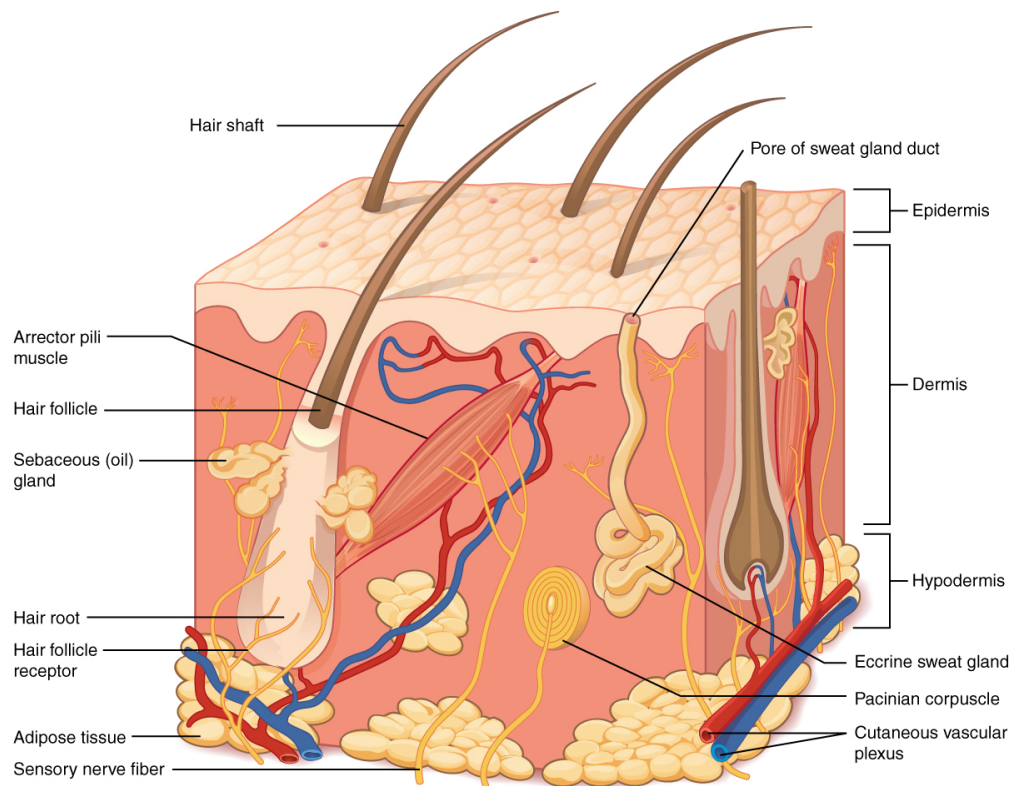


Figure 7.1 Layers of Skin. From Betts, et al., 2013. Licensed under [CC BY 4.0](https://creativecommons.org/licenses/by/4.0/).  
[\[Image description.\]](#)

## Epidermis

The outer layer, the epidermis, is composed of **keratinized**, stratified squamous epithelium. It is made of four or five layers of epithelial cells, depending on its location in the body. It is avascular.

## Dermis

The dermis contains blood and lymph vessels, nerves, and other structures, such as **hair follicles** and **sweat glands**. The dermis is made of two layers (papillary layer and reticular layer) of connective tissue that compose an interconnected mesh of elastin and collagenous fibers, produced by fibroblasts.

## Hypodermis

The **hypodermis** serves to connect the skin to the underlying **fascia** of the bones and muscles. It is not strictly a part of the skin, although the border between the **hypodermis** and **dermis** can be difficult to

distinguish. The hypodermis consists of well-vascularized, loose, areolar connective tissue and adipose tissue, which functions as a mode of fat storage and provides insulation and cushioning for the integument.

## Image Descriptions

**Figure 7.1 image description:** This illustration shows a cross section of skin tissue. The outermost layer is called the epidermis and occupies one-fifth of the cross section. Several hairs are emerging from the surface. The epidermis dives around one of the hairs, forming a follicle. The middle layer is called the dermis, which occupies four-fifths of the cross section. The dermis contains an erector pili muscle connected to one of the follicles. The dermis also contains an eccrine sweat gland, composed of a bunch of tubules. One tubule travels up from the bunch, through the epidermis, opening onto the surface a pore. There are two string-like nerves traveling vertically through the dermis. The right nerve is attached to a Pacinian corpuscle, a yellow structure consisting of concentric ovals similar to an onion. The lowest level of the skin, the hypodermis, contains fatty tissue, arteries, and veins. Blood vessels travel from the hypodermis and connect to hair follicles and erector pili muscle in the dermis. [\[Return to Figure 7.1\]](#).

# PHYSIOLOGY OF THE INTEGUMENTARY SYSTEM

---

## Basic Physiology of the System

### Protection

The skin protects the body from wind, water, and UV sunlight. It acts as a protective barrier against water loss, and it also is the first line of defense against abrasive activity such as grit, microbes, or harmful chemicals. Sweat excreted from sweat glands deters microbes from over-colonizing the skin surface by generating dermcidin, which has antibiotic properties.

### Sensory Function

The skin acts as a sense organ because the epidermis, dermis, and the hypodermis contain specialized sensory nerve structures that detect touch, surface temperature, and pain. These receptors are more concentrated on the tips of the fingers, which are most sensitive to touch, especially the **Meissner corpuscle** (tactile corpuscle), which responds to light touch, and the **Pacinian corpuscle** (lamellar corpuscle), which responds to vibration.

### Thermoregulation

The integumentary system helps regulate body temperature through its tight association with the **sympathetic nervous system**. The sympathetic nervous system is continuously monitoring body temperature and initiating appropriate responses.

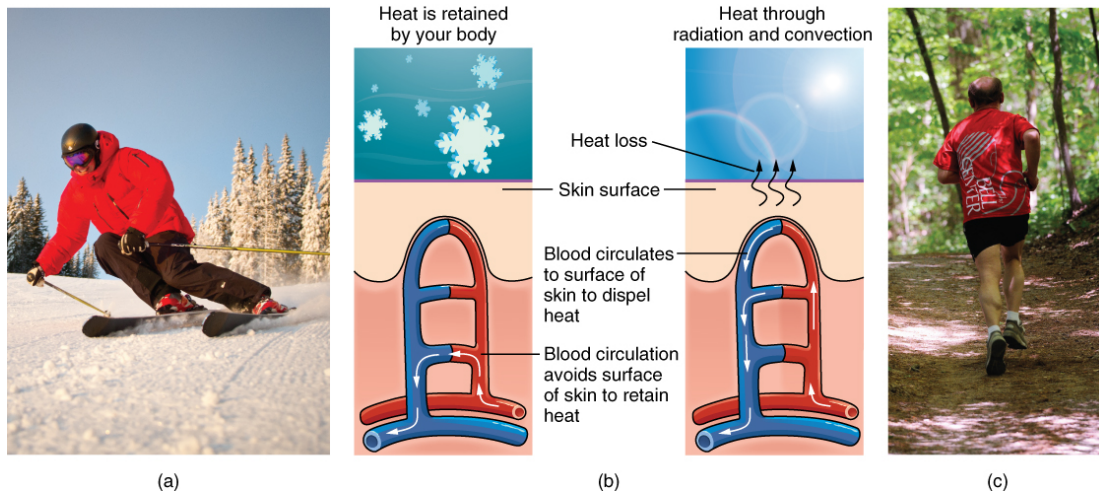


Figure 7.2 Thermoregulation. During strenuous physical activities, such as skiing (a) or running (c), the dermal blood vessels dilate and sweat secretion increases (b). These mechanisms prevent the body from overheating. In contrast, the dermal blood vessels constrict to minimize heat loss in response to low temperatures (b). (Credit a: “Trysil”/flickr; credit c: Ralph Daily.) From Betts, et al., 2013. Licensed under [CC BY 4.0](https://creativecommons.org/licenses/by/4.0/). [\[Image description.\]](#)

## Vitamin D Synthesis

The epidermal layer of human skin synthesizes vitamin D when exposed to UV radiation. In the presence of sunlight, a form of vitamin D<sub>3</sub> called cholecalciferol is synthesized from a derivative of the steroid cholesterol in the skin.

## Watch This Video:



One or more interactive elements has been excluded from this version of the text. You can view them online here: <https://louis.pressbooks.pub/medicalterminology/?p=1320#oembed-1>

Media 5.2 *The Integumentary System, Part 2—Skin Deeper: Crash Course A&P #7* [Online Video]  
 Copyright 2015 by [CrashCourse](https://www.cashcourse.com/).

## Accessory Structures

Accessory structures of the skin include hair, nails, sweat glands, and sebaceous glands. These structures embryologically originate from the epidermis and can extend down through the dermis into the **hypodermis**.

### Hair

Hair is a keratinous filament growing out of the **epidermis**. It is primarily made of dead, keratinized cells. Strands of hair originate in the **hair follicle**. The **hair shaft** is the part of the hair not anchored to the follicle, and much of this is exposed at the skin's surface. The rest of the hair lies below the surface of the skin and is referred to as the hair root. The **hair root** ends deep in the dermis at the hair bulb. The **hair bulb** surrounds the **hair papilla**, which is made of connective tissue and contains blood capillaries and nerve endings from the dermis (see [Figure 7.3](#)).

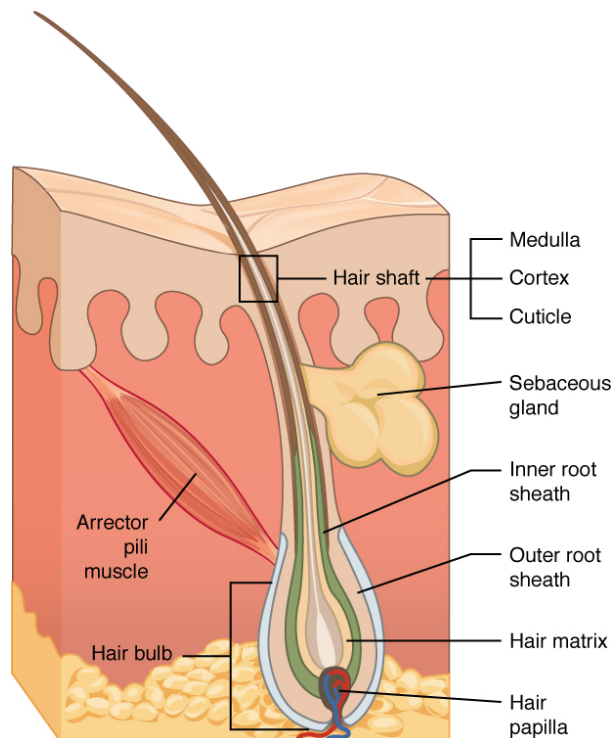


Figure 7.3 Hair. Hair follicles originate in the epidermis and have many different parts. From Betts, et al., 2013. Licensed under [CC BY 4.0](#). [\[Image description.\]](#)

## Nails

The **nail bed** is a specialized structure of the epidermis that is found at the tips of our fingers and toes. The **nail body** is composed of densely packed dead **keratinocytes**, forms on the nail bed, and protects the tips of our fingers and toes. The nail body forms at the **nail root**, which enables the nail to grow continuously. The **nail cuticle** is also called the **eponychium** (see [Figure 7.4](#)).

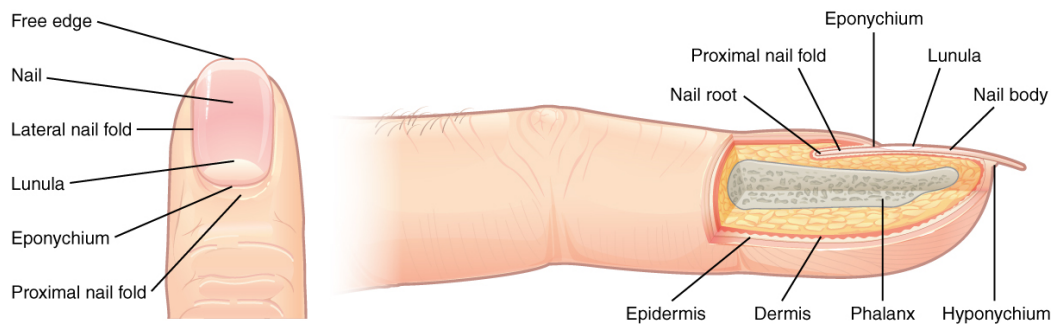


Figure 7.4 Nails. The nail is an accessory structure of the integumentary system. From Betts, et al., 2013. Licensed under [CC BY 4.0](#). [\[Image description.\]](#)

## Sudoriferous (Sweat) Glands

When the body becomes warm, sudoriferous glands produce sweat to cool the body. There are two types of sweat glands, each secreting slightly different products.

An **eccrine** sweat gland is a type of gland that produces a watery sweat for cooling the body. These glands have pores that are found all over the skin's surface ([Figure 7.5](#)). Eccrine glands are a primary component of thermoregulation in humans and thus help to maintain **homeostasis** (the internal balance of the body).

An **apocrine** sweat gland is usually associated with hair follicles in densely hairy areas, such as armpits and genital regions. Apocrine sweat glands are larger than eccrine sweat glands, with the duct normally emptying into the hair follicle. In addition to water and salts, apocrine sweat includes organic compounds that make the sweat thicker and subject to bacterial decomposition and subsequent smell.

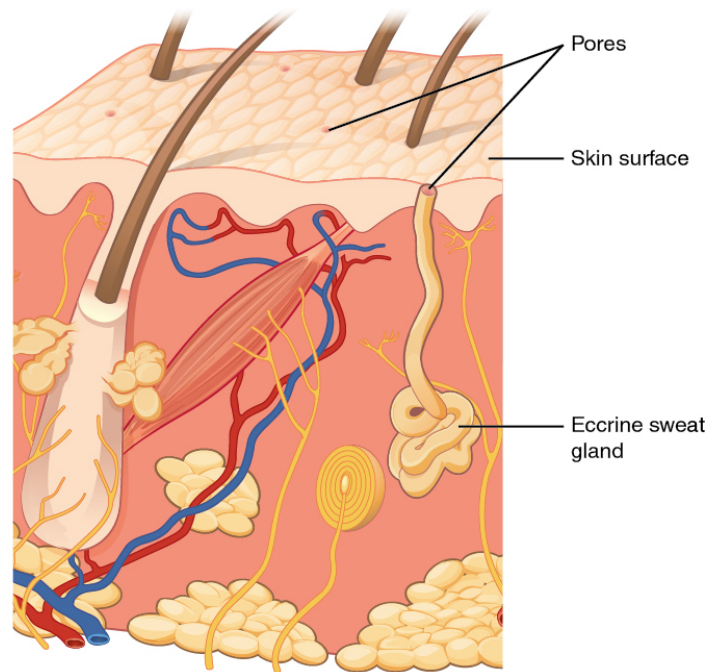


Figure 7.5 Eccrine Gland. Eccrine glands are coiled glands in the dermis that release sweat that is mostly water. From Betts, et al., 2013. Licensed under [CC BY 4.0](https://creativecommons.org/licenses/by/4.0/). [\[Image description.\]](#)

A **sebaceous** gland is a type of oil gland that is found all over the body and helps to lubricate and waterproof the skin and hair. Most sebaceous glands are associated with hair follicles. They generate and excrete **sebum**, a mixture of lipids (fats), onto the skin surface, thereby naturally lubricating the dry and dead layer of keratinized cells of the stratum corneum, keeping it pliable.

## Image Descriptions

**Figure 7.2 image description:** Part A is a photo of a man skiing with several snow-covered trees in the background. Part B is a diagram with a right and left half. The left half is titled “Heat is retained by the body,” while the right half is titled “Heat loss through radiation and convection.” Both show blood flowing from an artery through three capillary beds within the skin. The beds are arranged vertically, with the topmost bed located along the boundary of the dermis and epidermis. The bottommost bed is located deep in the hypodermis. The middle bed is evenly spaced between the topmost and bottommost beds. In each bed, oxygenated blood (red) enters the bed on the left and deoxygenated blood (blue) leaves the bed on the right. The left diagram shows a picture of snowflakes above the capillary beds, indicating that the weather is cold. Blood is only flowing through the deepest of the three capillary beds, as the upper beds are closed off to reduce heat loss from the outer layers of the skin. The right diagram shows a picture of the sun above the capillary

beds, indicating that the weather is hot. Blood is flowing through all three capillary beds, allowing heat to radiate out of the blood, increasing heat loss. Part C is a photo of a man running through a forested trail on a summer day. [\[Return to Figure 7.2\].](#)

**Figure 7.3 image description:** A cross section of the skin containing a hair follicle. The follicle is teardrop shaped. Its enlarged base, labeled the hair bulb, is embedded in the hypodermis. The outermost layer of the follicle is the epidermis, which invaginates from the skin surface to envelop the follicle. Within the epidermis is the outer root sheath, which is only present on the hair bulb. It does not extend up the shaft of the hair. Within the outer root sheath is the inner root sheath. The inner root sheath extends about half of the way up the hair shaft, ending midway through the dermis. The hair matrix is the innermost layer. The hair matrix surrounds the bottom of the hair shaft where it is embedded within the hair bulb. The hair shaft, in itself, contains three layers: the outermost cuticle, a middle layer called the cortex, and an innermost layer called the medulla. [\[Return to Figure 7.3\].](#)

**Figure 7.4 image description:** The anatomy of the fingernail region. The top image shows a dorsal view of a finger. The proximal nail fold is the part underneath where the skin of the finger connects with the edge of the nail. The eponychium is a thin, pink layer between the white proximal edge of the nail (the lunula), and the edge of the finger skin. The lunula appears as a crescent-shaped white area at the proximal edge of the pink-shaded nail. The lateral nail folds are where the sides of the nail contact the finger skin. The distal edge of the nail is white and is called the free edge. An arrow indicates that the nail grows distally out from the proximal nail fold. The lower image shows a lateral view of the nail bed anatomy. In this view, one can see how the edge of the nail is located just proximal to the nail fold. This end of the nail, from which the nail grows, is called the nail root. [\[Return to Figure 7.4\].](#)

**Figure 7.5 image description:** An illustration of an eccrine sweat gland embedded in a cross section of skin tissue. The eccrine sweat gland is a bundle of white tubes embedded in the dermis. A single white tube travels up from the bundle and opens onto the surface of the epidermis. The opening is called a pore. There are several pores on the small block of skin portrayed in this diagram. [\[Return to Figure 7.5\].](#)

# WORD PARTS AND STRUCTURAL TERMS

---

## Combining Forms

**adip/o:** fat

**albin/o:** white

**aut/o:** self

**bi/o:** life

**carcin/o:** cancer, malignant

**coni/o:** dust

**crypt/o:** hidden

**cutane/o:** skin

**cyan/o:** blue

**cyst/o:** fluid-filled sac

**cyt/o:** cell

**derm/o:** skin

**dermat/o:** skin

**erythr/o:** red

**heter/o:** other

**hidr/o:** sweat

**ichthy/o:** fishlike, dry, scaly

**kerat/o:** hard, horny tissue, keratin

**melan/o:** black

**myc/o:** fungus

**necr/o:** death

**onych/o:** nail

**pachy/o:** thick

**pil:** hair

**pruri/o:** itch

**reticul/o:** net

**rhytid/o:** wrinkles

**scler/o:** hard

**seb/o:** oil/sebum

**staphyl/o:** grapelike clusters

**strept/o**: twisted chains

**vascul/o**: blood vessel

**xanth/o, cirrh/o, jaund/o**: yellow

**xer/o**: dryness, dry

## Prefixes

**a-**: absence of

**bi-**: two or both

**cryo-**: cold

**dia-**: through, complete

**dys-**: difficult, painful, abnormal, labored

**epi-**: upon, on, over

**hyper-**: above, excessive

**hypo-**: deficient, below, under, incomplete

**intra-**: within, in

**meta-**: change, beyond, after

**neo-**: new

**para-**: beside, around, beyond, abnormal

**per-**: through

**pro-**: before

**sub-**: under, below

**trans-**: through, across, beyond

**uni-**: one

## Suffixes

**-a**: no meaning, noun ending

**-al**: pertaining to

**-ad**: toward

**-coccus**: berry-shaped

**-cyte**: cell

**-ectomy**: excision

**-gen**: substance that produces/causes, agent that produces/causes

**-genic**: producing, originating, causing

**-ia**: condition of, diseased state, abnormal state

- ic**: pertaining to
- itis**: inflammation
- ior**: pertaining to
- logy**: study of
- logist**: specialist who studies and treats
- malacia**: softening
- megaly**: enlarged, enlargement
- oid**: resembling
- oma**: tumor, swelling
- opsy**: view of, process of viewing, viewing
- osis**: abnormal condition, increased numbers relating to blood
- ous**: pertaining to
- pathy**: disease
- phagia**: eating, swallowing
- plasia**: development, growth, condition of formation
- plasm**: growth, substance, formation
- plasty**: surgical repair
- rrhea**: flow, discharge
- sis**: state of
- stasis**: stop, controlling, standing
- tome**: instrument used to cut

## Structural Terms Built from Word Parts

**adipocytes**: fat cells

**avascular**: pertaining to no blood vessels

**cutaneous**: pertaining to the skin

**dermal**: pertaining to the skin

**dermat**: skin

**dermatome**: area of skin supplied by a single spinal nerve

**epidermal**: pertaining to on top of the skin

**hypodermic**: pertaining to below the skin (interchangeable with subcutaneous)

**intra-dermal**: pertaining to within the skin

**keratinocytes**: cell producing a hard protein

**melanocyte**: melanin-producing cell

**percutaneous**: pertaining to through the skin

**phagocyte:** cell that eats

**reticular:** pertaining to being net-like

**sebaceous:** pertaining to sebum (oil) / oil producing

**subcutaneous:** pertaining to below the skin (interchangeable with hypodermic)

**subungual:** pertaining to under the nail

**transcutaneous:** pertaining to through or across the skin

**transdermal:** pertaining to through or across the skin

**ungual:** pertaining to the nail

**vascular:** pertaining to / having blood vessels

# MEDICAL, SURGICAL, & VIEWING TERMS AND ABBREVIATIONS

---

## Medical Careers & Professional Terminology

**aesthetician:** a medical specialist who performs only clinical skincare

**dermatologist:** physician who specializes in diagnosing and treating disorders of the skin

**dermatology:** the study of the skin and diseases affecting the skin

**dermatopathology:** the study of skin diseases

**esthetician:** a professional who performs manicures, pedicures, waxing, and other body/skin treatments

## Imaging Techniques/Treatments for the Organ System

**antibiotics:** medicines that kill bacteria

**antifungals:** medicines that kill fungi

**anti-inflammatories:** medicines that reduce swelling/edema

**antipruritics:** medicines that reduce itching

**antipyretics:** medicines that reduce fever

**antiseptic:** agents/chemicals that inhibit (prevent) bacterial growth

**keratogenic:** agent causing growth of horny tissue

**scabicides:** medicine that kills mites

## Surgical Techniques/Procedures Used for the Organ System

**biopsy:** view of life (process of removing tissue for study)

**cryosurgery:** cold surgery, used to freeze tissue for removal

**cryotherapy:** treatment of diseases using extreme cold

**debridement:** removal of dead tissue from a wound

**dermatoautoplasty:** surgical repair using one's own skin

**dermatoheteroplasty:** surgical repair using skin from others

**dermoplasty:** surgical repair of the skin

**onychectomy:** surgical removal of a fingernail or toenail

**onychotomy:** incision into a fingernail or toenail

**rhytidectomy:** excision (surgical removal) of wrinkles

**rhytidoplasty:** surgical repair of wrinkles

## Abbreviations Commonly Used with the Organ System

**BCC:** basal cell carcinoma

**bx:** biopsy

**derm:** dermatology

**ID:** intradermal

**MRSA:** methicillin-resistant *Staphylococcus aureus*

**SCC:** squamous cell carcinoma

**SLE:** systemic lupus erythematosus

**staph:** staphylococcus

**strep:** streptococcus

**subcut:** subcutaneous

**TD:** transdermal

## Medical Terms Practice

For each card, click the speaker icon to hear the correct pronunciation of the listed term. Practice saying the term to yourself, then attempt to define the term from memory. Click “Turn” to flip the card and see the definition. Use the right and left arrows to toggle through the cards in each set.



*An interactive H5P element has been excluded from this version of the text. You can view it online here:*

<https://louis.pressbooks.pub/medicalterminology/?p=1338#h5p-8>



*An interactive H5P element has been excluded from this version of the text. You can view it online here:*

<https://louis.pressbooks.pub/medicalterminology/?p=1338#h5p-10>

# DISEASES AND DISORDERS

---

## Disease and Disorder Terms Built from Word Parts

**albinism:** “condition of white”; a partial or complete lack of melanin-producing cells

**basal cell carcinoma:** a cancerous tumor of the regenerative cells in the epidermis of the skin

**carcinoma:** cancerous tumor

**cyanosis:** abnormal condition of blue skin; usually caused by low oxygen

**cyst:** a fluid-filled growth in skin

**dermatitis:** inflammation of the skin

**dermatocoinosis:** abnormal condition of the skin caused by dust

**dermatofibroma:** fibrous tumor of the skin

**dermatomycosis:** fungal infection of the skin

**epidermitis:** inflammation of the outer layer of the skin

**erythematous:** an inflammatory disease causing scaly red patches on the skin; also called systemic lupus erythematosus

**erythroderma:** red skin (abnormal redness of the skin)

**hemangioma:** benign tumor of the blood vessels; a type of birthmark

**hidradenitis:** inflammation of the sweat gland

**hyperhidrosis:** abnormal condition of excessive sweat

**ichthyosis:** abnormal condition of scaly/fishlike skin

**keratosis:** abnormal condition of horny tissue growth

**leukoderma:** white skin (patches of white skin caused by lack of pigment)

**leiodermia:** condition of smooth skin

**melanoma:** cancerous tumor of the melanin-producing cells; also called malignant melanoma

**metastasize:** produce cells that can mobilize and produce tumors in other organs

**necrosis:** condition of death (death of tissue)

**onychocryptosis:** abnormal condition of a hidden nail

**onychomalacia:** softening of the nails

**onychomycosis:** abnormal condition of a fungus in the nail

**onychopathy:** any disease of the nails

**onychophagia:** eating of the nails (nail biting)

**pachyderma:** thick

**paronychia:** infection around the nail

**pruritus:** condition causing itching

**seborrhea:** excessive discharge of sebum

**scleroderma:** hardness of the skin, chronic disease causing hardening of the skin

**staphylococcus:** berry-shaped bacterium in grapelike clusters

**streptococcus (strep):** berry-shaped bacterium in twisted chains

**xeroderma:** extremely dry skin

**xerosis:** abnormal condition of dryness

## Disease and Disorder Terms Not Built from Word Parts

**abscess:** localized collection of pus

**acne:** inflammatory papular and pustular eruption of the skin

**alopecia:** partial or complete loss or lack of hair (baldness)

**benign:** noncancerous/nonmalignant tumor

**bullae:** fluid-filled raised lesion >1cm (blister)

**comedo:** black head

**decubitus ulcer:** chronic ulcer caused by pressure over bony areas (seen in immobilized people)

**ecchymosis:** purple discoloration of skin >3mm in size, caused by blood pooling under the skin

**eczema:** inflammatory disorder causing redness, blisters, and scaling of skin

**excoriation:** linear break in skin (scratch)

**fissure:** deep, elongated break in the skin (crack)

**impetigo:** inflammatory disease with pustules that rupture

**keloid:** a raised scar

**lesion:** any wound, injury, or pathologic change in body tissue

**macule:** flat, discolored, flush area of the skin (freckle)

**nevus:** raised, discolored area, usually benign, but can be cancerous (mole)

**nodule:** small, round swelling under the skin

**petechiae:** tiny red/purple spots caused by capillary rupture

**plaque:** flat or raised lesions that may itch

**polyp:** an overgrowth of tissue on a mucous membrane

**pustule:** small, round, elevated lesion filled with pus

**scabies:** an infection of the skin caused by mites, highly contagious

**shingles:** a viral infection causing painful inflammation and pustular eruption of the nerve endings (also called herpes zoster)

**ulcer:** open sore of the skin or mucous membranes

**urticaria:** hives

**verruca:** wart caused by a virus

**vesicle:** small, fluid-filled, raised lesion (blister)

**vitiligo:** a loss of skin pigmentation in specific areas

**wheal:** smooth, rounded, slightly elevated area of skin that often itches

# PRACTICE

---

The following activities will allow you to practice what you've learned in this chapter.

## Label the Layers of the Skin

Click and drag each term to the box corresponding with the anatomic structure, body part, body plane, or body region for that term.



*An interactive H5P element has been excluded from this version of the text. You can view it online here:*

<https://louis.pressbooks.pub/medicalterminology/?p=2094#h5p-9>

## Medical Terms in Context—1

Click and drag each term from the word bank to its correct place in this exercise.



*An interactive H5P element has been excluded from this version of the text. You can view it online here:*

<https://louis.pressbooks.pub/medicalterminology/?p=2094#h5p-12>

## Medical Terms in Context—2

Click and drag each term from the word bank to its correct place in this exercise.



*An interactive H5P element has been excluded from this version of the text. You can view it online here:*

<https://louis.pressbooks.pub/medicalterminology/?p=2094#h5p-13>

## Vocabulary Reinforcement Activity

Click the term that correctly answers each question or completes each sentence.



*An interactive H5P element has been excluded from this version of the text. You can view it online here:*

<https://louis.pressbooks.pub/medicalterminology/?p=2094#h5p-14>

# REFERENCES

---

Centers for Disease Control and Prevention. (2018, October 25). [Psoriasis](https://www.cdc.gov/psoriasis/). Centers for Disease Control and Prevention: Fungal Diseases. <https://www.cdc.gov/psoriasis/>

Centers for Disease Control and Prevention. (2018a, August 6). [Ringworm](https://www.cdc.gov/fungal/diseases/ringworm/definition.html). Centers for Disease Control and Prevention: Fungal Diseases. <https://www.cdc.gov/fungal/diseases/ringworm/definition.html>

CrashCourse. (2015, January 6). [The Integumentary system, part 1—skin deep: Crash Course A&P #6](https://youtu.be/Orumw-PyNjw) [Video]. YouTube. <https://youtu.be/Orumw-PyNjw>

CrashCourse. (2015, February 16). [The Integumentary system, part 2—skin deeper: Crash Course A&P #7](https://youtu.be/EN-x-zXXVwQ) [Video]. YouTube. <https://youtu.be/EN-x-zXXVwQ>

Mayo Clinic Staff. (2017, September 6). [Mohs surgery](https://www.mayoclinic.org/tests-procedures/mohs-surgery/about/pac-20385222#:~:text=Mohs%20surgery%20is%20a%20precise,known%20as%20Mohs%20micrographic%20surgery.). Mayo Clinic. <https://www.mayoclinic.org/tests-procedures/mohs-surgery/about/pac-20385222#:~:text=Mohs%20surgery%20is%20a%20precise,known%20as%20Mohs%20micrographic%20surgery.>

Unless otherwise indicated, this chapter contains material adapted from [Building a Medical Terminology Foundation](#), by Kimberlee Carter and Marie Rutherford and is used under a [CC BY 4.0 international license](#), which itself contained material adapted from [Anatomy and Physiology](#) (on OpenStax), by Betts, et al. and is used under a [CC BY 4.0 international license](#).

## PART VIII

# CARDIOVASCULAR SYSTEM—PART I: THE HEART

## Learning Objectives

When completing this chapter, the learner will be able to do the following:

- Identify the anatomy of the heart
- Describe the main functions of the heart
- Spell terms relating to the heart and use correct abbreviations
- Pronounce terms relating to the heart and use correct abbreviations
- Identify the medical specialties associated with the heart
- Explore common diseases, disorders, and procedures related to the heart

## Introduction to the Heart

The heart is a fist-sized vital organ that has one job: to pump blood. If one assumes an average **heart rate** of 75 beats per minute, a human heart would beat approximately 108,000 times in one day, more than 39 million times in one year, and nearly 3 billion times during a 75-year lifespan. At rest, each of the major pumping chambers of the heart ejects approximately 70 mL of blood per contraction in an adult. This would be equal to 5.25 liters of blood per minute and approximately 14,000 liters per day. Over one year, that would equal 10,000,000 liters of blood sent through roughly 100,000 km of blood vessels. In order to understand how that happens, it is necessary to understand the anatomy and physiology of the heart.

## Watch this video:



One or more interactive elements has been excluded from this version of the text. You can view them online here: <https://louis.pressbooks.pub/medicalterminology/?p=1407#oembed-1>

Media 8.1. [The Heart, Part 1—Under Pressure: Crash Course A&P #25](#) [Online video]. Copyright 2015 by [CrashCourse](#).

# ANATOMY OF THE HEART

---

## Location

The human heart is located within the thoracic cavity, between the lungs in the space known as the **mediastinum**. [Figure 8.1](#) shows the position of the heart within the thoracic cavity. Within the mediastinum, the heart is separated from the other mediastinal structures by a tough membrane known as the **pericardium**, or **pericardial sac**, and sits in its own space called the **pericardial cavity**. The **great vessels**, which carry blood to and from the heart, are attached to the superior surface of the heart, which is called the base. The inferior tip of the heart is called the apex.

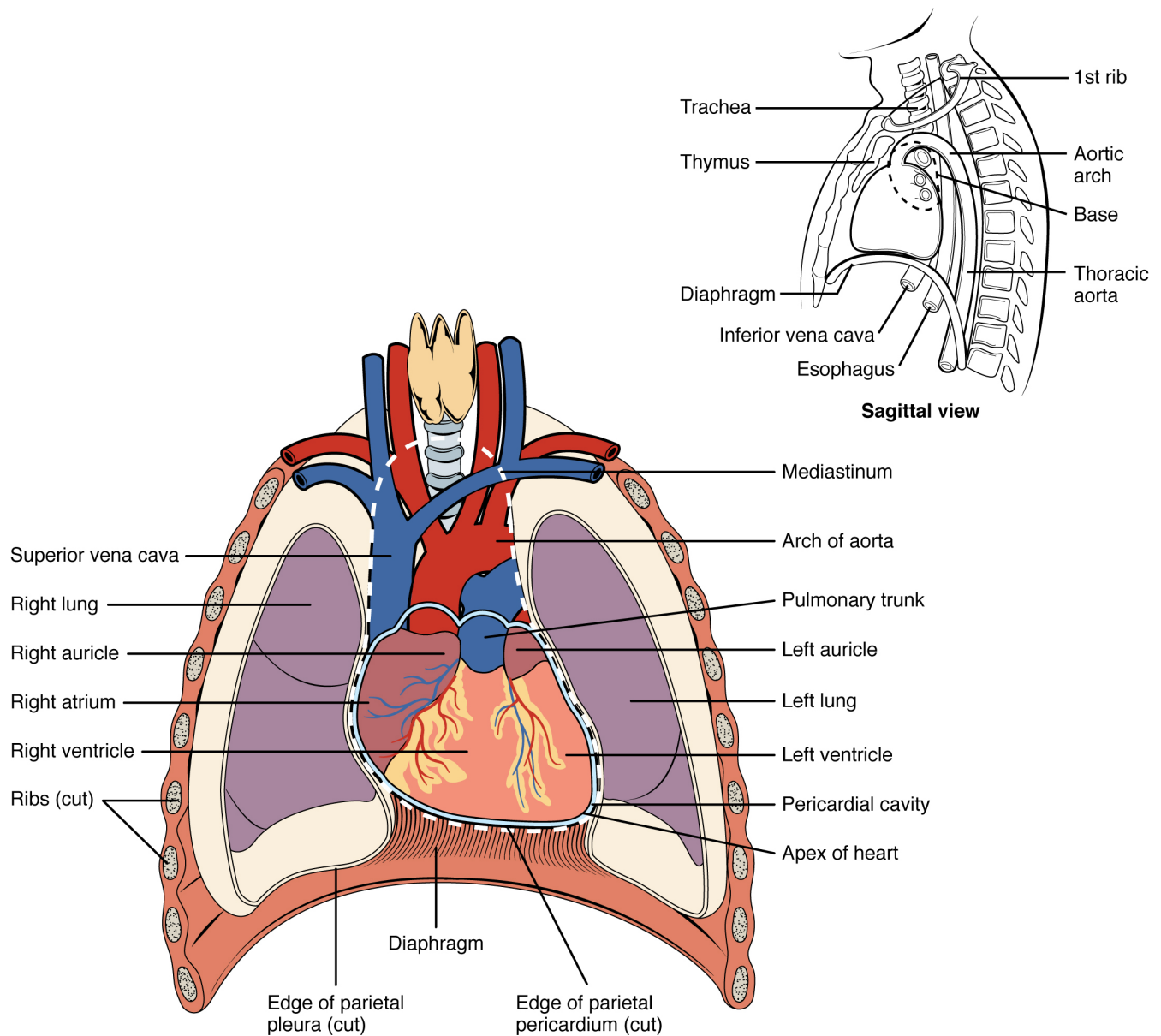


Figure 8.1 Position of the Heart in the Thorax. The heart is located within the thoracic cavity, medially between the lungs in the mediastinum. It is about the size of a fist, is broad at the top, and tapers toward the base. From Betts, et al., 2013. Licensed under [CC BY 4.0](https://creativecommons.org/licenses/by/4.0/). [\[Image description.\]](#)

## Membranes and Layers of the Heart Walls

The heart and the roots of the great vessels are surrounded by a membrane known as the pericardium or pericardial sac ([Figure 8.2](#)). The pericardium consists of two distinct sublayers:

- the outer **parietal pericardium**, which is fused to the **fibrous pericardium**
- the inner **visceral pericardium**, or **epicardium**, which is fused to the heart and forms the outer layer of the heart wall

The walls of the heart consist of three layers:

- the outer epicardium, which is another name for the visceral pericardium mentioned above
- the thick, middle **myocardium**, which is made of muscle tissue and gives the heart its ability to contract
- the inner **endocardium**, which lines the heart chambers and is the main component of the heart valves

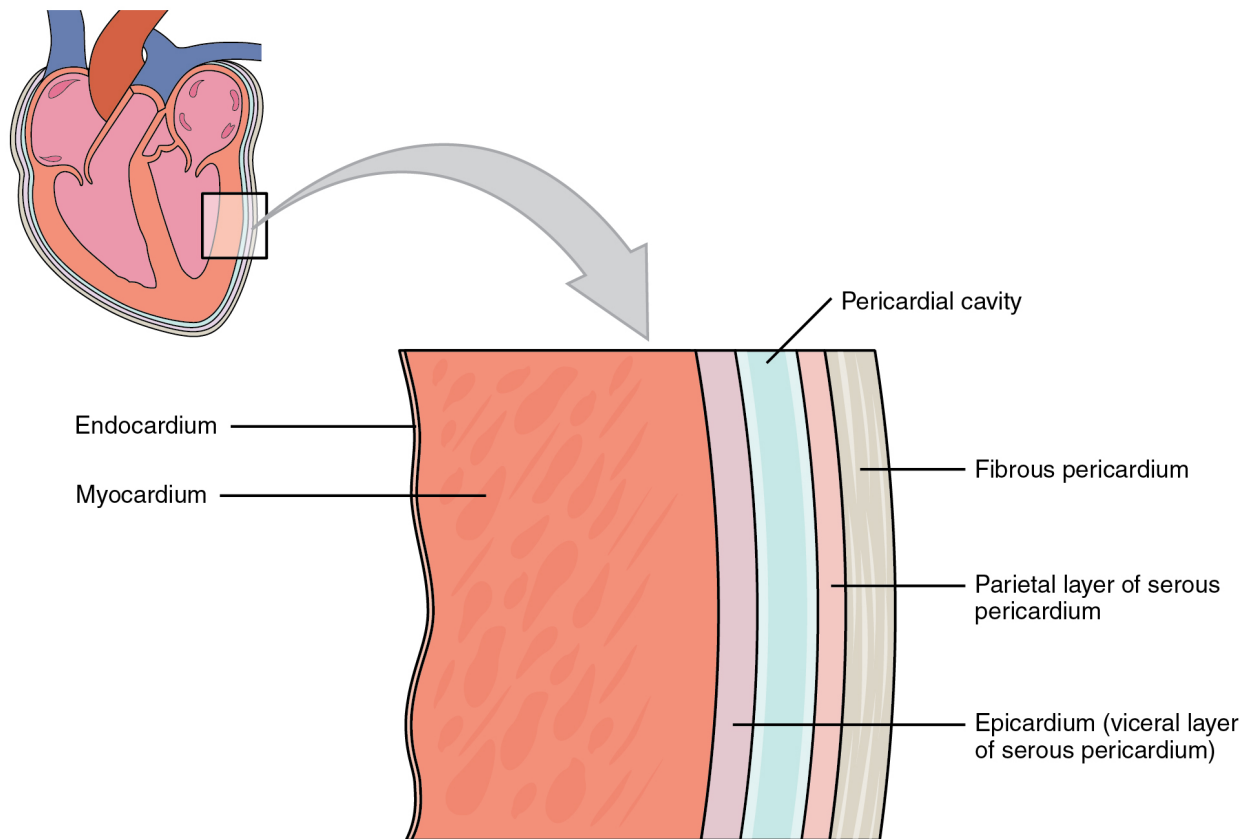


Figure 8.2 Pericardial Membranes and Layers of the Heart Wall. The pericardial membrane that surrounds the heart consists of three layers and the pericardial cavity. The heart wall also consists of three layers. The pericardial membrane and the heart wall share the epicardium. From Betts, et al., 2013. Licensed under [CC BY 4.0](https://creativecommons.org/licenses/by/4.0/). [\[Image description.\]](#)

# Internal Structures of the Heart

The heart consists of four chambers:

- The upper chambers are the **right and left atria** (singular: atrium).
- The lower chambers are the **right and left ventricles**.

The **interventricular septum** is a muscular wall that separates the right and left ventricles. The **interatrial septum** separates the right and left atria. The atrium and ventricle on each side of the heart are separated by an **atrioventricular (AV) valve**:

- The right AV valve, or **tricuspid valve**, separates the right atrium and right ventricle.
- The left AV valve, or **bicuspid valve**, separates the left ventricle and the left atrium. This valve is also called the mitral valve.

There are also two semilunar valves:

- The **pulmonary valve** separates the right ventricle from the pulmonary trunk.
- The **aortic valve** separates the left ventricle from the aorta.

## Image Descriptions

**Figure 8.1 image description:** This diagram shows the location of the heart in the thorax (sagittal and anterior views). The sagittal view labels read (from top, clockwise): first rib, aortic arch, thoracic arch, esophagus, inferior vena cava, diaphragm, thymus, trachea. The anterior view labels read (from top, clockwise): mediastinum, arch of aorta, pulmonary trunk, left auricle, left lung, left ventricle, pericardial cavity, apex of heart, edge of parietal pericardium, diaphragm, edge of parietal pleura, ribs, right ventricle, right atrium, right auricle, right lung, superior vena cava. [\[Return to Figure 8.1\]](#).

**Figure 8.2 image description:** This image shows a magnified view of the structure of the heart wall. Labels read (from top, clockwise): pericardial cavity, fibrous pericardium, parietal layer of serous pericardium, epicardium (visceral layer of serous pericardium), myocardium, endocardium. [\[Return to Figure 8.2\]](#).

# PHYSIOLOGY OF THE HEART

---

In order for the heart to do its job of pumping blood to the lungs and to the body, nutrients and oxygen must be supplied to the cells of the heart. The heart also needs to coordinate its contractions so that all parts are working together to pump blood effectively. To understand how all of this works together to give the heart its ability to pump blood, we will examine three interdependent aspects of heart function:

1. Circulation through the heart: Blood is pumped by the heart in order to provide oxygen and nutrients to every cell in the body.
2. The heart as an organ (coronary blood supply): The heart is an organ made of cells and tissues that require their own blood supply.
3. The heart's electrical conduction system: The heart is able to independently generate and transmit electrical signals to the myocardium in order to make it contract and pump the blood.

## 1. Circulation through the Heart: The Heart as a Pump

The heart pumps blood to two distinct but linked circulatory systems called the **pulmonary** and **systemic circuits**. The pulmonary circuit transports blood to and from the lungs, where it picks up oxygen and drops off carbon dioxide. The systemic circuit transports freshly oxygenated blood to virtually all of the tissues of the body and returns relatively deoxygenated blood and carbon dioxide to the heart to be sent back to the pulmonary circulation.

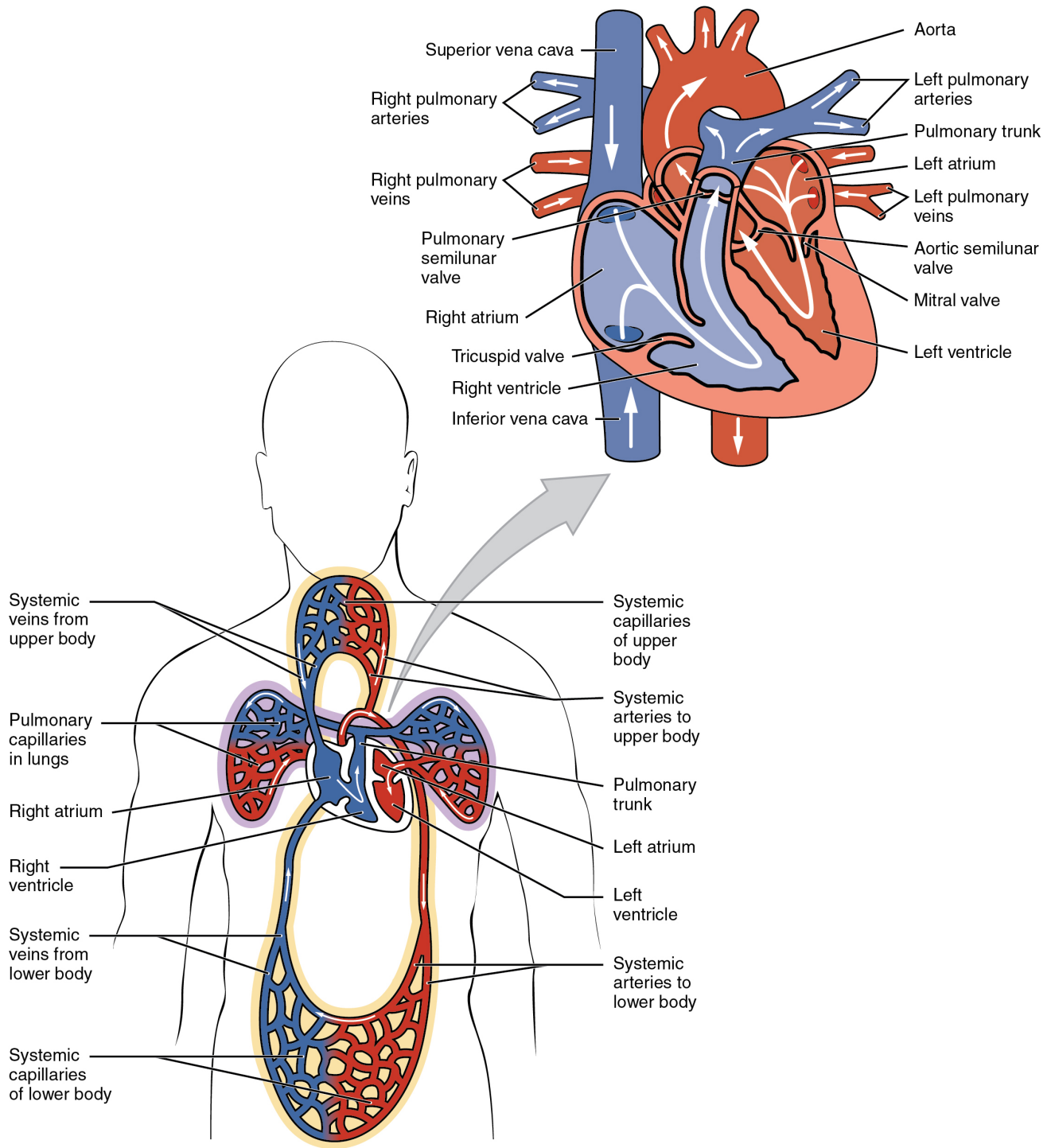


Figure 8.4 Dual System of Human Blood Circulation. Blood flows from the right atrium to the right ventricle, where it is pumped into the pulmonary circuit. The blood in the pulmonary artery branches is low in oxygen but relatively high in carbon dioxide. Gas exchange occurs in the pulmonary capillaries (oxygen into the blood, carbon dioxide out), and blood high in oxygen and low in carbon dioxide is returned to the left atrium. From here, blood enters the left ventricle, which pumps it into the systemic circuit. Following exchange in the systemic capillaries (oxygen and nutrients out of the capillaries and carbon dioxide and wastes in), blood returns to the right atrium, and the cycle is repeated. From Betts, et al., 2013. Licensed under [CC BY 4.0](https://creativecommons.org/licenses/by/4.0/). [Image description.]

## Cardiac Cycle

The process of pumping and circulating blood is active, coordinated, and rhythmic. Each heartbeat represents one cycle of the heart receiving blood and ejecting blood.

- **Diastole** is the portion of the cycle in which the heart is relaxed and the atria and ventricles are filling with blood. The AV valves are open so that blood can move from the atria to the ventricles.
- **Systole** is the portion of the cycle in which the heart contracts, the AV valves slam shut, and the ventricles eject blood to the lungs and to the body through the open semilunar valves. Once this phase ends, the semilunar valves close in preparation for another filling phase.

## 2. The Heart as an Organ: The Coronary Blood Supply

Myocardial cells require their own blood supply to carry out their function of contracting and relaxing the heart in order to pump blood. This blood supply, provided by the **coronary arteries** and **coronary veins**, supplies nutrients and oxygen and carries away carbon dioxide and waste.

## 3. The Heart's Electrical Conduction System

In order for all parts of the heart to work together to beat regularly and effectively, the heart has its own electrical system, which initiates and conducts each heartbeat through the entire myocardium. Specialized groups of heart cells perform this function all on their own, without requiring messages from the central nervous system.

## Image Descriptions

**Figure 8.4 image description:** The top panel shows the human heart with the arteries and veins labeled (from top, clockwise): aorta, left pulmonary arteries, pulmonary trunk, left atrium, left pulmonary veins, aortic semilunar valve, mitral valve, left ventricle, inferior vena cava, right ventricle, tricuspid valve, right atrium, pulmonary semilunar valve, right pulmonary veins, right pulmonary arteries, superior vena cava. The bottom panel shows a rough map of the human circulatory system. Labels read (from top, clockwise): systemic capillaries of upper body, systemic arteries to upper body, pulmonary trunk, left atrium, left ventricle, systemic

arteries to lower body, systemic capillaries of lower body, systemic veins from lower body, right ventricle, right atrium, pulmonary capillaries in lungs, systemic veins from upper body. [\[Return to Figure 8.4\].](#)

# WORD PARTS AND STRUCTURAL TERMS

---

## Combining Forms

- atri/o:** atrium
- cardi/o:** heart
- cuspid/i:** point
- ech/o:** sound
- electr/o:** electricity
- symptomato/o:** symptom
- valv/o:** valve
- valvul/o:** valve
- vascul/o:** vessel
- ventricul/o:** ventricle

## Prefixes

- a-:** absence of, without
- bi-:** two
- brady-:** slow
- endo-:** within, in
- epi-:** on, upon, over
- hyper-:** above, excessive
- hypo-:** below, deficient
- inter-:** between
- pan-:** all, total
- peri-:** surrounding, around
- tachy-:** fast, rapid
- tri-:** three

## Suffixes

- ac**: pertaining to (adjective)
- apheresis**: removal (noun)
- ar**: pertaining to (adjective)
- centesis**: surgical puncture to aspirate fluid (noun)
- ectomy**: excision, surgical removal (noun)
- genic**: producing, originating, causing (adjective)
- gram**: record, radiographic image (noun)
- graph**: instrument used to record (noun)
- graphy**: process of recording, radiographic imaging (noun)
- ia**: condition of, diseased state, abnormal state (noun)
- ic**: pertaining to (adjective)
- itis**: inflammation (noun)
- lysis**: loosening, dissolution, separating (noun)
- megaly**: enlarged, enlargement (noun)
- logist**: specialist, physician who studies and treats (noun)
- oma**: tumor (noun)
- osis**: abnormal condition (noun)
- tomy**: cut into, incision (noun)
- ous**: pertaining to (adjective)
- pathy**: disease (noun)
- penia**: abnormal reduction in number (noun)
- pexy**: surgical fixation, suspension (noun)
- plasty**: surgical repair (noun)
- poiesis**: formation (noun)
- sclerosis**: hardening (noun)
- scope**: instrument used to view (noun)
- scopy**: process of viewing (noun)
- stasis**: stop, stopping, controlling (noun)
- stenosis**: narrowing, constriction (noun)

## Structural Terms Built from Word Parts

**atrial**: pertaining to one or both atria

**atrioventricular**: pertaining to the atrium and ventricle

**bicuspid:** having two pointed folds/flaps

**cardiac:** pertaining to the heart

**cardiogenic:** originating in the heart

**cardiovascular:** pertaining to the heart and vessels

**endocardial:** pertaining to the endocardium

**interatrial:** pertaining to between the atria

**interventricular:** pertaining to between the ventricles

**myocardial:** pertaining to the myocardium

**pericardial:** pertaining to the pericardium

**tricuspid:** having three pointed folds/flaps

**ventricular:** pertaining to one or both ventricles

# DISEASES AND DISORDERS

---

## Disease and Disorder Terms Built from Word Parts

- bradycardia:** an abnormally slow heart rate
- cardiodynia:** pain in the heart
- cardiomegaly:** enlargement of the heart
- cardiomyopathy:** disease of the myocardium
- cardiovalvulitis:** inflammation of the heart valves
- endocarditis:** inflammation of the endocardium
- myocarditis:** inflammation of the myocardium
- pericarditis:** inflammation of the pericardium
- tachycardia:** an abnormally fast heart rate

## Disease and Disorder Terms Not Built from Word Parts

- acute coronary syndrome:** sudden symptoms of insufficient blood supply to the heart, caused by angina or a myocardial infarction
- angina pectoris:** chest pain
- arrhythmia:** absence of a regular heart rhythm
- atrial fibrillation:** arrhythmia originating in the conductive cells of the atrium
- bruit:** abnormal blowing, swishing heart sound heard on auscultation
- cardiac arrest:** sudden cessation of cardiac output
- cardiac tamponade:** the pericardial sac surrounding the heart has filled with blood or other fluid and the resulting pressure is preventing the heart from beating effectively
- congenital heart disease:** an inborn heart disease
- cor pulmonale:** a condition that causes right-sided heart failure, caused by long-term high blood pressure in the pulmonary arteries and right ventricle
- heart block:** an obstruction in the electrical conduction system of the heart, which leads to arrhythmia
- heart failure:** inability of the heart to pump enough blood through the body
- heart murmur:** an abnormal heart sound
- hypertensive heart disease:** heart disorder caused by chronic hypertension

**mitral valve stenosis:** abnormal narrowing of the mitral valve

**myocardial infarction:** death of myocardial tissue due to ischemia of a coronary artery (“heart attack”)

**rheumatic heart disease:** autoimmune damage to the endocardium and heart valves caused by a streptococcal infection

**Tetralogy of Fallot:** a congenital heart disease with four distinct areas of heart malformation

# MEDICAL, SURGICAL, & VIEWING TERMS AND ABBREVIATIONS

---

## Medical Careers & Professional Terminology

**cardiology:** the study of the heart and its disorders

**cardiology technologists:** perform diagnostic tests such as electrocardiography, stress testing, Holter monitor testing, and ambulatory blood pressure testing, as well as pacemaker monitoring and programming

**cardiologist:** a physician specializing in cardiology

**cardiovascular perfusionists:** responsible for operation of the heart-lung bypass machine during open heart surgery; also monitor the patient's vitals, administering IV fluids and other drugs

## Imaging Techniques/Procedures for the Organ System

**coronary angiogram:** a visual record of coronary angiography

**coronary angiography:** a procedure that uses contrast dye, usually containing iodine, and x-ray pictures to detect blockages in the coronary arteries that are caused by plaque buildup

## Surgical Techniques/Medical Procedures/ Diagnostic Procedures/Medications Used with the Organ System

**artificial cardiac pacemaker:** a small, battery-operated medical device that generates electrical impulses delivered by electrodes to cause the heart muscle chambers to contract and pump blood

**auscultation:** listening to a patient's heart sounds

**automatic implantable cardiac defibrillator:** an electronic implant that provides an automatic shock to convert a dangerous heart rhythm to a normal heart rhythm

**cardiac catheterization:** a procedure in which a thin, flexible tube is guided through a blood vessel to the heart to diagnose or treat certain heart conditions

**catheter ablation:** Using extreme heat or extreme cold to destroy cells in parts of the heart that were causing abnormal rhythms

**coronary artery bypass graft:** a nonvital superficial vessel from another part of the body (often the great saphenous vein) or a synthetic vessel is inserted to create a path around the blocked area of a coronary artery

**coronary stent:** a tiny coil of wire mesh that supports the walls of a coronary artery and helps prevent it from re-narrowing after angioplasty

**echocardiogram:** a visual record using sound to record the heart

**echocardiography:** Process of using sound to record the heart.

**electrocardiogram:** a visual record of the electrical impulses in the heart

**electrocardiograph:** a device used to create an electrocardiogram

**electrocardiography:** the process of recording the electrical impulses of the heart

**exercise stress test:** a test that shows how the heart works during physical activity

**pericardiocentesis:** removal of pericardial fluid for treatment or testing

**valvuloplasty:** surgical repair of a heart valve

## Abbreviations Commonly Used with the Organ System

**ACS:** acute coronary syndrome

**Afib:** atrial fibrillation

**AICD:** automatic implantable cardiac defibrillator

**AV:** atrioventricular

**CAD:** coronary artery disease

**CPR:** cardiopulmonary resuscitation

**ECG/EKG:** electrocardiogram

**ECHO:** echocardiogram

**HF:** heart failure

**HHD:** hypertensive heart disease

**MI:** myocardial infarction

## Medical Terms Practice

For each card, click the speaker icon to hear the correct pronunciation of the listed term. Practice saying the term to yourself, then attempt to define the term from memory. Click “Turn” to flip the card and see the definition. Use the right and left arrows to toggle through the cards in each set.



*An interactive H5P element has been excluded from this version of the text. You can view it online here:*

<https://louis.pressbooks.pub/medicalterminology/?p=1480#h5p-56>



*An interactive H5P element has been excluded from this version of the text. You can view it online here:*

<https://louis.pressbooks.pub/medicalterminology/?p=1480#h5p-58>

# PRACTICE

---

The following activities will allow you to practice what you've learned in this chapter.

## Anatomy Labeling Activity

Click and drag each term to the box corresponding with the anatomic structure, body part, body plane, or body region for that term.



*An interactive H5P element has been excluded from this version of the text. You can view it online here:*

<https://louis.pressbooks.pub/medicalterminology/?p=2102#h5p-57>

## Medical Terms in Context

Click and drag each term from the word bank to its correct place in this exercise.



*An interactive H5P element has been excluded from this version of the text. You can view it online here:*

<https://louis.pressbooks.pub/medicalterminology/?p=2102#h5p-60>

## Vocabulary Reinforcement Activity

Click the term that correctly answers each question or completes each sentence.



*An interactive H5P element has been excluded from this version of the text. You can view it online here:*

<https://louis.pressbooks.pub/medicalterminology/?p=2102#h5p-61>

# REFERENCES

---

- Canadian Medical Association. (2018). [Canadian Specialty Profiles](https://www.cma.ca/canadian-specialty-profiles). <https://www.cma.ca/canadian-specialty-profiles>
- Canadian Society of Cardiology Technologists. (n.d.). [Becoming a registered cardiology technologist](https://www.csct.ca/education/about-being-rct). <https://www.csct.ca/education/about-being-rct>
- Centers for Disease Control and Prevention. (2019). [Cardiomyopathy](https://www.cdc.gov/heartdisease/cardiomyopathy.htm). CDC. <https://www.cdc.gov/heartdisease/cardiomyopathy.htm>
- Centers for Disease Control and Prevention. (2019a). [Valvular heart disease](https://www.cdc.gov/heartdisease/valvular_disease.htm). CDC. [https://www.cdc.gov/heartdisease/valvular\\_disease.htm](https://www.cdc.gov/heartdisease/valvular_disease.htm)
- Centers for Disease Control and Prevention. (2019b). [Aortic aneurysm](https://www.cdc.gov/heartdisease/aortic_aneurysm.htm). CDC. [https://www.cdc.gov/heartdisease/aortic\\_aneurysm.htm](https://www.cdc.gov/heartdisease/aortic_aneurysm.htm)
- [CrashCourse]. (2015, July 6). [The heart, part 1—under pressure: Crash course A&P #25](https://youtu.be/X9ZZ6tcxArI) [Video]. YouTube. <https://youtu.be/X9ZZ6tcxArI>
- Heart & Stroke. (n.d.). [Heart failure](https://www.heartandstroke.ca/heart/conditions/heart-failure). Heart and Stroke Foundation. <https://www.heartandstroke.ca/heart/conditions/heart-failure>
- Michener Institute for Education. (n.d.). [Cardiovascular perfusion](https://michener.ca/program/cardiovascular-perfusion/). Michener Institute of Education at UHN. <https://michener.ca/program/cardiovascular-perfusion/>
- Tittley, J. G. (n.d.). [Thoracic aortic aneurysms \(TAA\)](https://canadianvascular.ca/Thoracic-Aortic-Aneurysms-(TAA)). Retrieved from Canadian Society for Vascular Surgery: [https://canadianvascular.ca/Thoracic-Aortic-Aneurysms-\(TAA\)](https://canadianvascular.ca/Thoracic-Aortic-Aneurysms-(TAA))

Unless otherwise indicated, this chapter contains material adapted from [Building a Medical Terminology Foundation](#), by Kimberlee Carter and Marie Rutherford and is used under a [CC BY 4.0 international license](#), which itself contained material adapted from [Anatomy and Physiology](#) (on OpenStax), by Betts, et al. and is used under a [CC BY 4.0 international license](#).



## PART IX

# CARDIOVASCULAR SYSTEM—PART II: BLOOD AND BLOOD VESSELS

## Learning Objectives

- Identify the anatomy of the blood vessels and blood
- Describe the main functions of the blood vessels and blood
- Spell terms relating to the blood vessels and blood and use correct abbreviations
- Pronounce terms relating to the blood vessels and blood and use correct abbreviations
- Identify the medical specialties associated with the blood vessels and blood
- Explore common diseases, disorders, and procedures related to the blood vessels and blood

## Introduction

Our large, complex bodies need blood to deliver nutrients to and remove wastes from our trillions of cells. The heart, as discussed in the previous chapter, pumps blood throughout the body in a network of blood vessels. Together, these three components—blood, heart, and vessels—make up the cardiovascular system.

Virtually every cell, tissue, organ, and system in the body is impacted by the circulatory system. This includes the generalized and more specialized functions of transport of materials, capillary exchange, maintaining health by transporting white blood cells and various immunoglobulins (antibodies), hemostasis, regulation of body temperature, and helping to maintain acid-base balance.

## Watch this video:



One or more interactive elements has been excluded from this version of the text. You can view them online here: <https://louis.pressbooks.pub/medicalterminology/?p=1409#oembed-1>

Media 9.1 [Blood Vessels, Part 1—Form and Function: Crash Course A&P #27](#) [Online video].

Copyright 2015 by [CrashCourse](#).

# ANATOMY OF THE BLOOD VESSELS

---

## Anatomy of the Blood Vessels

Blood pumped by the heart flows through a series of vessels known as arteries, arterioles, capillaries, venules, and veins before returning to the heart.

- **Arteries** transport blood away from the heart and branch into smaller vessels, forming arterioles.
- **Arterioles** distribute blood to capillary beds, the sites of exchange with the body tissues.
- A **capillary** is a microscopic channel that supplies blood to the tissues themselves, a process called **perfusion**.
  - Exchange of gases and other substances occurs in the capillaries between the blood and the surrounding cells and their tissue fluid (interstitial fluid).
  - For capillaries to function, their walls must be leaky, allowing substances to pass through.
  - Capillaries lead back to small vessels known as **venules**.
- Venules are small veins that converge into larger **veins**.
- A vein is a blood vessel that conducts blood toward the heart.
  - Compared to arteries, veins are thin-walled vessels with large and irregular lumens.
  - Larger veins are commonly equipped with valves that promote the unidirectional flow of blood toward the heart and prevent backflow toward the capillaries caused by the inherent low blood pressure in veins as well as the pull of gravity.
  - Other ways in which the body assists the transport of venous blood back to the heart involve contractions of skeletal muscles in the extremities (see figure below) as well as pressure variations caused by the breathing motion of the chest.

Both arteries and veins have the same three distinct tissue layers, called tunics (after the garments first worn by ancient Romans). From the most interior layer to the outer, these tunics are the **tunica intima**, the **tunica media**, and the **tunica externa** (see [Figure 9.1](#)). The smooth muscle in the middle layer, the tunica media, provides the vessel with the ability to **vasoconstrict** and **vasodilate** as needed to ensure sufficient blood flow.