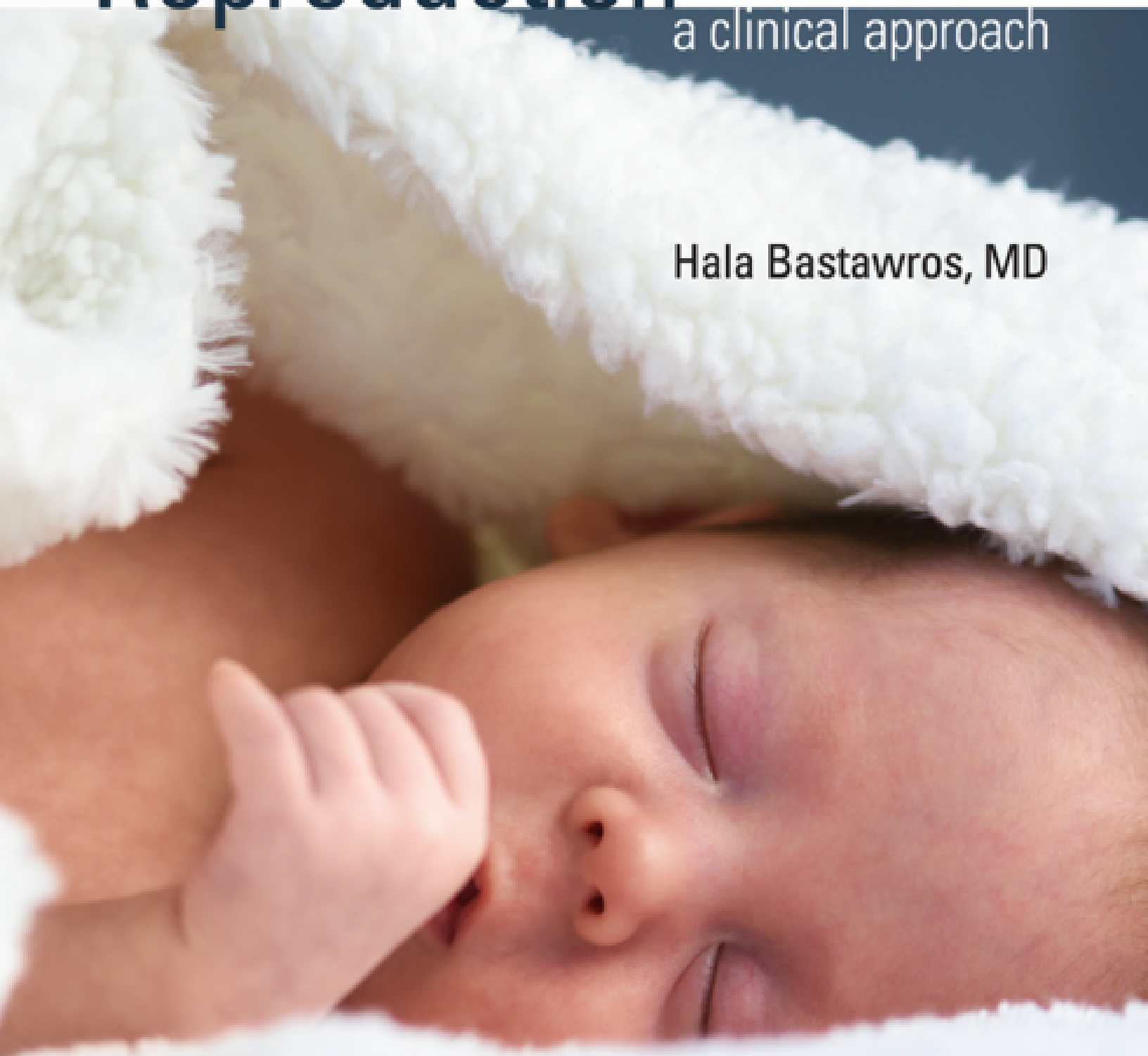

Human Reproduction

a clinical approach

Hala Bastawros, MD



Human Reproduction: A Clinical Approach

Dr. Hala Bastawros, M.D

Iowa State University Digital Press
Ames, Iowa



Human Reproduction: A Clinical Approach Copyright © 2023 by Dr. Hala Bastawros, M.D is licensed under a [Creative Commons Attribution-NonCommercial 4.0 International License](https://creativecommons.org/licenses/by-nc/4.0/), except where otherwise noted.

You are free to copy, share, adapt, remix, transform, and build upon the material, so long as you follow the terms of the license.

This is a publication of the
Iowa State University Digital Press
701 Morrill Rd, Ames, IA 50011
<https://www.iastatedigitalpress.com>
digipress@iastate.edu

Contents

About this book vi

The Female Reproductive System

Female External Genitalia 2
Female Internal Genitalia 9
Uterine Tubes 13
Uterus and Uterine Cervix 16
Vagina 24
Mammary Glands 26

Female Endocrinology

Hormonal Control of Reproductive Systems 30
Hormones of the Menstrual Cycle 33
Menstrual Cycle Pattern 40
Menstrual Disorders 43

The Male Reproductive System

Scrotum and Testes 47
Male Reproductive Ducts 54
Accessory Glands 55
Penis 58
Ejaculate 61

Male Endocrinology

Hormonal Regulation in the Male Reproduction 65

Stages of Life

Puberty 69
Menopause 72

Gametogenesis, Fertilization, and Implantation

Gametogenesis 78

Fertilization	83
Post Fertilization and Pre-Embryonic Stage	87
Implantation	90
Placenta Development	93
Embryogenesis	97

Genetic Disorders

Genetic Disorders	102
Sex Chromosome Number Disorders	105
Prenatal Diagnosis and Genetic Counseling	108

Normal Pregnancy

Endocrinology of Pregnancy	113
Physiological Changes During Pregnancy	117
Nutrition and Pregnancy	120
Lifestyle During Pregnancy	122

Labor and Birth

Labor and Birth	125
Labor Medication and Tools	131
Complications During Pregnancy and Labor	134

Contraception

Natural Contraception	139
Barrier Contraception Methods	140
Oral Contraception Pills (OCP)	143
Alternative Methods of Hormonal Administration	145
Intrauterine Devices	147
Surgical Sterilization	149
Contraception in Specialized Conditions	150
Male Contraceptive Hormonal Vaccines	152

Infertility

Infertility	154
Male Infertility Evaluation	157

Female Infertility Evaluation	159
Infertility Treatment	164
Assisted Reproductive Techniques	166

Sexual Transmitted Diseases

Sexually Transmitted Diseases	170
Bacterial Sexually Transmitted Infections and Diseases	172
Viral Sexually Transmitted Infections and Diseases	174
Human Immunodeficiency Virus (HIV) and Pregnancy	176

Pelvic Pain

Pelvic Pain	179
About the Author	184
Reviewers	185

About this book

This open textbook is designed to provide a deep understanding of the biological and biomedical aspects of human reproduction, covering a wide range of topics from basic reproductive biology to clinical applications. The book has a well-structured approach, starting with foundational knowledge and progressing to more advanced topics while also including real-world clinical orientation for practical contexts.

The following topics are addressed throughout the book's major sections:

1. **Fundamentals of Reproduction:** Explaining the basic biological processes of male and female reproductive systems and hormones.
2. **Aging of the Reproductive System:** Exploring how the reproductive system changes as individuals age, including menopause and its implications.
3. **Conception and Fetal Development:** Delving into the stages of conception, embryonic development, and the factors influencing fetal growth and health.
4. **Physiological Changes of Pregnancy:** Detailing the hormonal, anatomical, and physiological adaptations that occur in a woman's body during pregnancy.
5. **Labor and Birth:** Discussing the processes of labor, childbirth, and the associated physiological changes in both the mother and the newborn.
6. **Population Growth and Family Planning:** Addressing the broader societal aspects of reproduction, including discussions on population growth, family planning, and contraception methods.
7. **Infertility and Management:** Covering the causes of infertility, diagnostic techniques, and available treatment options, including assisted reproductive technologies.
8. **Sexually Transmitted Diseases:** Examining common sexually transmitted infections, their impact on reproductive health, and methods of prevention and treatment.
9. **Clinical Correlation:** Incorporating real-world clinical scenarios and applications within the chapters helps bridge the gap between theoretical knowledge and real-world implementation. These clinical applications are included across several chapters.

The Female Reproductive System

Female External Genitalia

External genitalia are located in the perineal region. The **perineum** is the diamond-shaped space between the bony landmark, pubic symphysis (anteriorly), the coccyx (posteriorly), and the ischial tuberosities (laterally). Lying just inferior to the pelvic diaphragm (levator ani and coccygeus) until it reaches the skin. It is divided transversely into triangles, the anterior “**urogenital triangle**,” where the external genitals, the urethral and vaginal orifices in females, are located, and the posterior, “**anal triangle**,” which contains the anus and external anal sphincter in both sexes (Figure 1).

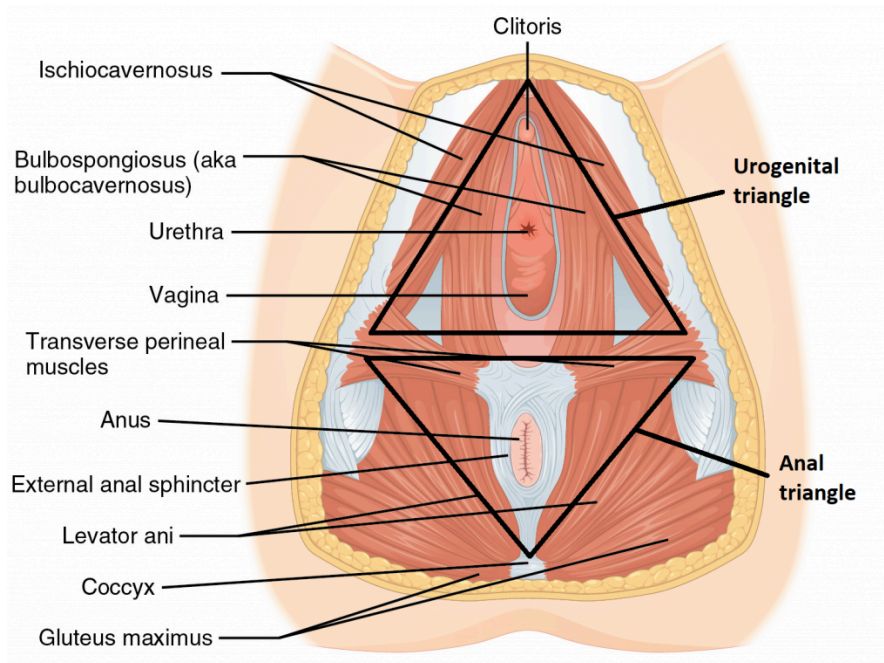


Figure 1. Labeled muscles of the perineum.

The external female reproductive structures are referred to collectively as the **vulva** (Figure 2 and 3). The **mons pubis** is a pad of fat that is located at the anterior, over the pubic bone. After puberty, it becomes covered in pubic hair. The **labia majora** (labia = “lips”; majora = “larger”) are folds of hair-covered skin that begin just posterior to the mons pubis. The labia majora possess sebaceous and sweat glands and are homologous to the scrotum of the male.

The thinner and more pigmented **labia minora** (labia = “lips”; minora = “smaller”) extends medial to the labia majora. Although they naturally vary in shape and size from woman to woman, labia minora are devoid of hair and are highly vascularized with numerous melanocytes. The space between the labia minora is the **vestibule**. Within the vestibule reside the **urethral opening**, the **vaginal orifice**, and a pair

of **greater vestibular glands (glands of Bartholin)**. The **vestibular glands secrete liquid** which keeps the vestibular area moist **and lubricates the area during sexual intercourse**.

The superior, anterior portions of the labia minora come together and form the **prepuce**, a hoodlike covering over the clitoris. The **clitoris** is a small (< 2 cm), erectile body, located superior to the urethral opening and homologous to the penis of the male. It consists of two small erectile bodies called the **corpora cavernosa** form the body of the clitoris and the glands capping the body of the clitoris. The clitoris has abundant nerves that make it important in sexual sensation and orgasm.

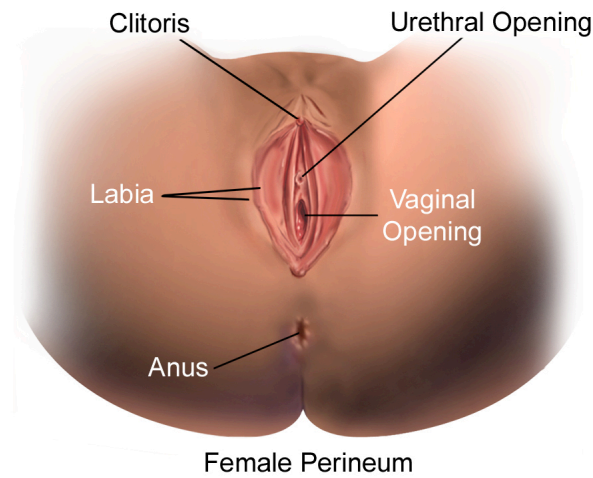


Figure 2. The labeled parts of the external female genitalia.

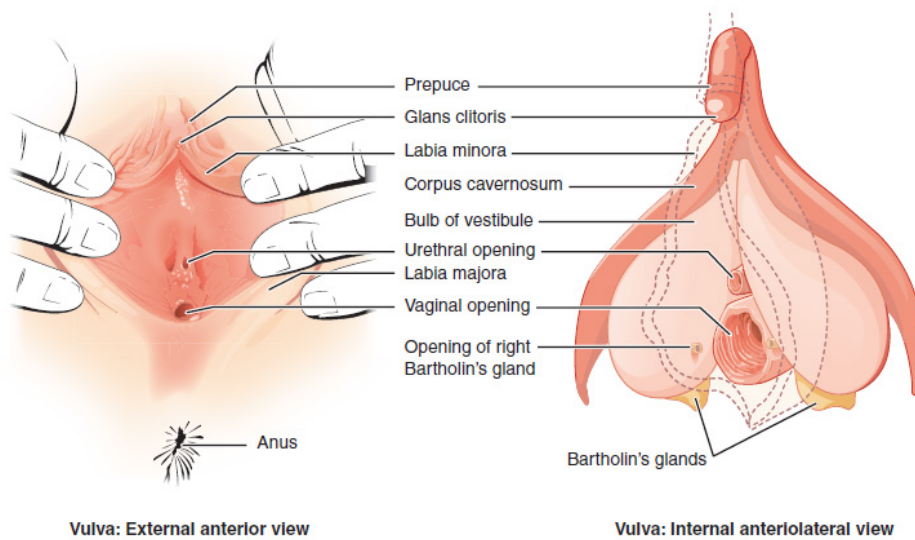


Figure 3. The external female genitalia are referred to collectively as the vulva.

The **hymen** is a thin perforated membrane that covers the entrance to the vagina. An intact hymen cannot be used as an indication of “virginity”. The hymen can be ruptured with strenuous physical exercise, penile–vaginal intercourse, and childbirth. The hymen is only a partial membrane, as menstrual fluid and other secretions must be able to exit the body. Figure 4 shows different shapes the membrane can take.

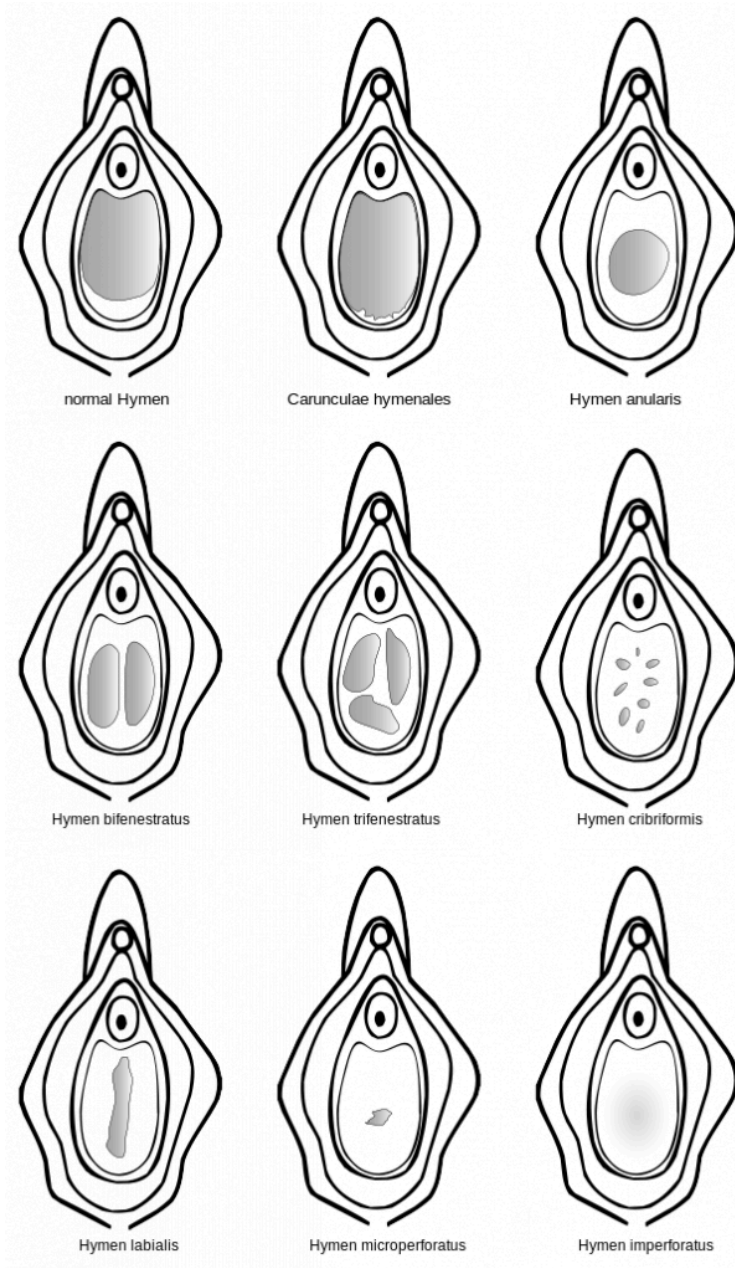


Figure 4. Hymen membrane placement.

Clinical Correlation

Imperforated hymen (Figure 4)

Failure of the hymen to perforate leads to fluid and menstrual blood accumulation and bulge of the membrane. The condition is usually associated with pubic pain at the puberty with the first mensural cycle. Surgical opening and perforation of the membrane can relieve this condition.

Bartholin's cyst/abscess (Figure 5)

A Bartholin's cyst or abscess is a common condition. The openings of Bartholin glands become obstructed, causing fluid to back up and glands became swollen (Bartholin's cyst). If the fluid becomes infected, that leads to the collection of pus surrounded by inflamed tissue, and an abscess develops. Swollen glands may be painless or, if infected, may become tender with a painful lump. Treatment of a Bartholin's cyst ranges from good personal hygiene to surgical drainage and antibiotics for infected cysts.

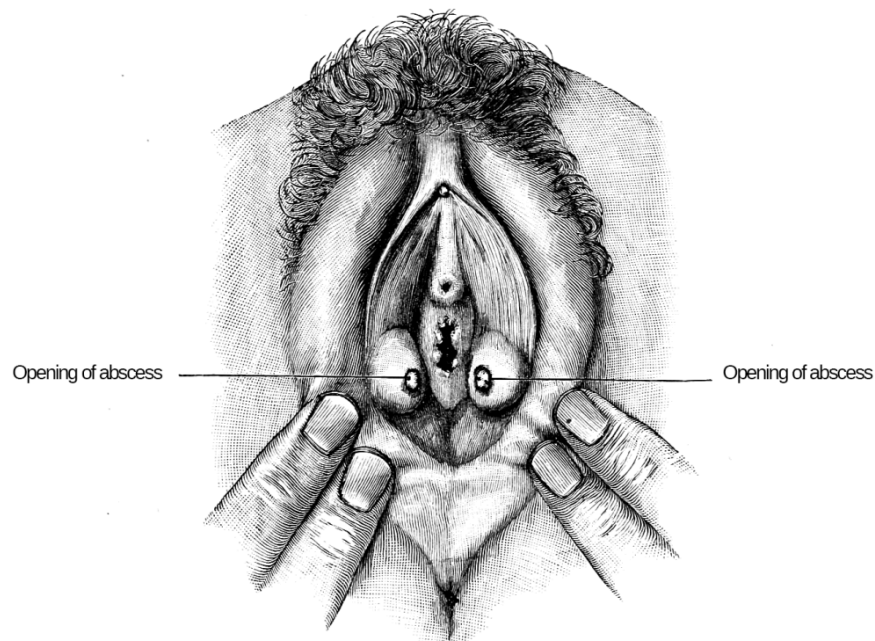


Figure 5. Bartholin's cyst.

Episiotomy

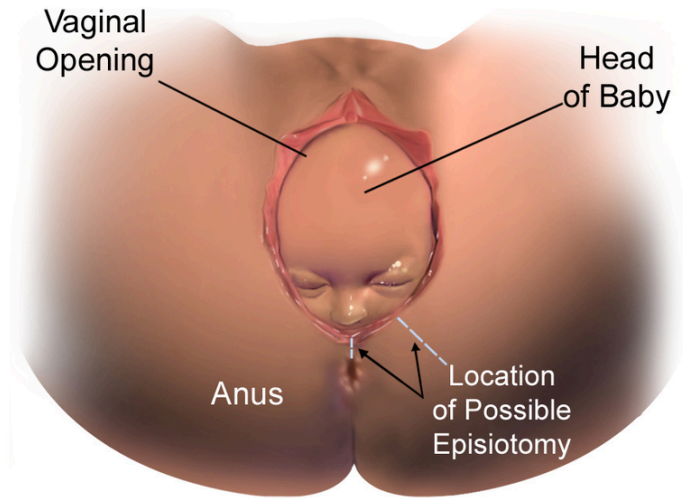


Figure 6. Possible location of episiotomy.

During vaginal childbirth, a significant stretching of the vaginal canal and the perineum occurs, and a potential natural tear of the perineum may happen. **Episiotomy**, an incision made in the perineum between the vaginal opening and the anus, could be made during childbirth to prevent perineal tearing (Figures 6 and 7). Two types of episiotomy incisions could be done:

- A **midline** (median) incision, a vertical cut. This type of incision is intended to be easily repairable but carries a higher risk of extending into the anal area and potentially resulting in fecal incontinence.
- A **mediolateral** incision, an angled cut. While this incision tends to be more painful and somewhat more challenging to repair, it offers greater protection against an extended tear involving the anal area.

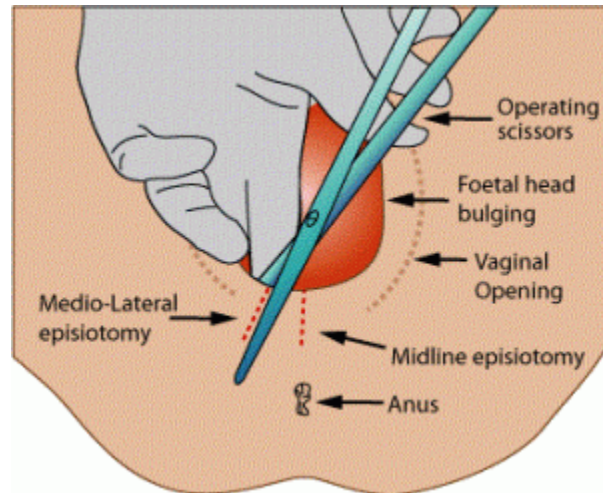


Figure 7. Episiotomy incisions.

Episiotomy was previously done as a routine part of vaginal birth; however, recently it is only done as needed.

Take Home Message

- Female external genitalia are collectively called the vulva. They consist of the mons pubis, labia majora and minora, vestibule, and its component.
- Episiotomy is a planned surgical incision to widen the perineal during vaginal delivery.
- Bartholin glands' secretions moisten the vestibular area and help lubrication at sexual intercourse.

Image Sources

- **Figure 1.** “Labeled muscles of the perineum” is adapted from [OpenStaxAnatomy & Physiology](#), licensed [CC BY 4.0](#). Access for free at [OpenStax College online](#).
- **Figure 2.** “Female perineum” is from [Bruce Blaus via Wikimedia Commons](#), licensed [CC BY SA 4.0](#).
- **Figure 3.** “The Vulva The external female genitalia” is from [OpenStaxAnatomy & Physiology](#), licensed [CC BY 4.0](#). Access for free at [OpenStax College online](#)
- **Figure 4.** “Hymen membrane placement” is from [FollowTheMedia via Wikimedia Commons](#), licensed [CC BY SA 3.0](#).

- **Figure 5.** “Batholin’s cyst” is from Ernest, [Diseases of Women](#). Public domain.
- **Figure 6.** “Possible location of episiotomy” is from [Bruce Blaus via Wikimedia Commons](#), licensed [CC BY 3.0](#).
- **Figure 7.** “Episiotomy incisions” is from [Jeremy Kemp via Wikimedia Commons](#). Public domain.

Female Internal Genitalia

Ovaries

The **ovaries** are the female gonads (Figure 1), paired oval organs. Each is 2 to 3 cm in length and about the size of an almond. The ovaries are located within the pelvic cavity embedded in the posterior surface of the broad ligament of the uterus. They are supported by the mesovarium, an extension of the peritoneum that is continuous with the outer ovaries. The ovary itself is attached to the uterus via the ovarian ligament. Extending from the mesovarium is the suspensory ligament that connects the ovary to the lateral pelvic wall and contains the ovarian blood and lymph vessels. Loose, elongated ligaments or conditions that may lead to ligament twisting, could cut off blood supply to the ovary, pain, and necrosis of the ovarian cells (Ovarian Torsion).

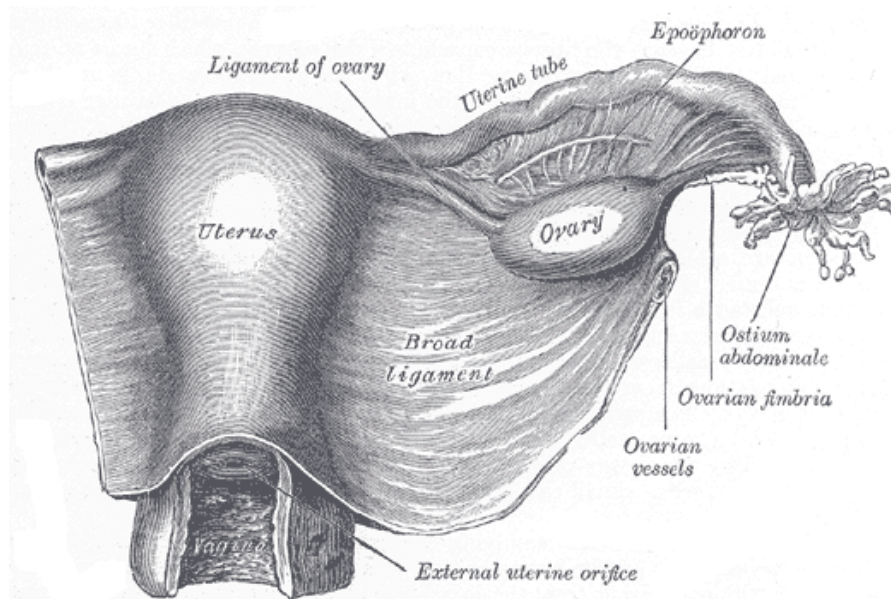


Figure 1. Uterus and right broad ligament.

The ovary comprises an outer covering of simple cuboidal epithelium called the **germinal epithelium**. Deep to the ovarian surface epithelium, a dense connective tissue covering called the **tunica albuginea**. Beneath the tunica albuginea is the cortex, the outer portion of the ovary. The ovarian cortex is composed of thousands of **ovarian follicles**. Each ovarian follicle consists of an **oocyte** surrounded by surrounded stromal cells (**follicle cells** or **granulosa cells**). Beneath the cortex lies the inner ovarian medulla, the site of blood vessels, lymph vessels, and the nerves of the ovary.

Follicular development and maturation (Folliculogenesis)

The process of follicular growth and maturation is called **folliculogenesis** (Figure 2), which typically leads to the ovulation of one follicle approximately every 28 days, along with death to multiple other follicles.

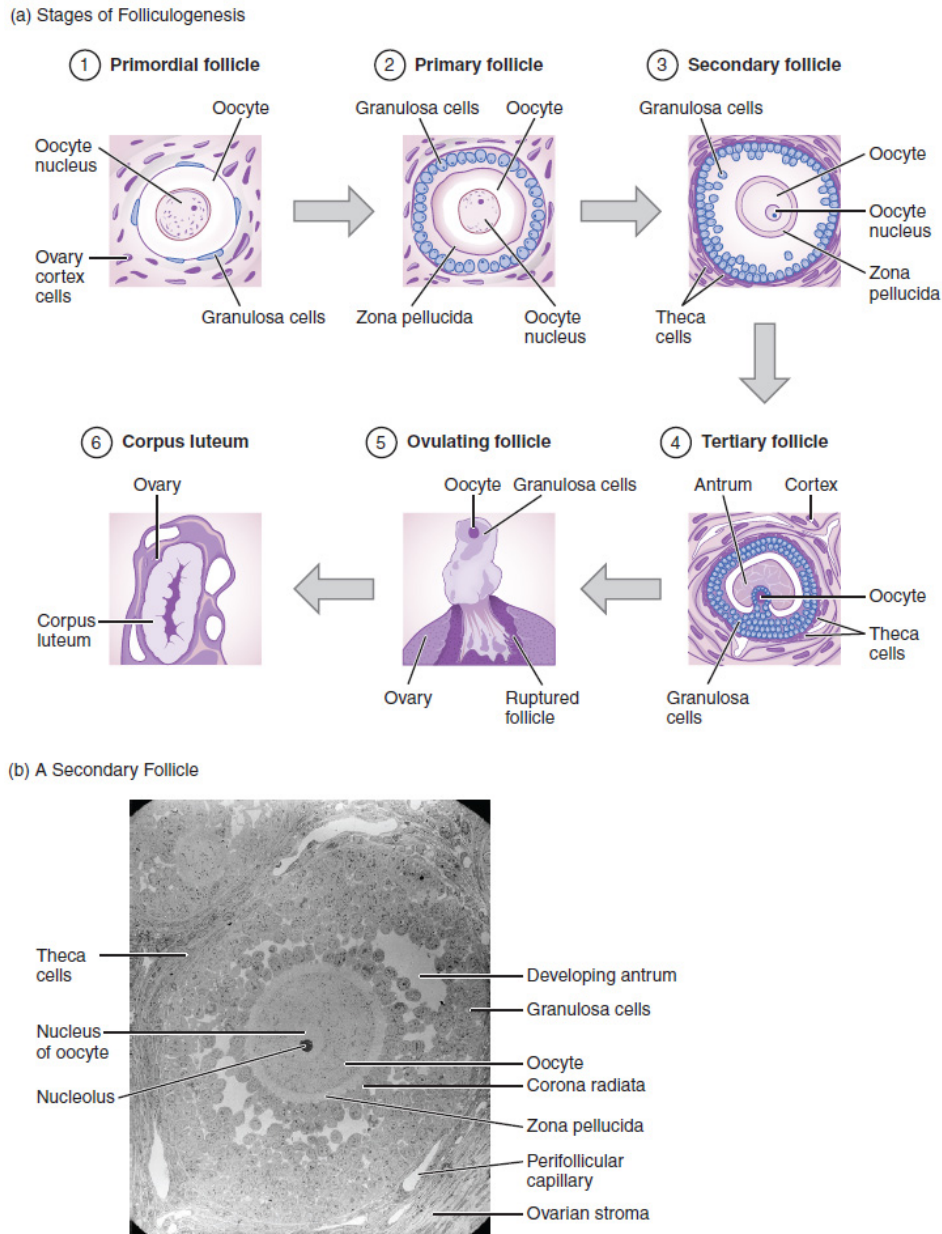


Figure 2. Folliculogenesis (a) The maturation of a follicle is shown in a clockwise direction proceeding from the primordial follicles. (b) In this electron micrograph of a secondary follicle, the oocyte, theca cells (thecae folliculi), and developing antrum are clearly visible. EM × 1100.

The death of ovarian follicles is called atresia and can occur at any point during follicular development. At birth, a female infant will have half a million oocytes within her ovarian follicles, and this number declines throughout life until menopause, when no follicles remain. Follicle maturation is under the effect of FSH and goes through a few stages of development. It progresses from resting primordial, to primary, to secondary and tertiary stages where ovulation occurs. The oocyte inside the follicle remains as a primary oocyte, arrested at prophase I of the first stage of meiosis until right before ovulation.

At birth, all the follicles in newborn females are small primordial follicles, a primitive type of ovarian follicle, and consists of a **primary oocyte** surrounded by a single layer of **flattened** stromal cells (Granulosa cells).

Around puberty, a few primordial follicles will respond to a recruitment signal each day through FSH hormone and join a pool of immature growing follicles. The single-layer granulosa cells become active, and transition from a flat or squamous shape to a rounded, cuboidal shape as they increase in size and proliferate, and the follicles change to **primary follicles**.

As FSH levels increase, the follicles continue to grow. The granulosa cells continue to divide, adding many layers of granulosa cells and the follicles increase in diameter, now called **secondary follicles**. The follicles still contain a **primary oocyte**, surrounded by **many layers** of follicle granulosa cells. Within the growing secondary follicle, the primary oocyte now secretes a thin acellular membrane called the zona pellucida that will play a critical role in fertilization. Two protective structures that surround the primary oocyte are developed, the zona pellucida and several layers of granulosa cells surround the oocyte, corona radiata. Several fluid-filled spaces start to develop, and the formation of the antrum begins. The fluid-filled spaces increase in volume as the follicles mature. A new outer layer of connective tissue, blood vessels, and **theca cells start to develop at the periphery of the follicles** — theca cells work with the granulosa cells to produce estrogens.

The thick fluid between the granulosa cells begins to collect into one large pool, and a well-developed **antrum** develops. A well-developed Theca cells layer is located at the periphery of the follicles. Follicles in which the antrum has become large and fully formed are considered **tertiary, Mature, or Graafian follicles**. Several follicles reach the tertiary stage at the same time, and most of these will undergo atresia. The one that does not die will continue to grow and develop until ovulation.

At ovulation, FSH and LH continue to increase. LH reaches its peak and stimulates the completion of meiosis I and the beginning of the second stage of meiosis of the oocyte within the follicle. Now the tertiary follicle contains the secondary oocyte, surrounded by zona pellucida and corona radiata cells layers. LH influences the rupture of the follicles and releases the secondary oocyte and its surrounding layers. Keep in mind that most follicles don't make it to this point. In fact, roughly 99 percent of the follicles in the ovary will undergo atresia, which can occur at any stage of folliculogenesis.

If the oocyte is successfully fertilized, the resulting zygote will begin to divide into two cells, then four, and so on, as it makes its way through the uterine tube and into the uterus. There, it will implant and continue to grow. If the egg is not fertilized, it will degrade—either in the uterine tube or the uterus, where it may be shed with the next menstrual period.

After ovulation and the release of the secondary oocyte, the remaining granulosa cells multiply and form a mass of cells that are wrapped by the theca cells layer, and the follicle is now called the **corpus luteum follicle**. The corpus luteum follicle secretes **progesterone** and **estrogen**, which stimulates the growth of the uterine endometrium and supports the fertilized egg until the placenta is developed. 14 days after ovulation, if fertilization has not happened, degeneration of the granulosa cells will occur and the cells will be replaced by fibrous connective tissue. The follicle is then called **corpus albicans**.

Take home Message

- All follicles at birth are primordial follicles, with the effect of FSH hormone many follicles grow, few reach maturation and the rest die. Usually, one ruptures at the time of ovulation.
- A Tertiary mature follicle is large in diameter, containing a secondary oocyte, large antrum, and well-developed theca cell layer.
- The peak of LH hormones leads to the rupture of mature follicles at ovulation and releases the secondary oocyte and the surrounding zona pellucida and corona radiata.

Image Sources

- **Figure 1.** “Broad ligament” is from [Gray’s Anatomy](#). Public domain.
- **Figure 2.** “Folliculogenesis” is from [OpenStax Anatomy & Physiology 2E](#), licensed [CC BY 4.0](#). Access for free at <https://openstax.org/books/anatomy-and-physiology-2e/pages/1-introduction> (Micrograph provided by the Regents of University of Michigan Medical School © 2012)

Uterine Tubes

The **uterine tubes** (also called fallopian tubes or oviducts) serve as the conduit of the oocyte from the ovary to the uterus (Figure 1). Each tube is 10–12 centimeters in length and covered by the mesosalpinx, part of the broad ligament.

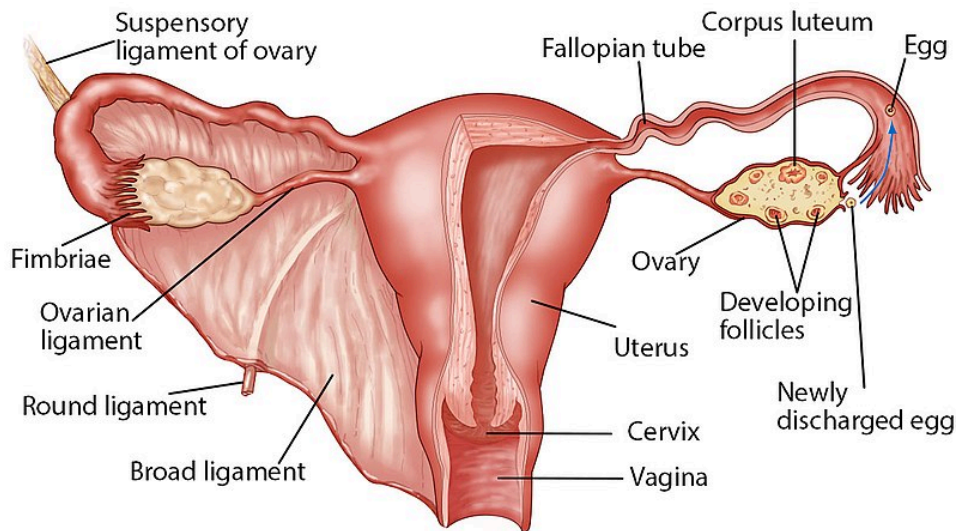


Figure 1. Labeled ovary and fallopian tubes.

Each of the two uterine tubes is close to, but not directly connected to, the ovary and divided into sections. The lateral distal opening close to the ovary is the **infundibulum**. The infundibulum flares out with slender, finger-like projections called **fimbriae**, which capture the released oocyte. Medial to the infundibulum is an extended tube, a region called the **ampulla**, where fertilization often occurs. Medial to the ampulla is a narrow straight segment, about 1/3 of the entire length of the uterine tube, called the **isthmus**. The most medial narrow segment of the tubes (**interstitial segment**) runs through the uterine wall and is continuous with the uterine cavity.

The wall of the uterine tubes consists of three layers:

1. an inner epithelial lining mucosa, which facing the lumen of the tubes,
2. a middle smooth muscle layer (muscularis mucosa), responsible for peristalsis and rhythmic contraction of the tubes and movement of the released or fertilized egg, and
3. an outer serosa layer, connective tissue, covered by peritoneal membrane and the mesosalpinx.

The epithelial lining mucosa consists of two types of cells. **Ciliated columnar epithelial cells** beat in the direction of the uterus and produce a current that will be critical to moving the oocyte/fertilized egg, and **secretory (peg cells) non-ciliated cells** provide nourishment and protect the released oocytes or the fertilized embryo.

It usually takes the fertilized egg approximately three days of to travel the length of the uterine tube and reach the lumen of the uterus. Delay in movement may lead to early implantation and ectopic pregnancy.

Function of the Fallopian Tubes

Following ovulation, the secondary oocyte, surrounded by zona pellucida and a few granulosa cells corona radiata, is released into the peritoneal cavity. The nearby uterine tube, either left or right, receives the oocyte. Unlike sperm, oocytes lack flagella and cannot move on their own. High concentrations of estrogen that occur around the time of ovulation induce contractions of the smooth muscle along the length of the uterine tube. These contractions occur every 4 to 8 seconds, and the result is a coordinated movement that sweeps the surface of the ovary and the pelvic cavity, capturing the released egg by the fimbria. Current flowing toward the uterus is generated by coordinated beating of the cilia that line the outside and lumen of the length of the uterine tube. These cilia beat more strongly in response to the high estrogen concentrations that occur around the time of ovulation. As a result of these mechanisms, the oocyte-granulosa cell complex is pulled into the interior of the tube. Once inside, the muscular contractions and beating cilia move the oocyte slowly toward the uterus. When fertilization does occur, the sperm typically meet the egg while it is still moving through the ampulla.

Clinical Correlation

Sepsis and Infertility

The open-ended structure of the uterine tubes can have significant health consequences if bacteria or other contagions enter through the vagina and move through the uterus, into the tubes, and then into the pelvic cavity. If left unchecked, this bacterial infection (**sepsis**) could quickly become life-threatening.

Cause of infection (Sepsis)

The spread of an infection in this manner is of special concern when unskilled practitioners perform abortions in non-sterile conditions. Sepsis is also associated with sexually transmitted bacterial infections, especially gonorrhea and chlamydia. These STIs increase a woman's risk for pelvic

inflammatory disease (PID), an infection of the uterine tubes or other reproductive organs. Even when resolved, PID can leave scar tissue in the tubes, leading to infertility.

Take Home Message

- The ampulla is the proper place for fertilization to occur.
- Ciliated cells lining the uterine tubes propel the egg in one direction toward uterine cavity.
- The peritoneal cavity is open in females through the open end of the uterine tubes, and can lead to infection and sepsis.

Image Sources

- **Figure 1.** “Labeled ovary and fallopian tubes” is from [Zealthy via Wikimedia Commons](#), licensed [CC BY 4.0](#).

Uterus and Uterine Cervix

The **uterus** is a pear-shaped, thick-walled muscular organ within the pelvic cavity that nourishes and supports the growing embryo (Figure 1). Its average size is approximately 5 cm wide by 7 cm long (approximately 2 in by 3 in) when a female is not pregnant, and it possesses a lumen that is continuous with the uterine tubes.

Uterus has four sections. The portion of the uterus superior to the opening of the uterine tubes is called the **fundus**. The middle section of the uterus is called the **body of the uterus** (or corpus). The **cervix** is the narrow inferior portion of the uterus that projects into the vagina. The **isthmus** is a constricted segment 1 cm long between the body and cervix, which is the preferred site for surgical delivery by cesarean section.

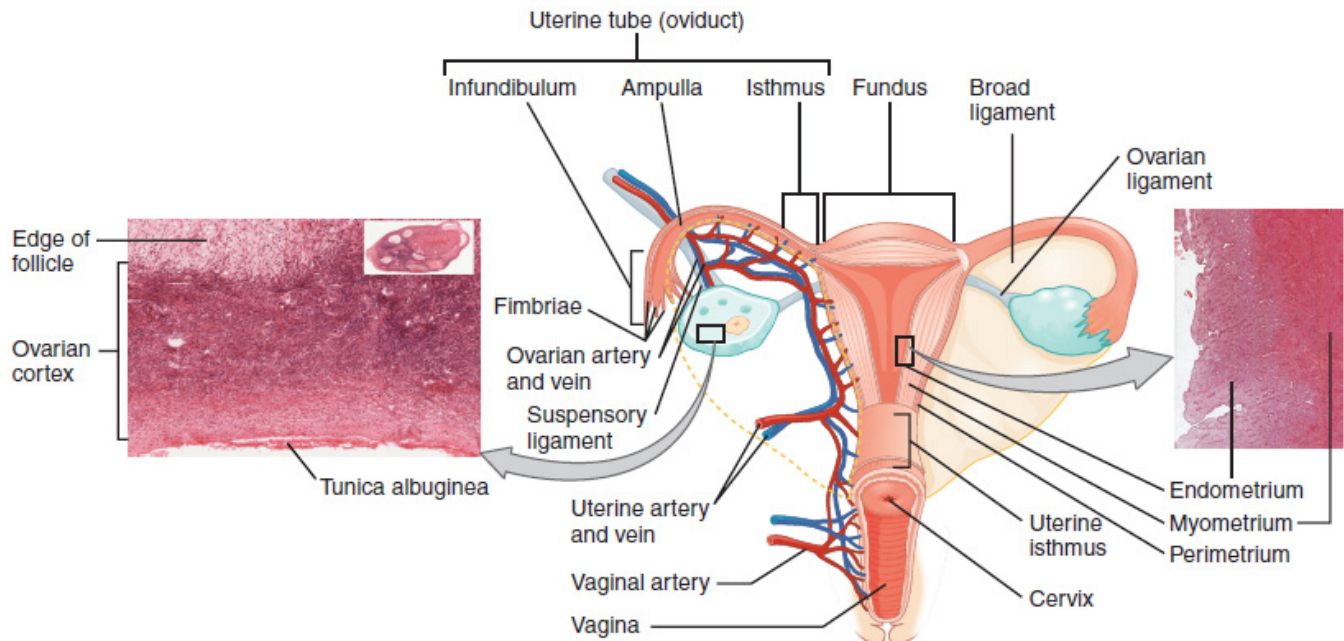


Figure 1. This anterior view shows the relationship of the ovaries, uterine tubes (oviducts), and uterus. Sperm enter through the vagina, and fertilization of an ovulated oocyte usually occurs in the ampulla region of the uterine tube. LM \times 400, LM \times 20.

Uterine position

The uterus is normally located between the rectum and urinary bladder, superior to the vagina and angled antero-superior across the superior surface of the urinary bladder, a position referred to as **anteverted** (Figure 2).

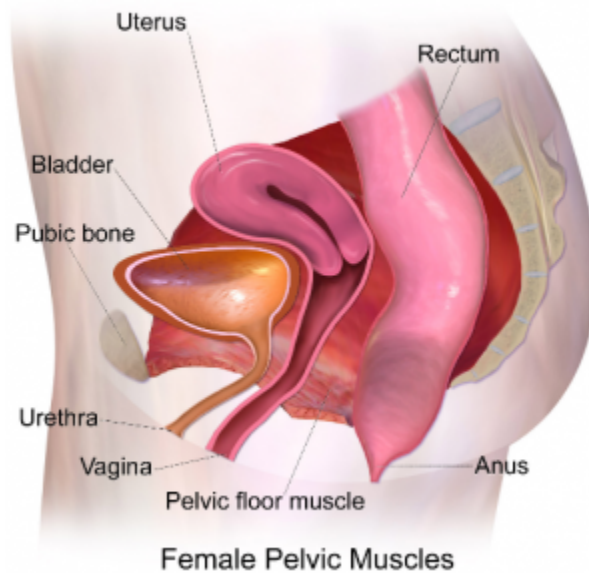


Figure 2. A medical illustration depicting the anteverted uterus.

Support of the Uterus

Several ligaments (Figure 3) maintain the position of the uterus position within the abdominopelvic cavity:

1. The **broad ligament**, a fold of peritoneum, serves as a primary support for the uterus, extending laterally from both sides of the uterus and attaching it to the pelvic wall.
2. The **round ligament**, a rope-like band of connective tissue, attaches to the uterus near the uterine tubes and extends to the labia majora.
3. **Transverse ligament** (cardinal ligament), holds the cervical part of the uterus to the lateral pelvic wall. Uterine vessels run through the cardinal ligaments.
4. **Uterosacral ligament**, stabilizes the uterus posteriorly by its connection from the cervix to the sacrum.
5. The intact pelvic floor muscle, the **Levator ani muscles**, covers the external pelvis and holds the uterus in place to prevent it from dangling into the perineal region.

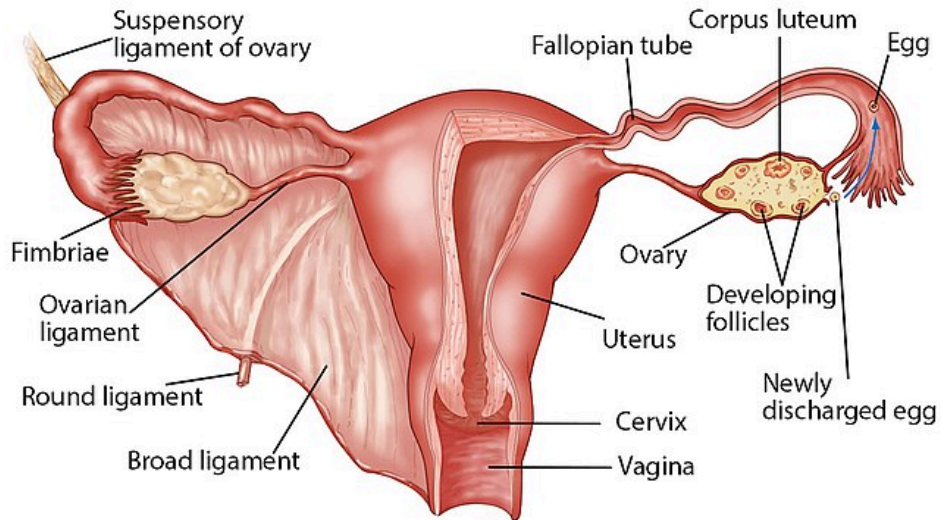


Figure 3. Uterus and its supportive ligaments.

Clinical Correlation

Back Pain

During the menstrual cycle or growing fetus in pregnancy leads to pain in the lower back, usually referred to as overstretching of the uterosacral ligament and increasing the pressure over the sacrum.

Retro-verted Uterus

When the uterus is tilted posteriorly toward the rectum instead of facing forward, this is called a retro-verted position. Individuals with a retro-verted uterus may not have any symptoms at all, or they may experience back pain during menstruation (**Dysmenorrhea**) or pain during sexual intercourse (**Dyspareunia**). Pregnancy could proceed normally; however, a retroverted uterus can be associated with infertility, though other possible causes of infertility should be ruled out first.

Uterine Prolapse

Weakness of the uterine support muscles and ligaments may lead to protrusion of the uterus through the vagina, uterine prolapse (Figure 4). Prolapse may be mild with no symptoms, or it may lead to discomfort and severe symptoms that interfere with daily life.

Symptoms of uterine prolapse may include:

- A sensation of heaviness or pulling in the pelvis.
- Soft tissue protruding from the vagina.
- Urinary problems, such as urine leakage (incontinence) or urine retention.
- Trouble having a bowel movement.
- Feeling as if one is sitting on a small ball or as if something is falling out of the vagina.
- Sexual concerns, such as a sensation of looseness in the tone of one's vaginal tissue.

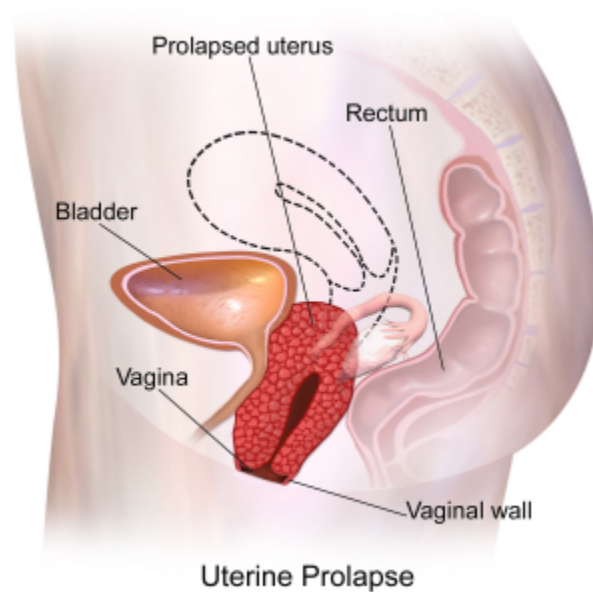


Figure 4. Uterine prolapse.

Uterine Pouches

The peritoneal folds around the uterus and various pelvic organs lead to two major dead-end recesses or pouches. The **Vesicouterine pouch**, a space between the uterus and the urinary bladder, and the **Rectouterine pouch** or (Gouglas pouch), a space between the uterus and the rectum, the most dependent point where infection and fluid might be collected.

Culdocentesis (Figure 5) is the procedure in which peritoneal fluid is obtained from the female Rectouterine pouch.

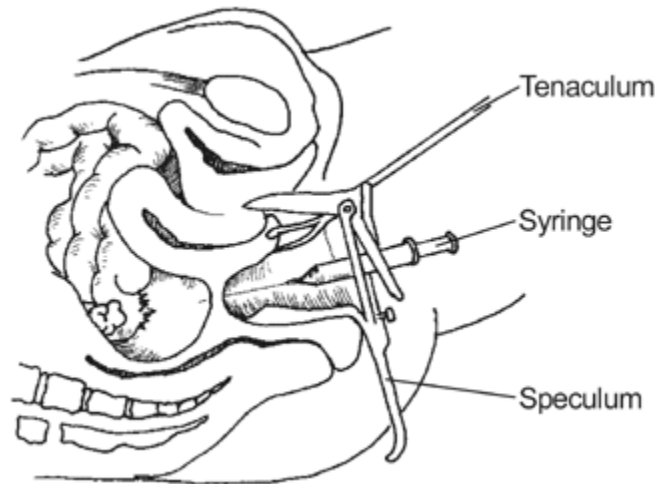


Figure 5. Culdocentesis.

This procedure involves the introduction of a needle to the posterior vaginal fornix wall to reach the Douglas pouch and aspirate the peritoneal fluid. Culdocentesis helps to collect, analyze fluid, and aid in clinical diagnosis.

The Uterine Wall

The wall of the uterus is made up of three layers (Figure 1). The most superficial layer is the serous membrane, or the **perimetrium**, which consists of epithelial tissue covering the uterus' exterior portion. The middle layer, or **myometrium**, is a thick layer of smooth muscle responsible for uterine contractions. Most of the uterus is myometrial tissue, and the muscle fibers run horizontally, vertically, and diagonally, allowing the powerful contractions that occur during labor and the less powerful contractions (or cramps) that help to expel menstrual blood during menstruation. Anteriorly directed myometrial contractions also occur near the time of ovulation and are thought to possibly facilitate the transport of sperm through the female reproductive tract.

The innermost layer of the uterus is called the **endometrium**. The endometrium contains a connective tissue lining, the lamina propria, which is covered by the epithelial tissue that lines the lumen. The endometrium consists of two layers: **the stratum basalis** (the basal layer) and the **stratum functionalis** (the functional layer).

The **stratum basalis layer** is the part of the lamina propria adjacent to the myometrium; this layer does not shed during menses. The **stratum functionalis layer** is thicker and contains the glandular portion of the lamina propria and the endothelial tissue that lines the uterine lumen. This layer grows and thickens in response to increased levels of estrogen and progesterone. In the luteal phase of the menstrual cycle,

branches off of the uterine artery called spiral arteries supply this thickened stratum functionalis. This inner functional layer provides the proper site of implantation for the fertilized egg. If fertilization did not occur, the stratum functionalis layer of the endometrium sheds during menstruation.

Uterine Vessels

The uterus gets its blood supply through the uterine artery, a branch of the internal iliac artery which runs through the **cardinal ligament**. The uterine artery supplies the myometrium and gives **straight arteries** branches that run close to the base of the endometrium to supply the stratum basale. The arteries become **spiral and more helical arteries** run along the whole length of the functionalis layer of the endometrium. Spiral arteries elongate and become tortuous with the effect of hormones and rupture and shed blood with each menstrual cycle (Figure 6).

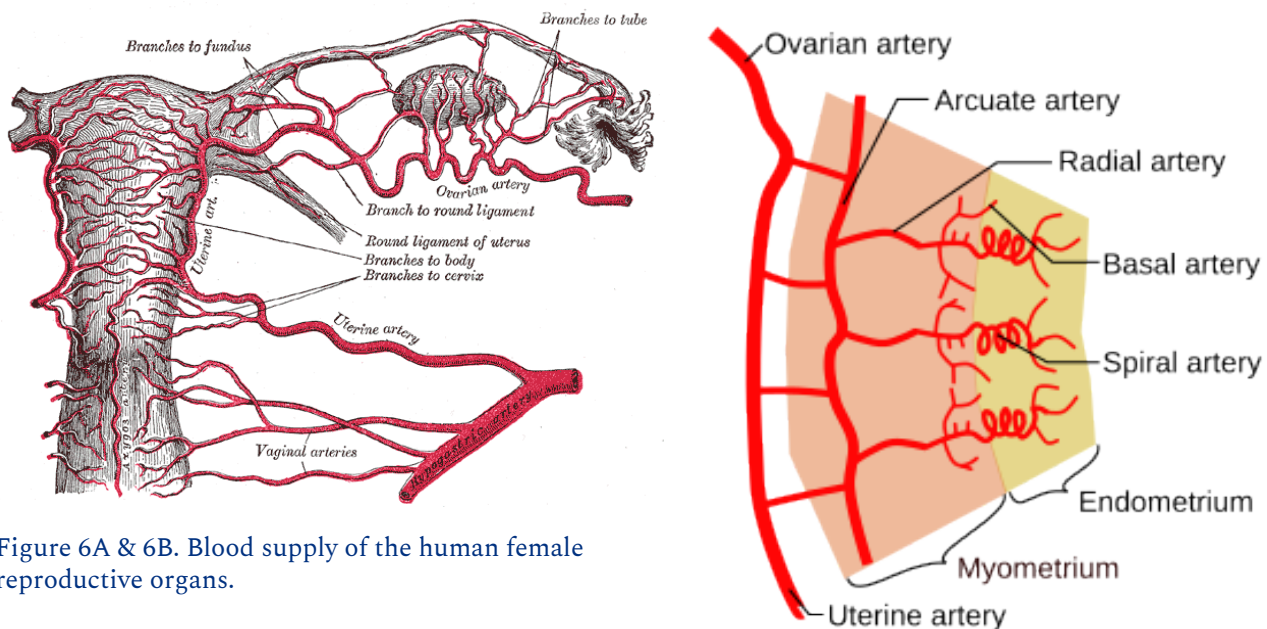


Figure 6A & 6B. Blood supply of the human female reproductive organs.

Uterine Cervix

The uterine cervix opens to the vagina through external os and the junction between the uterine cervix, the and uterine body is marked by internal os. The pathway between the internal and external *ostia* is called the cervical canal or **endocervix**. The cervical wall is thinner than the wall of the body of the uterus, with few smooth muscle layers. The portion of the uterine cervix extending into the vagina is called the **ectocervix**.

The cervical canal is lined by columnar epithelial mucosal glands that secrete thick, **mucous, acidic** secretions. These secretions fill and seal the cervical canal and form a **mucous plug**, which prevents the penetration of pathogens to the uterus. At the midpoint of the menstrual cycle, under the influence of high systemic plasma estrogen concentrations, these secretions became thin and **watery** in nature, and help to facilitate entry of sperms through the reproductive tract.

The ectocervix is lined by stratified squamous epithelia cells. During a **pap smear** (Figure 7), cells from your cervix are gently scraped away and examined to detect potentially precancerous and cancerous processes. Abnormal growth changes in the type of epithelia is a concern, and intervention is aimed at preventing the progression of disease.

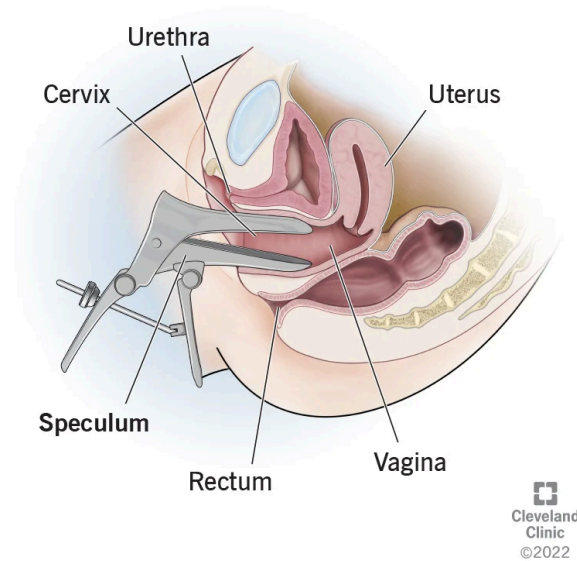


Figure 7. Pap smear.

Take Home Message

- The uterus is anteverted and its wall consists of the perimetrium, myometrium, and endometrium.
- The endometrium consists of the stratum basalis and functionalis layers.
- The uterine cervix is thinner than the body of the uterus as it has fewer smooth muscles. It is lined by mucosal glands that secrete acidic and mucous secretions, and a mucous plug.
- Changes in cervical lining mucosa taken during pap smears can detect precancerous conditions.

Image Sources

- **Figure 1.** “Ovaries, Uterine Tubes, and Uterus ” is from [OpenStax Anatomy & Physiology](#), licensed [CC BY 4.0](#). Access for free at <https://openstax.org/books/anatomy-and-physiology/pages/1-introduction> (Micrographs provided by the Regents of University of Michigan Medical School © 2012).
- **Figure 2.** “Pelvis floor” is from [Bruce Blaus via Wikimedia Commons](#), licensed [CC BY SA 4.0](#).
- **Figure 3.** “Uterus and its supportive ligaments” is from [Zealthy via Wikimedia Commons](#), licensed [CC BY SA 4.0](#).
- **Figure 4.** “Uterine prolapse” is from [Bruce Blaus via Wikimedia Commons](#), licensed [CC BY SA 4.0](#).
- **Figure 5.** “Culdocentesis” is from [Health Education to Villages](#), as allowed by their [reproduction policy](#).
- **Figure 6A.** “Blood supply of the female reproduction system” is from [Gray’s Anatomy](#). Public domain.
- **Figure 6B.** “Uterine arterial vasculature” is from [Mikael Häggström via Wikimedia Commons](#). Public domain.
- **Figure 7.** “Pap smear” is © The Cleveland Clinic. Used for educational purpose under fair use.

Vagina

The **vagina**, shown at the bottom of (Figure 1), is a muscular canal (approximately 10 cm long) that serves as the entrance to the reproductive tract. It also serves as the exit from the uterus during menses and childbirth. The superior part of the anterior and posterior vaginal wall form recess anterior and posterior fornices—called the fornix—meet the protruded uterine cervix. A needle through the posterior fornix is used clinically to access the rectovaginal pouch during culdocentesis.

The walls of the vagina are lined with an outer fibrous adventitia, a middle layer of smooth muscle, and an inner mucous membrane with transverse mucosal folds called **rugae**. The extension of mucosa centrally forms the hymen. The middle and inner layers together allow the expansion of the vagina to accommodate intercourse and childbirth.

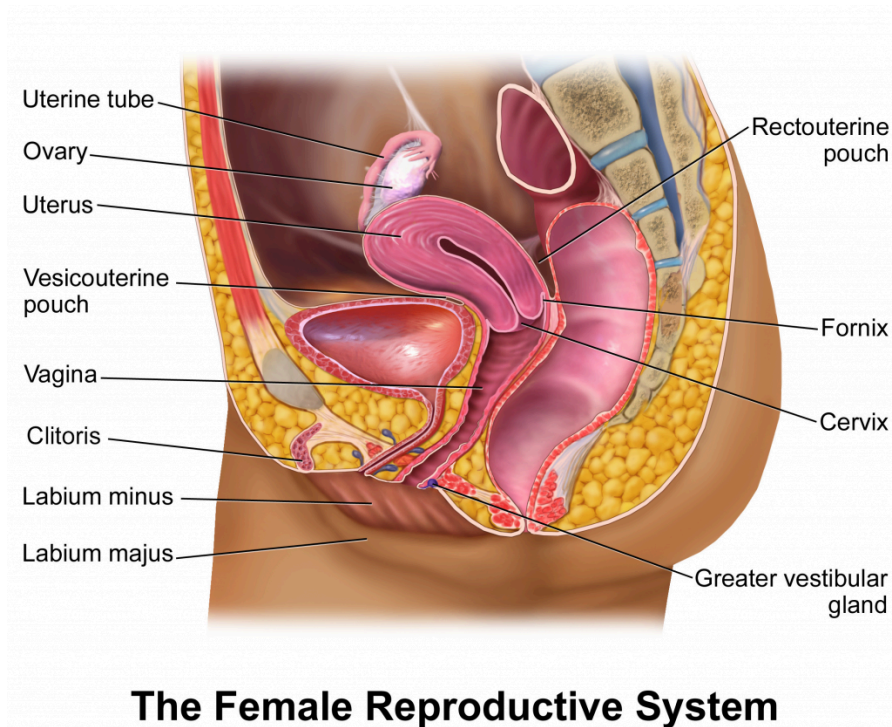


Figure 1. The female reproductive system, with major pieces labeled.

Vaginal mucosal cells are under the influence of estrogen hormones. Estrogen stimulates the cells to synthesize, store, and release **glycogen**. The vagina is considered home to a normal population of microorganisms that help protect against infection by pathogenic bacteria, yeast, or other organisms that can enter the vagina. In a healthy individual, the most predominant type of vaginal bacteria is from the genus *Lactobacillus*. This family of beneficial bacterial flora works on glycogen released by mucosal

cells and secretes lactic acid, and thus protects the vagina by maintaining an acidic pH (below 4.5). Potential pathogens are less likely to survive in these acidic conditions.

Lactic acid, in combination with other vaginal secretions, makes the vagina a self-cleansing organ. Douching—or washing out the vagina with fluid—can disrupt the normal balance of healthy microorganisms, and increases a person’s risk for infections and irritation. Indeed, the American College of Obstetricians and Gynecologists recommend that individuals do not douche and that they allow the vagina to maintain its normal healthy population of protective microbial flora.

Take Home Message

- Estrogen stimulates vaginal mucosal cells to synthesize and secrete glycogen.
- Vaginal flora lyse the released glycogen and produce an acidic environment undesirable for pathogen survival.
- Vaginal acidity minimizes the entry of pathogens into the female reproductive system.

Image Sources

- **Figure 1.** “The female reproductive system” is from [Bruce Blaus via Wikimedia Commons](#), licensed [CC BY 3.0](#).

Mammary Glands

The mammary glands (breasts) are accessory organs of the female reproductive system located in the thoracic region, far from the other female reproductive organs. The function of the breasts is to supply milk, which contains a complex mixture of proteins, fats, and sugar for infant nutrition in a process called **lactation**.

The main external feature of the breast is the nipple, a cylindrical projection on the center of the breast containing multiple openings from internal secretory ducts. The nipple is surrounded by a pinkish/brownish pigmented ring of skin called **areola** (Figure 1), whose coloration deepens during pregnancy. The areola is typically circular and can vary in size from 25 to 100 mm in diameter. The areolar region is characterized by small, raised areolar glands that secrete lubricating fluid during lactation to protect the nipple from chafing. When a baby nurses, or draws milk from the breast, the entire areolar region is taken into the mouth.

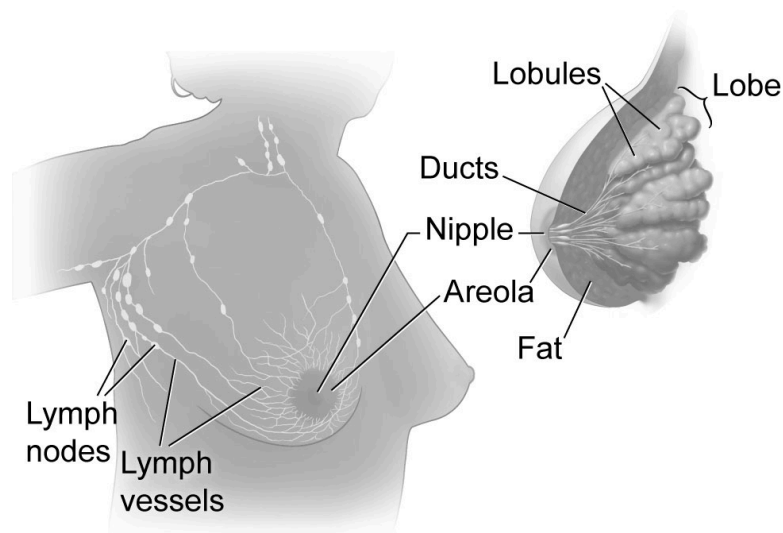


Figure 1. During lactation, milk moves from the alveoli through the lactiferous ducts to the nipple.

Breast milk is produced by the **mammary glands**, which are modified sweat glands. The milk itself exits the breast through the nipple via 15 to 20 **lactiferous ducts** that open on the surface of the nipple. These lactiferous ducts each extend to a **lactiferous sinus** that connects to a glandular lobe within the breast that contains groups of milk-secreting cells in clusters called **alveoli**. The clusters can change in size depending on the amount of milk in the alveolar lumen. Once milk is made in the alveoli, stimulated

myoepithelial cells that surround the alveoli contract to push the milk to the lactiferous sinuses. From here, the baby can draw milk through the lactiferous ducts by suckling. Prolactin hormone released from the anterior pituitary glands stimulates the process of milk synthesis. Oxytocin hormone secretion by the posterior pituitary, which is stimulated by suckling, leads to alveolus myoepithelial cells contraction and the excretion of milk out of the lactiferous ducts and sinuses.

Internally, the breast is divided into **lobes** which are further divided into **lobules**. The lobes are surrounded by fat tissue, which determines the size of the breast. Breast size differs between individuals and does not affect the amount of milk produced. Supporting the breasts are multiple bands of connective tissue called **suspensory ligaments** that connect the skin of the gland to the overlying fascia of the pectoralis major muscle.

During the normal hormonal fluctuations in the menstrual cycle, breast tissue responds to changing levels of estrogen and progesterone, which can lead to swelling and breast tenderness in some individuals, especially during the secretory phase. If pregnancy occurs, the increase in hormones leads to further development of the mammary tissue and enlargement of the breasts.

Clinical Correlation

In breast cancer, obstruction of lymphatic drainage leads to swelling and edema in breast tissue while the suspensory ligament remains roped to the skin. This will lead to changes in breast contour and or dimpling appearance, a characteristic feature in breast cancer (Figure 2).

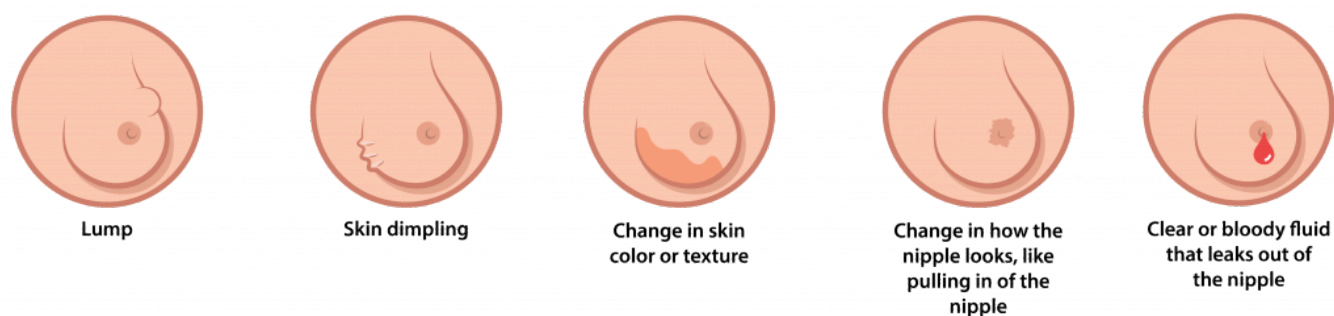

Figure 2. External signs of breast cancer.

Take Home Message

- Breasts are under the control of estrogen, progesterone, oxytocin, and prolactin hormones.

Image Sources

- **Figure 1.** “Breast anatomy” is from [US National Institutes of Health via Wikimedia Commons](#). Public domain.
- **Figure 2.** “External signs of breast cancer” is adapted from [Raphseck via Wikimedia Commons](#), licensed [CC BY SA 4.0](#).

Female Endocrinology

Hormonal Control of Reproductive Systems

Hormones are chemical substances secreted by cells within an organ, released directly to circulation and acting on a distant target (cells/organs). The human male and female reproductive cycles are controlled by the interaction of hormones from the hypothalamus and anterior pituitary with hormones from the reproductive tissues and organs of each sex. In both sexes, the hypothalamus monitors and causes the release of hormones from the pituitary gland.

When the reproductive hormone is required, the hypothalamus sends a **gonadotropin-releasing hormone (GnRH)** to the anterior pituitary. GnRH causes the release of **follicle stimulating hormone (FSH)** and **luteinizing hormone (LH)** from the anterior pituitary into the blood and stimulates gonadal function. Note that the body must reach puberty for the **adrenal glands** to release the sex hormones that must be present for GnRH to be produced. Although FSH and LH are named after their functions in female reproduction, they are produced in both sexes and play important roles in controlling reproduction.

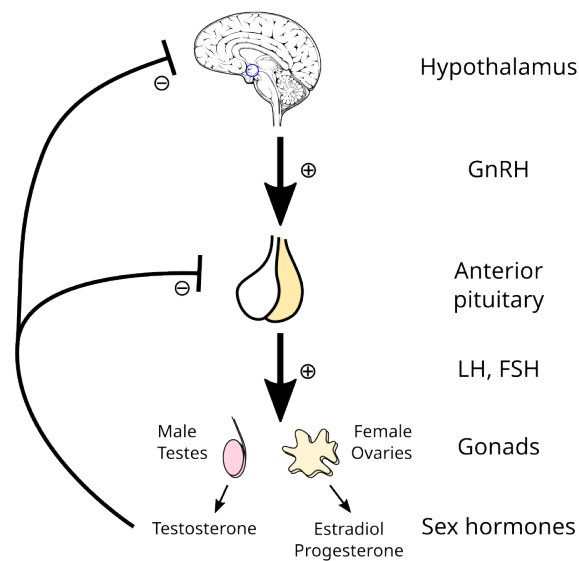


Figure 1. Relationship between hypothalamus, pituitary hormones, and gonads.

Other hormones released from the pituitary gland also have specific functions in the male and female reproductive systems. **Prolactin** hormones released from the anterior pituitary are used to measure sexual satisfaction in both sexes, with its main function focusing on mammary glands during pregnancy and lactation. Prolactin stimulates mammary gland development and milk production. **Oxytocin**

hormones are released from the posterior pituitary and stimulate the smooth muscle contraction of reproductive organs.

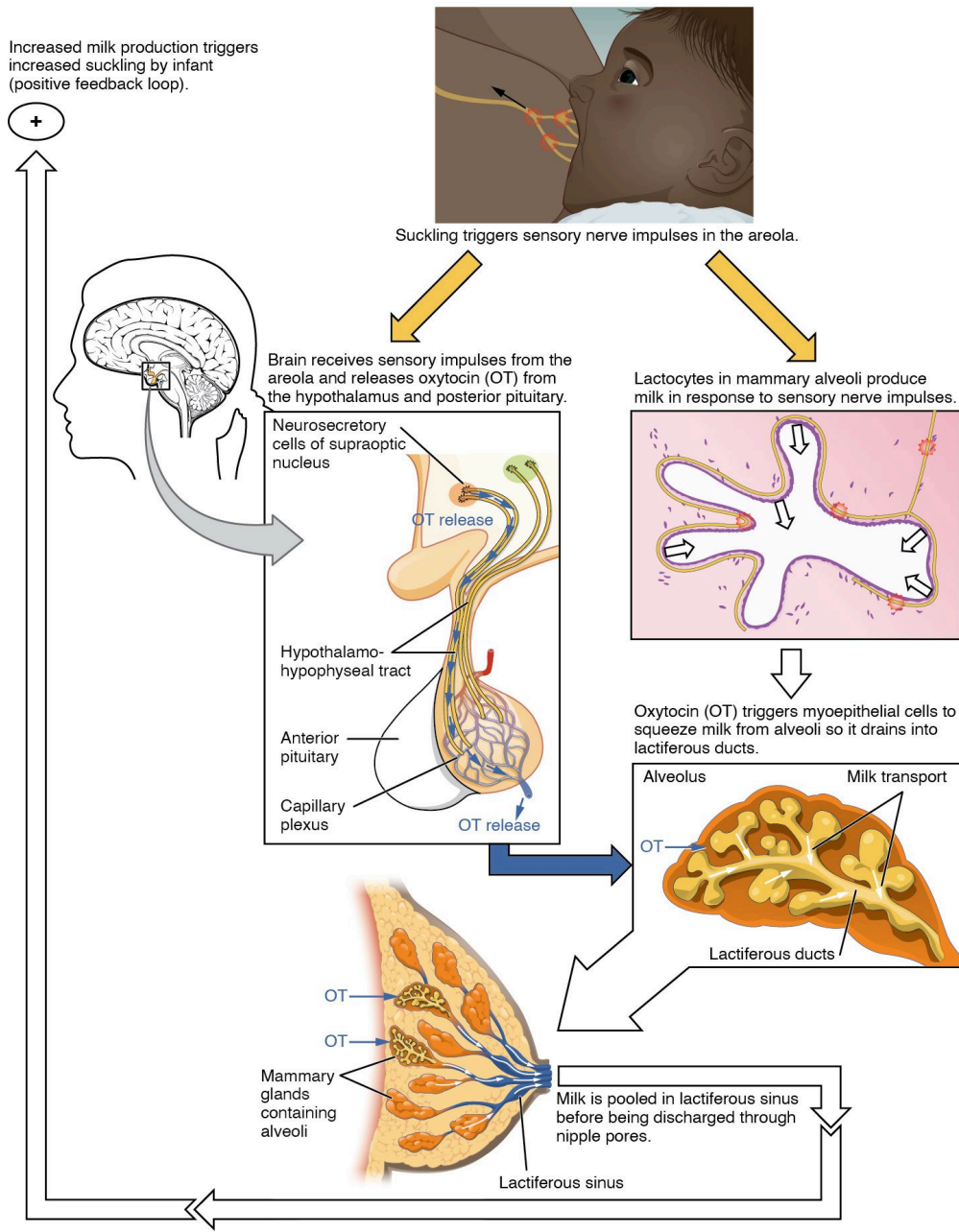


Figure 2. A positive feedback loop ensures continued milk production as long as an infant continues to breastfeed.

Take Home Message

- Adrenal gland function at puberty stimulates the hypothalamus to produce GnRH.
- GnRH released from the hypothalamus stimulates pituitary glands to produce FSH and LH, hormones that work on the Gonads.
- Prolactin and Oxytocin released by pituitary glands have an influence on the reproductive organs.

Image Sources

- **Figure 1.** “Relationship between hypothalamus, pituitary hormones, and gonads” is from [Artoria via Wikimedia Commons](#), licensed [CC BY 3.0](#).
- **Figure 2.** “Let-Down Reflex” is from [OpenStax Anatomy & Physiology 2E](#), licensed [CC BY 4.0](#). Access for free at [OpenStax Anatomy and Physiology 2E online](#).

Hormones of the Menstrual Cycle

The hormonal control of reproduction in females is complex, requiring the maturation of the hypothalamo-hypophyseal axis, the connection between the hypothalamus and pituitary gland.

The hypothalamus stimulates the **pulsatile** release of **GnRH**, which stimulates **LH** and **FSH** release from anterior pituitary. FSH stimulates the development of egg cells, called ova, which develop in structures called follicles. Follicle cells produce estrogen and inhibin, which inhibits FSH production. LH also plays a role in the development of ova, the induction of ovulation, and the stimulation of estradiol and progesterone production by the ovaries. Progesterone inhibits LH production. The maturation of the hypothalamo-hypophyseal axis typically occurs 2 years after puberty, and is associated with regular menstruation cycles.

Estrogens and progesterone are sex hormones (steroid hormones) derived from cholesterol and released from the developing ovarian follicles. **Estrogen** is the reproductive hormone in females that assists in endometrial regrowth, ovulation, and calcium absorption; it is also responsible for the secondary sexual characteristics of females. These include breast development, flaring of the hips, and a shorter period necessary for bone maturation. **Progesterone** assists in endometrial growth and complete endometrial layer maturation, and inhibition of FSH and LH release. Both estrogen and progesterone prepare the body for pregnancy and regulate the menstrual cycle.

Menstrual Cycle

The cycle consists of two parts, the ovarian and uterine cycles. **The ovarian cycle** governs the preparation of endocrine gonads and the release of eggs, while the **uterine cycle** governs the preparation and maintenance of the uterine lining. These two cycles occur concurrently and are coordinated over a 22–32-day cycle, with an average length of 28 days (Figure 1).

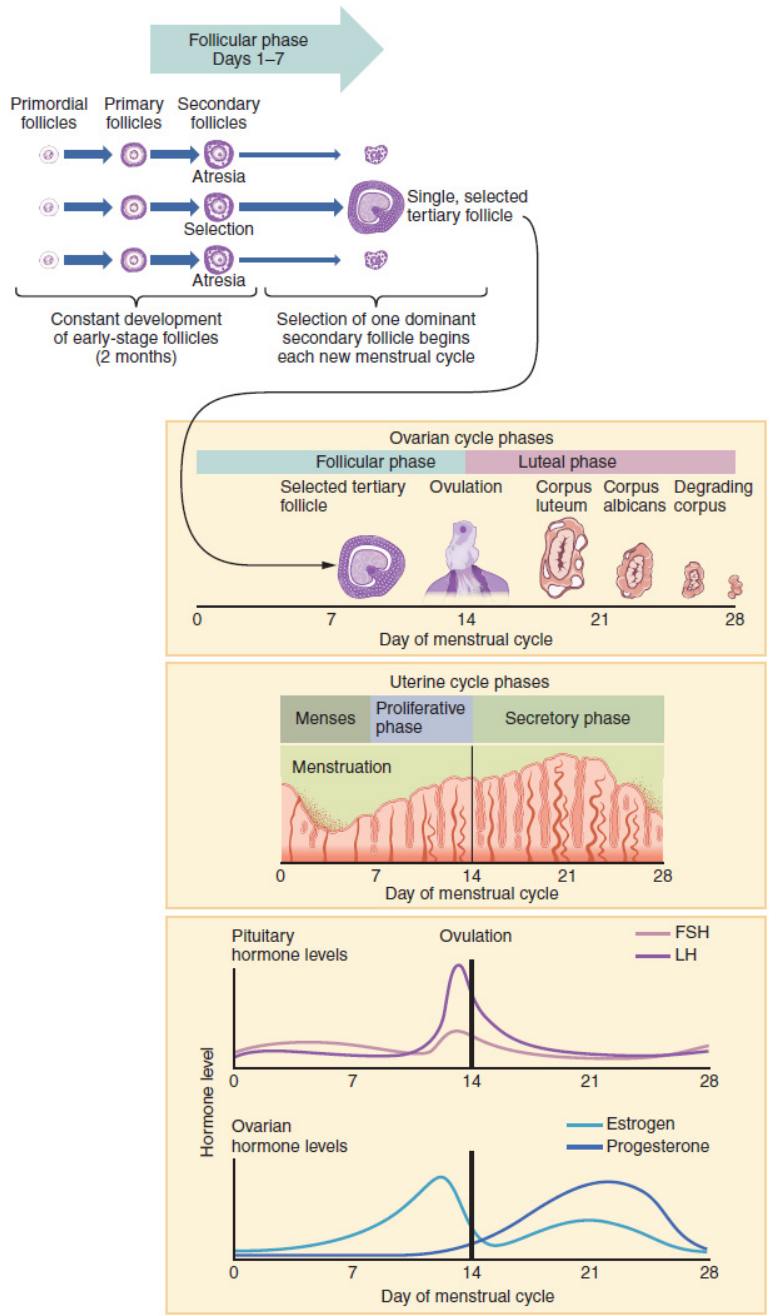


Figure 1. Hormone Levels in Ovarian and Menstrual Cycles. The correlation of the hormone levels and their effects on the female reproductive system is shown in this timeline of the ovarian and menstrual cycles.

Ovarian Cycle; Pituitary-Ovarian Hormonal Effect

Follicular phase

The follicular phase is the first phase of the ovarian cycle, preparing the egg for ovulation. The phase manifests by slowly rising levels of FSH and LH from the anterior pituitary. The release of FSH and LH causes the growth of follicles on the surface of the ovary. FSH is vital for the development and maturation of the follicles. FSH is required to synthesize theca cells at the periphery of the follicle to LH. LH then acts on the surrounding theca cells, stimulating androgen synthesis. FSH also acts on follicular granulosa cells and stimulates their uptake of androgen and the conversion of androgen into estrogen.

The continued rising of ovarian estrogen levels further increases FSH production and the growth of the follicles. Once estrogen reaches a peak and its threshold causes a negative effect at the pituitary and hypothalamus, the level of FSH drops and no more follicle maturation occurs. At the same time, the level of inhibin released from follicular cells increases, which inhibits the release of FSH from the anterior pituitary. The drop of FSH stops further maturation of the follicles.

Ovulation

The surge of estrogen secretion at this time is responsible for the mid-cycle surge of LH. A concentration of 200 pg/ml or more of estrogen is necessary to produce a positive feedback effect on LH release, and it should be sustained for about 50 hours. Ovulation occurs about 29 to 39 hours after the peak of LH. At this time, the mature follicle ruptures and releases its egg with its surrounding layers. The follicles that did not rupture degenerate, and their eggs are lost. The level of estrogen decreases when the extra follicles degenerate.

Luteal phase

After ovulation, LH stimulates corpus luteum follicle formation, and the follicular cells produce estrogen and progesterone. The increased level of progesterone drops LH at the pituitary and hypothalamic levels and prevents further ovulation, a negative feedback effect. At the same time, the release of estrogen and progesterone out of the ovary influences the development of the endometrial lining of the uterus to support pregnancy. If fertilization and pregnancy do not occur, 14 days after ovulation, the corpus luteum degenerates. A fibrous tissue corpus albicans follicle develops and progesterone levels drop. With the decreased level of progesterone, the lining of the superficial endometrial layer is sloughed off. This is the inception of menstrual bleeding, and the menstrual phase of the uterine cycle.

The Uterine Cycle

The uterine cycle consists of the menstrual, proliferative, and secretory phases. Figure 2 visually compares the ovarian and uterine cycles and Figure 1 shows the commensurate hormone levels in each.

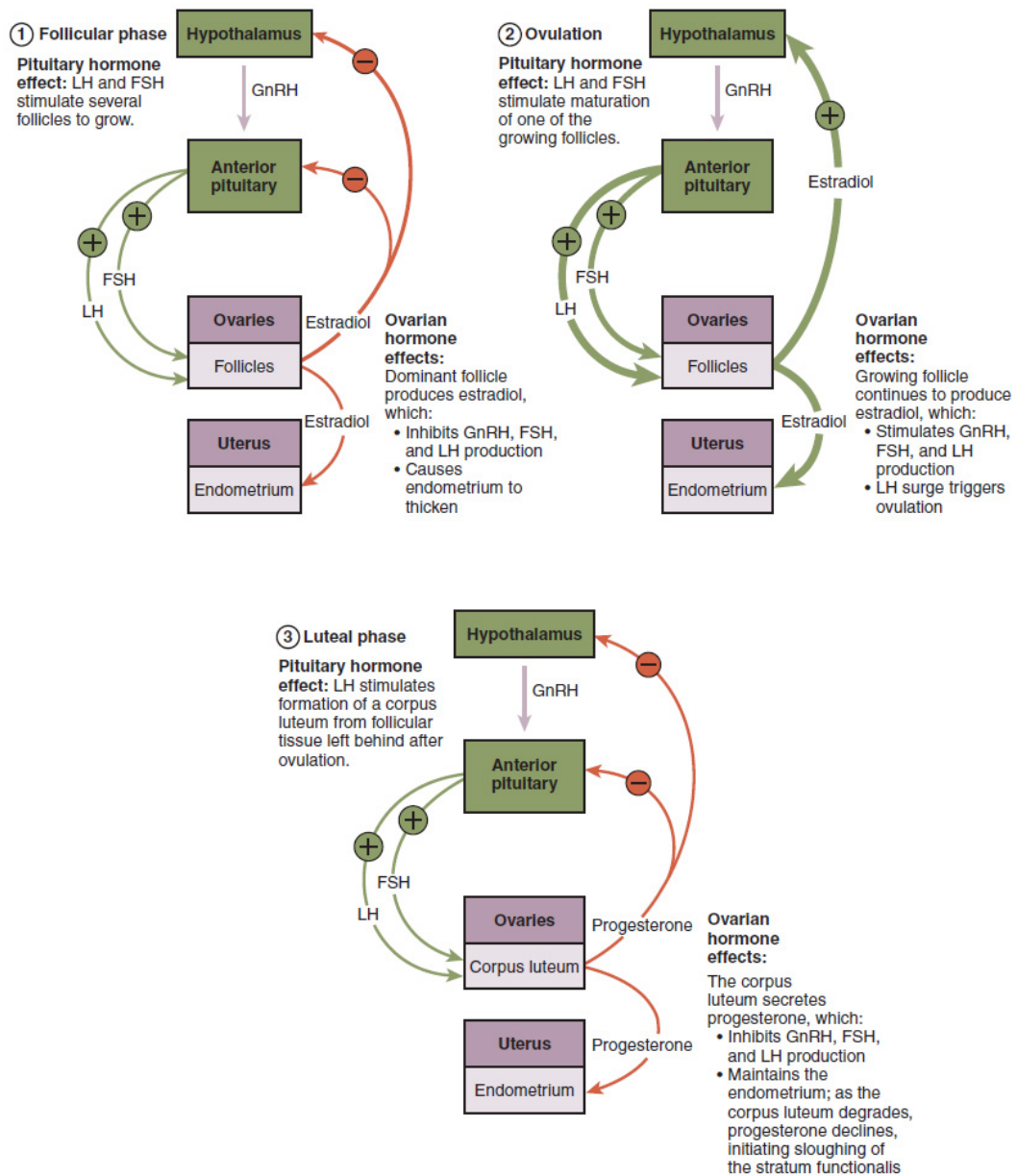


Figure 2. Hormonal action during ovarian and Uterine cycles.

Menstrual phase

High progesterone during the luteal phase stimulates the release of prostaglandin from endometrium cells. Prostaglandins are a powerful vasoconstrictor of the smooth muscle of blood vessels. If there is no fertilization, prostaglandin causes the intermittent contraction of helical (spiral) arteries and decreases blood supply to the functionalis endometrial layer. The endometrial cells become anoxic, bacteria invades the dead endometrial layer, and the superficial layer dies (necrosis).

A sudden dilatation of the helical vessels follows as the vessels rupture. Hemorrhagic discharge, which includes blood associated with sloughed off dead functionalis layer and bacteria, is released through the vagina during menstruation, also referred to as **menses**. The first menses after puberty is called **menarche**. During this process, the basal endometrial cells remain intact.

This bleeding phase takes approximately 3-5 days. After that time, estrogen levels rise and the menstrual cycle enters the proliferative phase.

Proliferative phase

The proliferative phase starts with the end of the menstrual flow from day 4 to day 14 of the menstrual cycle. The released **FSH** and **estrogen** influence the reconstruction of the functionalis layer. The endometrium begins to regrow, replacing the blood vessels and glands that deteriorated during the end of the last cycle. Endometrial epithelial cells proliferate and reach about 2-3mm in length. Endometrial glands grow and straighten. Cells are active and start glycogen accumulation. Spiral arteries lengthen but do not reach the upper third of the endometrial layer. By day 14, the functionalis layer becomes fully restored and ovulation occurs. The ovarian cycle enters its luteal phase, and the uterine cycle enters its secretory phase.

Secretory phase (Luteal phase)

The luteal phase starts on day 15-25 of the menstrual cycle. The secretory and luteal phases are under the influence of LH and progesterone. After ovulation, the cells in the follicle undergo physical changes and produce the corpus luteum. The corpus luteum produces estrogen and progesterone. Progesterone facilitates the complete construction and differentiation of the endometrial layer. Glands are hypertrophy, cells become convoluted, and glycogen and mucoid production increase within the glands. Spiral arteries elongate and extend into superficial layers. The endometrial lining reaches its full thickness of around 5mm. At this stage, the uterus is prepared to accept a fertilized egg (implantation).

Indeed, if an embryo implants, signals are sent to the corpus luteum to continue secreting progesterone

to maintain the endometrium and the pregnancy. If an embryo does not implant, no signal is sent to the corpus luteum and it degrades, ceasing progesterone production and ending the luteal phase. Without progesterone, the endometrium thins and, under the influence of prostaglandins, the spiral arteries of the endometrium constrict and rupture as menstruation occurs (initiating the next menstrual cycle). The decrease in progesterone also allows the hypothalamus to send GnRH to the anterior pituitary, releasing FSH and LH and starting the cycles again.

Clinical Correlation

Contraception and Inhibition of Ovulation

Long-term use of high concentrations of estrogen and progesterone, as with oral contraceptive pills, can lead to pituitary suppression. High estrogen levels cause a negative feedback effect on FSH, halting maturation of the follicle, while high progesterone levels causes a negative feedback effect on LH, and inhibits ovulation.

Estrogen and Endometrial hyperplasia

As estrogen is responsible for endometrial layer growth and proliferation, the building hormone, it is considered a highly mitotic hormone. Conditions with high endogenous or exogenous levels of estrogen may lead to endometrial cell hyperplasia and cancer development.

Take Home Message

- The menstrual cycle consists of ovarian and uterine cycles.
 - Ovarian granulosa cells and theca cells work together to produce estrogen under the influence of FSH and LH.
 - Theca cells are the source of ovarian androgens.
 - High progesterone stimulates endometrial cells to secrete prostaglandin, a powerful vasoconstrictor.
 - Estrogen is the building hormone that reconstructs the endometrial cells; progesterone is responsible for differentiation and full maturation of the endometrium.
-

Image Sources

- **Figure 1.** “Hormone Levels in Ovarian and Menstrual Cycles” is from [OpenStax Anatomy & Physiology 2E](#), licensed [CC BY 4.0](#). Access for free at [OpenStax Anatomy and Physiology 2E online](#).
- **Figure 2.** “Hormonal action during ovarian and Uterine cycles” is from [OpenStax Anatomy & Physiology 2E](#), licensed [CC BY 4.0](#). Access for free at [OpenStax Anatomy and Physiology 2E online](#).

Menstrual Cycle Pattern

Normal Menstrual Pattern

The onset of the menstrual cycle occurs at puberty with the establishment of the hypothalamo-pituitary axis. The first bleeding is known as **menarche** which happens two years after breast bud development. 2–3 years after menarche—and around menopause—the hypothalamic-pituitary axis is immature, and these years are usually associated with irregular an-ovulatory cycles.

The **normal ovulatory cycle pattern** occurs every 24–32 days during reproductive years. The bleeding phase lasts approximately 3–7 days, with an average 30cc of blood lost. Nearly 80% of blood loss occurs in the first two days.

Signs of an Ovulatory Cycle

- A sustained high estrogen level: 200 pg/ml or more for about 50 hours before ovulation that precedes the peak of LH hormone.
- A surge/peak of LH hormone: > 20 mIU/ml that lasts 2–3 days at the midcycle (day 14 in the 28-day cycle). Ovulation and rupture of mature follicle occurs 24–48 hours after LH peak.
- High progesterone level at the midpoint of the luteal phase: 6.525ng/ml is produced by the developed corpus luteum.
- An increase of at least 0.4°F in the luteal phase over the proliferative-phase temperature is considered normal. As the circulating progesterone elevates, it rises the basal body temperature during the luteal phase.
- A change in cervical secretion into watery discharge at the midcycle with ovulation.
- A light pinkish-reddish spotting at the time of ovulation due to the slight drop in estrogen levels.

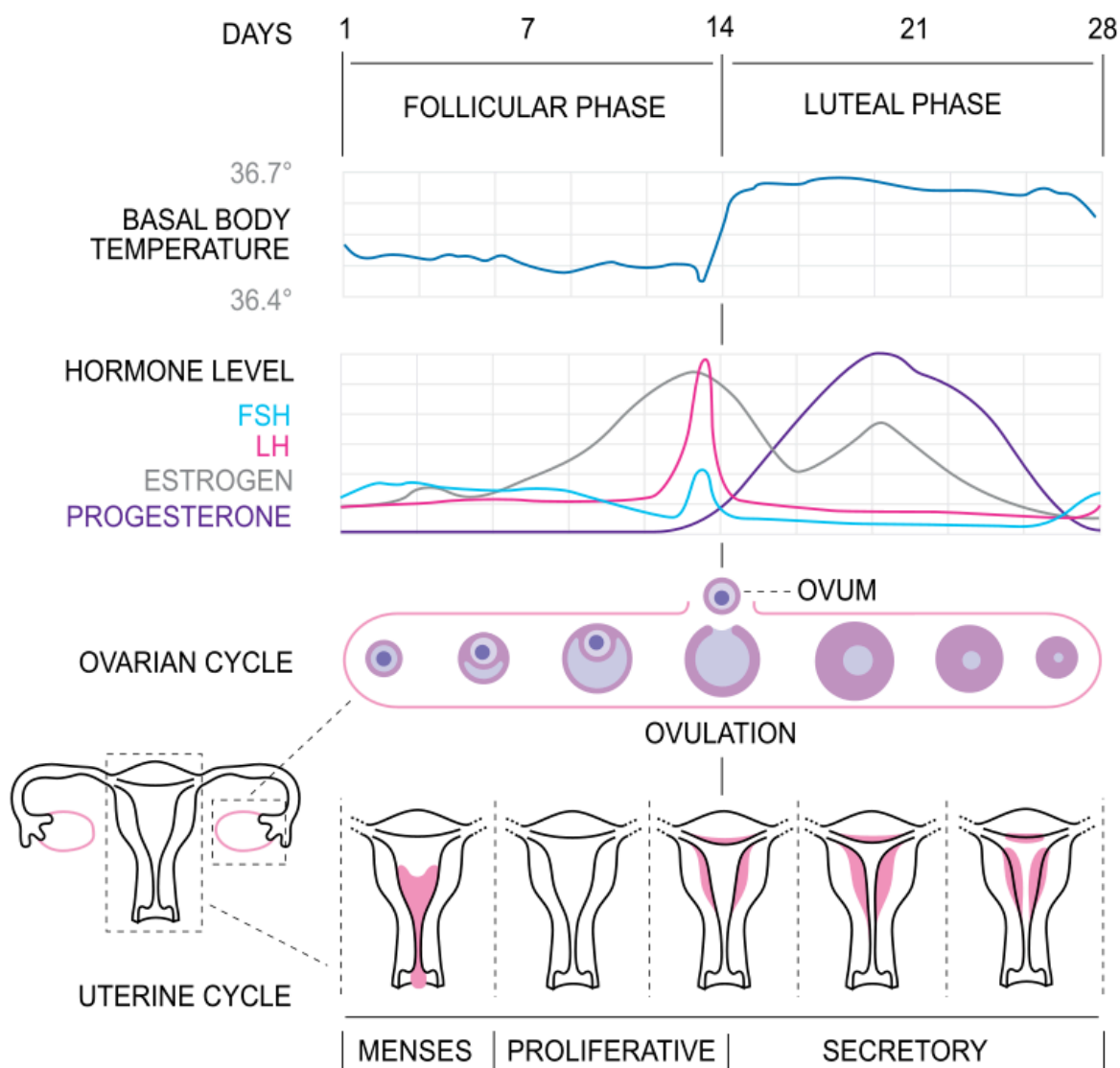


Figure 1. Menstrual cycle.

Different Patterns of Menstrual Bleeding with Ovulatory Cycles

- Infrequent bleeding that occurs at intervals greater than 35 days with prolonged cycles; A condition known as **Oligomenorrhea**, probably associated with prolonged corpus luteum activity.
- Frequent but regular episodes of uterine bleeding, usually at intervals of 21 days or less; A condition known as **Polymenorrhea**, probably due to a shortened follicular phase.
- Uterine bleeding that is excessive in amount and duration of flow is known as **Menorrhagia** (hypermenorrhagia); bleeding occurs at regular intervals during ovulatory cycles.
- Inter-menstrual bleeding: uterine bleeding occurring between regular menstrual periods- mid-

cycle spotting due to the drop in estrogen just before ovulation.

- A physiological absence of menses is known as **Amenorrhea**. This condition typically occurs during reproductive years in special situations (e.g., before or directly after menarche, pregnancy, lactation, or menopause).

Clinical Correlation

The chance of conception and occurrence of pregnancy is higher in polymenorrhea ovulatory cycles compared to oligomenorrhea ovulatory cycles due to multiple ovulations within a significant period.

Take Home Message

- The establishment of the menstrual cycle depends on the maturation of the hypothalamo-pituitary axis and the pulsatile secretion of GnRH.
- Different patterns of menstrual cycles may occur during the ovulatory cycle.

Image Sources

- **Figure 1.** “Menstrual cycle” is from [Isometrik via Wikimedia Commons](#), licensed [CC BY 3.0](#).

Menstrual Disorders

Menstrual disorders are problems related to a woman's normal menstrual cycle. They are one of the most common reasons women visit their gynecologist. Menstrual disorders and their symptoms can disrupt a woman's daily life and can also affect her ability to become pregnant.

Types of menstrual disorders

Primary Dysmenorrhea

Painful menses without evidence of an organic lesion or cause. Pain is usually brief, and worse on the first day of menstruation. Primary dysmenorrhea is usually seen in **ovulatory** menstrual cycles, typically occurs within five years of menarche, and improves with age. Over 50% of all post-pubescent women are affected and 5% are affected for 1-3 days each month. Most theories about the cause of primary dysmenorrhea center around excess **prostaglandin** around the endometrium cells. Prostaglandin is a powerful vaso-constrictive hormone that stimulates smooth muscle contraction of the myometrium, resulting in powerful uterine muscle contraction.

Treatment is usually aimed at prostaglandin inhibition or the suppression of cycles to inhibit its release. Non-specific measures like heat, mild analgesics, and exercise should be encouraged, but narcotics are not used.

Premenstrual Syndrome (PMS)

PMS is described as physical and emotional discomfort prior to menstruation, usually of unknown cause.

Symptoms include both emotional effects (depression, emotional lability) and physical effects (water retention, pain, breast tenderness). These symptoms are experienced in the **luteal phase** of the **ovulatory** cycle and become absent in the post-menstrual week. Not all premenstrual changes are considered PMS. Symptoms should be severe enough to disrupt daily life and family interactions, and/or lead to alcohol or drug abuse, or suicidal thoughts. Evaluation is usually made by carefully taken history.

Management of PMS depends on a responsive and cooperative patient who wants to get better. Sometimes exercise, vitamin B6, or antidepressants may be of value.

Abnormal Uterine Bleeding

Abnormal uterine bleeding is bleeding that is considered excessive in frequency, duration, or amount by an individual who has previous normal menstrual pattern. The bleeding is different from a woman's normal menstrual cycle, and unusual for her age. Abnormal uterine bleeding is one of the most common gynecological health issues and can have many causes.

Pregnancy-related causes

- Pregnancy or ectopic pregnancy
- Miscarriage

Non-pregnancy-related causes

- Hormonal imbalance
- Problems linked to birth control methods
- Infection of the uterus or cervix
- Uterine fibroids or polyps
- Problems with blood clotting
- Cancer of the uterus, cervix, or vagina
- Chronic medical conditions such as thyroid problems and diabetes
- Endometrial hyperplasia. Unopposed estrogen can lead to endometrial hyperplasia. Usually, a sample of the endometrial lining is recommended in those 35-years-old or older who have experienced abnormal uterine bleeding.

Amenorrhea

The absence of a normal monthly period or menstrual cycle. There are two major types of amenorrhea:

Primary amenorrhea

When a young woman has not had her first period by age 16. Possible causes include:

- Failure of the ovaries, ovarian atresia.
- Poorly formed reproductive organs.
- Problems in the nervous system or the pituitary gland and failure to initiate menstrual cycle.
- Extreme weight gain or weight loss

- Long-term illness
- Extreme exercise

Secondary amenorrhea

Defined when a woman who was previously menstruating stopped having menstrual bleeding for three months or more. This is the most common type of amenorrhea, where the endometrial lining does not shed synchronously and could occur in normal or pathological conditions.

1. **Physiological amenorrhea** is an absence of menstruation during normal physiological conditions (e.g., pregnancy, lactation, and during menopause). Usually, these conditions are associated with **physiological** hormonal changes.
2. **Pathological amenorrhea** is usually associated with **anovulation** and anovulatory cycles.
 - Conditions that interfere with the hypothalamic-pituitary axis
 - Pituitary adenoma – hyperprolactinemia
 - Stress and anxiety
 - Rapid weight loss
 - Exogenous sources of estrogen
 - Obesity: peripheral conversion of androgens to estrogen
 - Excess intake of estrogen
 - Defects in estrogen metabolism
 - thyroid and hepatic diseases

Take Home Message

- Menstrual disorders can be associated with ovulatory and non-ovulatory cycles.

The Male Reproductive System

Scrotum and Testes

The majority of the male reproductive system is external, located in the perineum region between the upper part of the two thighs. Male external genitalia include the scrotum, its contents, and the penis.

Scrotum

The scrotum is a skin-covered, highly-pigmented muscular sac containing the testes. The scrotum extends from the body behind the penis (Figure 1). This location is important in sperm production, which occurs within the testes and proceeds more efficiently when the testes are kept 2 to 4°C below core body temperature. The scrotum is homologous to the labia majora in the female during fetal development.

The **dartos** muscle is a subcutaneous smooth muscle that makes up the wall of the scrotum. It continues internally to make up the scrotal septum that divides the scrotum into two compartments, each housing one testis. Descending from the internal oblique muscle of the abdominal wall are the two **cremaster** muscles, which cover each testis like a muscular net. By contracting simultaneously, the dartos and cremaster muscles can elevate the testes in cold weather (or water), moving the testes closer to the body and decreasing the surface area of the scrotum to retain heat. Alternatively, as the environmental temperature increases, the scrotum relaxes, moving the testes farther from the body's core and increasing the scrotal surface area, which promotes heat loss. Externally, the scrotum has a raised medial thickening on the surface called the **raphe** defines the separation between the two scrotal sacs.

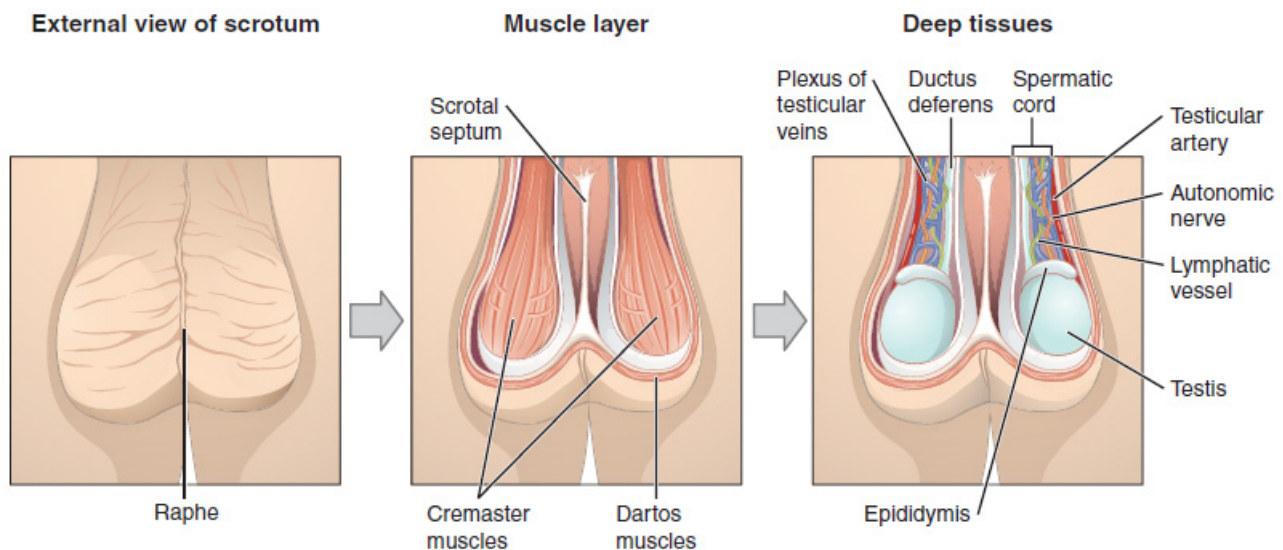


Figure 1. The Scrotum and Testes.

Spermatic Cord

The **spermatic cord** is a cord-like structure in the male reproductive system that communicates between the abdominal cavity and scrotum and transmits to the testes and genital ducts. It consists of several parts:

1. The extension of abdominal muscles forms the cremaster muscle and fascia that covers the spermatic cord.
2. The testicular artery: a branch of the abdominal aorta to supply the testes.
3. Pampiniform plexus: a network of veins surrounding the testicular artery and helps to counter current arterial heat and make sure the testes at cooler environment.
4. The Autonomic nerves: fibers that supply the genitalia.
5. Vas deference (Ductus deference): a duct that connects to the testis and carries sperm up to the ejaculatory duct in the pelvis.

Testes

The **testes** (singular = testis) are the male **gonads**, the primary sex organ in the male reproductive system. They produce both sperms, in addition to the production and secretion of androgens and the male sex hormone, testosterone. Testes are active throughout the reproductive lifespan of the male.

The testes are paired oval structures, each approximately 4 to 5 cm in length and housed within the scrotum. During fetal development, the testes develop as abdominal organs. In the seventh month of the developmental period, each testis moves to descend into the scrotal cavity. At birth, testes reach their final destination in the scrotal sacs. This process is called the “descent of the testis.”

During their migration to the scrotum, the testes are enclosed in part by the peritoneum membrane. As they descend into the scrotum, the anterior and lateral surfaces of each testis remain covered by the peritoneal membrane, the **tunica vaginalis** layer, a serous membrane that has both a parietal and a thin visceral layer of the peritoneum (Figure 2).

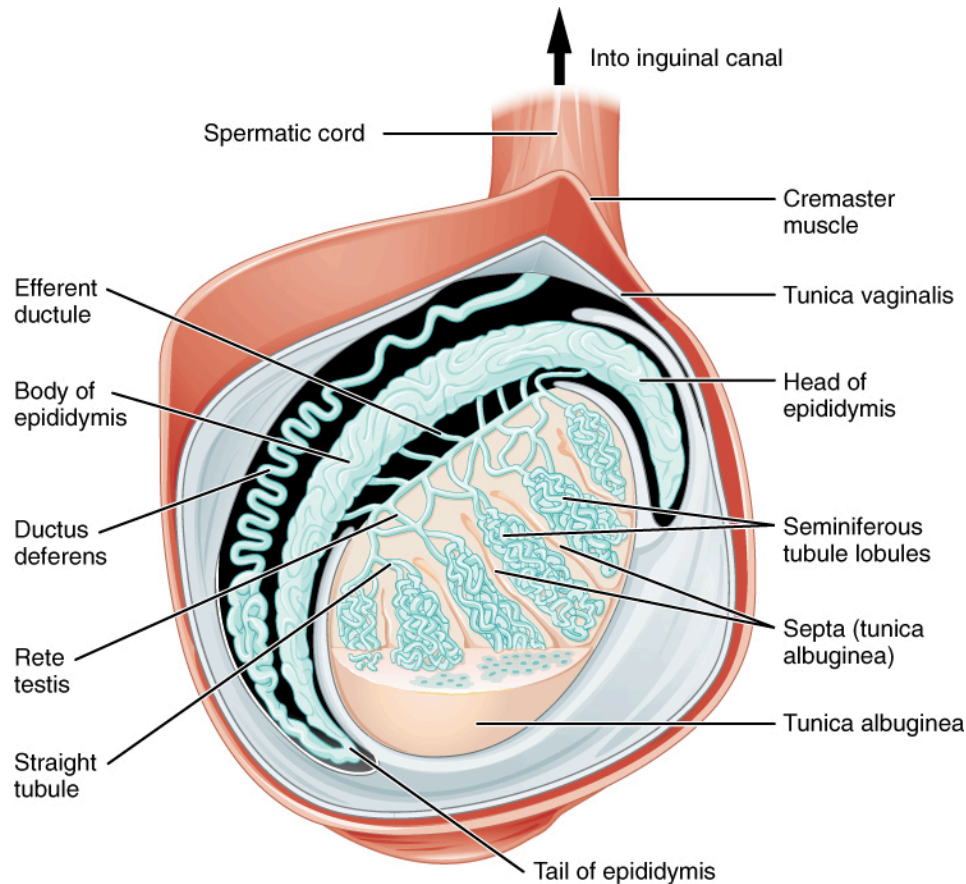


Figure 2. Anatomy of the Testis.

Clinical Correlation

Cryptorchidism

Cryptorchidism is a clinical term used when one or both of the testes fail to descend into the scrotum prior to birth. Undescended testes will lead to male infertility and inability to produce sperms, as the testes require a cooler environment for the manufacture of sperms. It may also be associated with testicular tumors. Usually, testes descend during the first year of life on their own; however, to reduce the risk, it is much better to be brought into the scrotum in infancy by a surgical procedure called orchiopexy.

Hydrocele

Fluid accumulation between the two layers of tunica vaginalis leads to swelling of the scrotum, a condition known as **hydrocele**. It is a common condition in newborns and usually disappears without

treatment by age 1. Transillumination, through shining a light through the scrotum, will show clear fluid surrounding the testes. A simple and easy diagnostic method to distinguish fluid accumulation from other causes of scrotum enlargement. Older boys and adult men can develop a hydrocele due to inflammation or injury within the scrotum.

Beneath the tunica vaginalis is the tunica albuginea, a tough, white, dense connective tissue layer covering the testis itself. Not only does the tunica albuginea cover the outside of the testis, but it also invaginates to form septa that divide the testis into lobes and lobules. Around 250 lobules are developed. Each lobule contains four convoluted **seminiferous tubules**, where sperms develop. In the posterior surface, Tunica albuginea projects deeper into the interior of the testis as the **mediastinum testis**, through which blood vessels, lymphatic vessels, and some nerves enter and leave the testis.

Seminiferous Tubules

The seminiferous tubules are the tightly coiled tubules that form the bulk of each testis. They are composed of two types of cells: the sperm developing **Spermatogenic** cells and the supporting cells known as **Sustentacular** cells (Figure 3).

Spermatogenic Cells

These are a population of dividing germ cells that continuously produce sperm beginning at **puberty**. Germ cells development progresses from the basement membrane at the perimeter of the seminiferous tubule toward its lumen.

The least mature cells, the **spermatogonia** (singular = spermatogonium), line the basement membrane inside the tubule. Spermatogonia are the stem cells of the testis, which means that they are still able to differentiate into a variety of different cell types throughout adulthood. Spermatogonia divide to produce primary and secondary spermatocytes, then spermatids, which produce formed sperm. The process that begins with spermatogonia and concludes with the production of sperm is called **spermatogenesis**.

The formed sperm are released into the duct system of the testis. Specifically, from the lumens of the seminiferous tubules to straight tubules (or tubuli recti), and from there into a fine meshwork of tubules called the rete testes. Sperms leave the rete testes, and the testis itself, through the 15 to 20 efferent ductules that cross the tunica albuginea.

Sustentacular (Sertoli Cells)

The elongated, pyramid-shaped, non-dividing supportive cells that surround all stages of the developing sperm cells are called **Sustentacular** or **Sertoli** cells. They extend physically around the germ cells from

the peripheral basement membrane of the seminiferous tubules to the lumen. They provide support and nourishment to spermatogenic cells, and phagocytose the degenerating cells during spermatogenesis.

The sustentacular cells are connected by tight, form-occluding junctions, creating a diffusion barrier called the **blood–testis barrier**. The barrier maintains a luminal environment favorable for sperm maturation. It keeps bloodborne substances from reaching the germ cells and, at the same time, keeps surface antigens on developing germ cells from escaping into the bloodstream and prompting an autoimmune response.

Under the influence of FSH, Sertoli cells also function to secrete **androgen-binding protein (ABP)** that increases the concentration of testosterone within the seminiferous tubules and facilitates the process of spermatogenesis. They also secrete **inhibin**, a hormone that controls testosterone and sperm production at the higher brain centers.

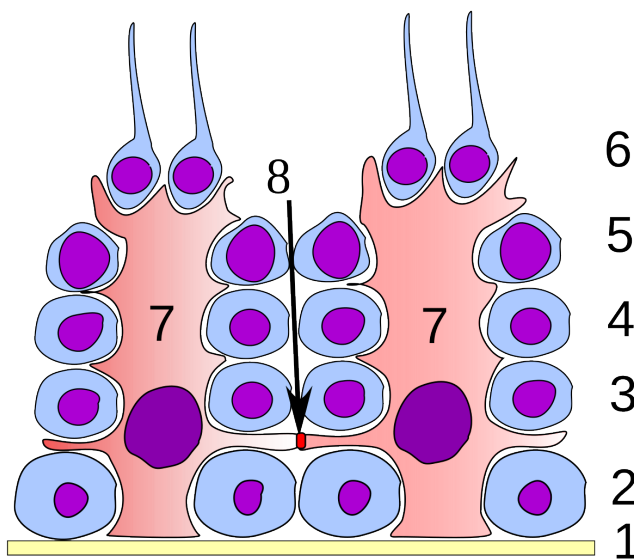


Figure 3. Spermatogenic and Sertoli cells
Germinal epithelium of the testicle.

1. basal lamina
2. spermatogonia
3. primary (1st-order) spermatocyte
4. secondary (2nd-order) spermatocyte
5. developing spermatid
6. mature spermatid
7. Sertoli cell
8. tight junction (blood-testis barrier)

Interstitial Space

Between the seminiferous tubules, there is interstitial space and tissues. Within the interstitial tissue, **interstitial** cells, also known as **Leydig** cells, are located. Leydig cells, under the influence of LH hormones, get activated and secrete testosterone (androgenic hormone), the main male sex hormone. Testosterone circulates in the blood and, once reaches its target organs, stimulates puberty. It works on skeletal muscles, causing protein synthesis and muscle enlargement. It also stimulates Growth Hormone (GH) secretion, increasing bone growth in adolescence. Testosterone is responsible for the promotion and maintenance of secondary sex characteristics. In the brain, plasma testosterone increases the sex drive. Testosterone acts at Sertoli cells and stimulates spermatogenesis and sperms production.

During fetal development, testosterone works at the Wolffian duct to promote the development of male reproductive structures.

Blood Vessels Around Testes

The testes get nourishment and oxygenated blood through the testicular artery, a direct branch of the abdominal aorta, as they develop as abdominal organs. In the spermatic cord, the testicular artery is surrounded by a group of veins, **Pampiniform plexus**, that drain waste and return deoxygenated blood back to the testicular vein in the abdomen (Figure 4). This pampiniform plexus reduces the temperature around the testes and works as a countercurrent heat-exchange system to cool down the arterial blood before it enters the testis.

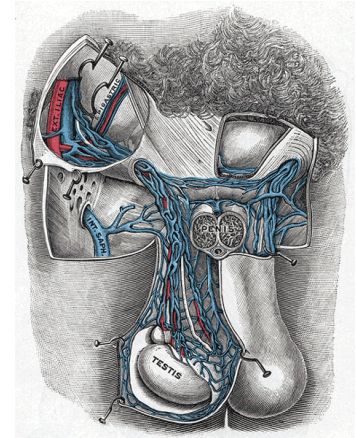


Figure 4. Testicular veins.

Clinical Correlation

Varicocele

Varicocele are enlarged dilated pampiniform plexus veins that surround the testes. The veins feel like cords or worms within the scrotal sac and may be visible on the surface of scrotum. This may be caused by an upper venous drainage obstruction in the pelvis or abdomen, which leads to the stagnation of blood around the testes, impeding their heat-regulatory system and leaving the testes in a hot environment. Varicoceles cause low sperm production and decreased sperm quality, and are a common cause of male infertility (Figure 5).

Two figures of testicles, one normal with no varicocele present and one with varicocele, inflamed veins surrounding the testicle.

Figure 5. Varicocele.

Take Home Message

- The testes are kept cooler than core body temperature within the scrotum.
- Sperms synthesize within the seminiferous tubules in the testes at the puberty.
- Leydig cells produce testosterone within the interstitial space, while Sertoli cells stimulate its uptake within the seminiferous tubules and stimulate the process of spermatogenesis.
- The blood testis barrier favors sperm maturation and prevents contact with the immune system.

Image Sources

- **Figure 1.** “The Scrotum and Testes” is from [OpenStax Anatomy & Physiology 2E](#), licensed [CC BY 4.0](#). Access for free at [OpenStax Anatomy and Physiology 2E online](#).
- **Figure 2.** “Anatomy of the Testis” is from [OpenStax Anatomy & Physiology 2E](#), licensed [CC BY 4.0](#). Access for free at [OpenStax Anatomy and Physiology 2E online](#).
- **Figure 3.** “Germinal epithelium testicle” is from [Uwe Gille via Wikimedia Commons](#), licensed [CC BY SA 3.0](#).
- **Figure 5.** “Varicocele” is © Mayo Foundation. Used here as a thumbnail image for educational purposes under fair use.

Male Reproductive Ducts

Sperms are produced within the seminiferous tubules then they transferred through the duct system, where they mature and exit the body during ejaculation. The duct system begins within the testes and ends with the urethra at the penis, where sperms are released.

The **Rete Testis** is the first duct to receive sperm from the seminiferous tubules within the testis. They are small ducts located in the posterior portion of the testis, the mediastinum testis. From the rete testis, the sperm travels to the **Efferent ducts**, larger ducts which allow the sperms to travel from the rete testis to the Epididymis.

The **Epididymis** is a convoluted set of tubing consisting of a head, body, and tail. It is here that the storage, maturation, and leaking of sperm cells occurs. The sperm that is held for ejaculation is in the tail of the epididymis. This location is incredibly important when it comes to discussions of infertility. Often, the maturation of sperm does not properly occur here and thus sperm cells are left infertile.

When the sperm cells exit the epididymal tail, they enter the **Ductus Deferens (vas deferens)**. This duct lies within the spermatic cord. When the ductus deferens reached the prostate, it enlarges, forming the ampulla. The ampulla lies at the proximal portion of the seminal vesicle, forming the ejaculatory duct.

The **ejaculatory duct** conducts sperm from the ductus deferens to the urethra.

The **Urethra** transports semen and sperms from the ejaculatory ducts to the outside of the body. There are three sections to the Urethra: the Prostatic urethra, Membranous urethra, and the Spongy (penile) urethra.

Accessory Glands

There are three glands that secrete fluids and mix with sperms to create **seminal fluid**. The secretions nourish the sperm and neutralize the acidity of the vagina. These three glands are the seminal vesicles, the prostate, and the bulbourethral glands.

Seminal Vesicles

Paired **seminal vesicles** are located on the posterior surface of the urinary bladder, lateral to the ampulla of the ductus deferens. As sperm pass through the ampulla of the ductus deferens at ejaculation, they mix with fluid from the associated **seminal vesicle** (Figure 1).

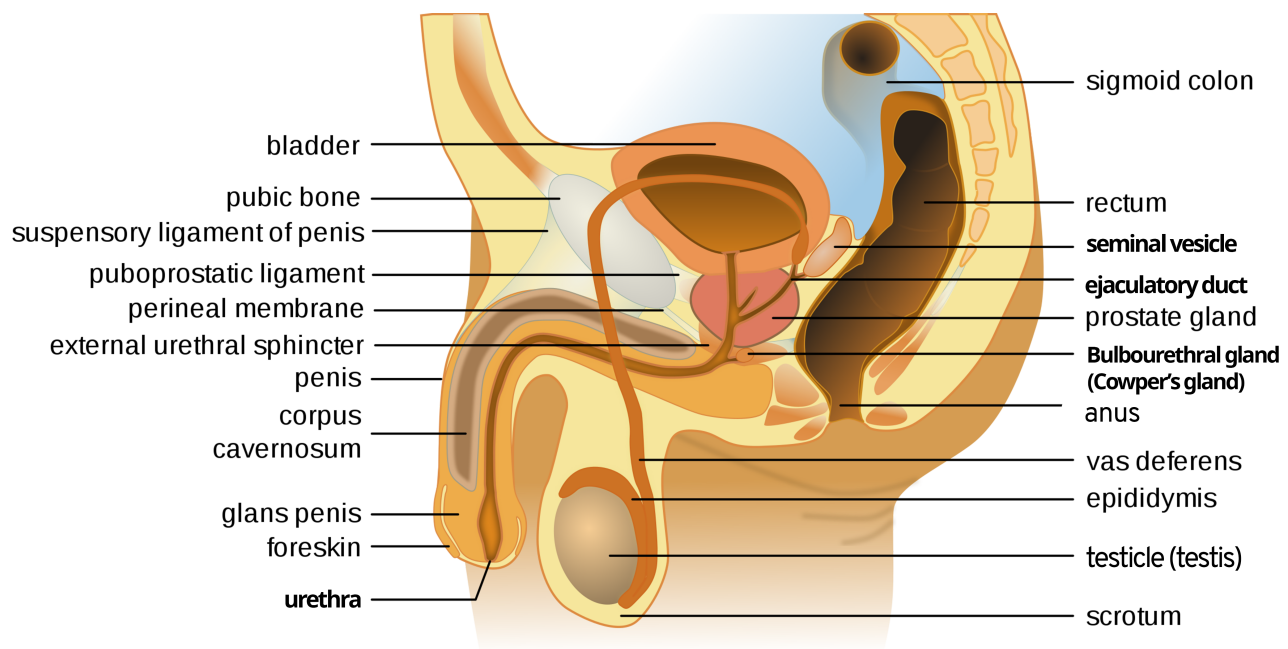


Figure 1. Bold labels highlight the placement of seminal vesicles, paired ejaculatory ducts into prostatic urethra, bulbourethral glands.

The paired seminal vesicles are glands that contribute approximately 75% of semen by volume. Seminal vesicles secrete whitish yellow, thick and **viscous** fluid. The fluid contains large amounts of fructose for the sperms' nourishment and **prostaglandins**, which are used by the sperms' mitochondria to generate ATP to allow movement through the female reproductive tract. The secretion of seminal vesicles is under the influence of **testosterone**.

The seminal fluid contains both sperm and seminal vesicle secretions. This fluid moves into the associated **ejaculatory duct**, a short structure formed from the ampulla of the ductus deferens and the duct of the seminal vesicle. The paired ejaculatory ducts transport the seminal fluid into prostatic urethra which runs through the prostate gland.

Prostate Gland

The prostate gland is a centrally located gland that sits anterior to the rectum, inferior to the bladder, and surrounding the prostatic urethra (the portion of the urethra that runs within the prostate). The gland is the size of a walnut and is formed of both muscular and glandular tissues. The glandular tissue runs in three concentric layers of 30–50 tubuloalveolar glandular tissues. The mucosal glands open directly into the urethra. The submucosal layer is larger than the mucosal and has short ducts that open into the urethra. The main mucosal glands have long ducts that open into the prostatic urethra. Prostatic secretion contributes to 20–30% of seminal fluid and is under the influence of **testosterone**. The prostate normally doubles in size during puberty. At approximately age 25, it gradually begins to enlarge again. This enlargement does not usually cause problems.

The prostatic secretion contains mucin and citric acid, providing nutrients for sperms. It is slightly **acidic** to partially neutralize the alkaline nature of seminal vesicle fluid. Prostatic secretion is rich in **prostatic-specific antigen (PSA)**, an enzyme that helps liquify the viscosity of seminal fluid and achieve good sperm mobility. The final secreted fluid in the prostatic urethra is now called semen, which helps sperms pass farther into the female reproductive tract.

Clinical Correlation

Benign prostatic hyperplasia (BPH)

Abnormal growth of the prostate or **benign prostatic hypertrophy (BPH)** is usually caused by the enlargement of the mucosal and submucosal parts of the glands that lead to constriction of the urethra as it passes through the middle of the prostate gland. Prostatic hypertrophy can cause a number of lower urinary tract symptoms, such as a frequent and intense urge to urinate, a weak stream, and a sensation that the bladder has not emptied completely. By age 60, approximately 40 percent of men have some degree of BPH. By age 80, the number of affected individuals has jumped to as many as 80 percent. Treatments for BPH attempt to relieve the pressure on the urethra so that urine can flow more normally. Mild to moderate symptoms are treated with medication, whereas severe enlargement of the prostate is treated by surgery in which a portion of the prostate tissue is removed.

Prostatic Adenocarcinoma

Prostate cancer is the second most common cancer in men. Prostatic carcinoma usually arises from the largest and outer part of the glands, the prostatic bulk, that open via long ducts to the urethra. Some forms of prostate cancer grow very slowly and thus may not ever require treatment. In contrast, aggressive forms of prostate cancer can cause metastasis to vulnerable organs like the lungs and brain. There is no link between BPH and prostate cancer, but the symptoms are similar. Prostate cancer is detected by a medical history, a blood test, and a rectal exam that allows physicians to palpate the prostate and check for **unusual nodular** masses. If a mass is detected, the cancer diagnosis is confirmed by a biopsy of the cells.

Bulbourethral Glands

The final addition to semen less than 5% is made by two **bulbourethral glands** (or Cowper's glands), Located in the urogenital diaphragm on either side of the membranous urethra. The glands release a thick, salty fluid that lubricates the end of the spongy urethra and the vagina and helps to clean urine residues from the penile urethra. The fluid from these accessory glands is released after the male becomes sexually aroused and shortly before the release of the semen. It is sometimes called **pre-ejaculate** for this reason. It is important to note that, in addition to the lubricating proteins, bulbourethral fluid can pick up sperm already present in the urethra, and therefore it may be able to cause pregnancy.

Take Home Message

- Accessory glands function under the influence of testosterone and help in the production of seminal fluids.
- Prostatic secretion neutralizes the alkaline nature of the seminal fluid.

Image Sources

- **Figure 1.** “Male anatomy svg, labeled” is from [Tsaitgaist](#) via Wikimedia Commons, licensed [CC BY 3.0](#).

Penis

The **penis** is the primary organ used for copulation (sexual intercourse) in males. It is flaccid for non-sexual actions, such as urination, and turgid and rod-like with sexual arousal. When erect, the stiffness of the organ allows it to penetrate the vagina and deposit semen into the female reproductive tract (Figure 1).

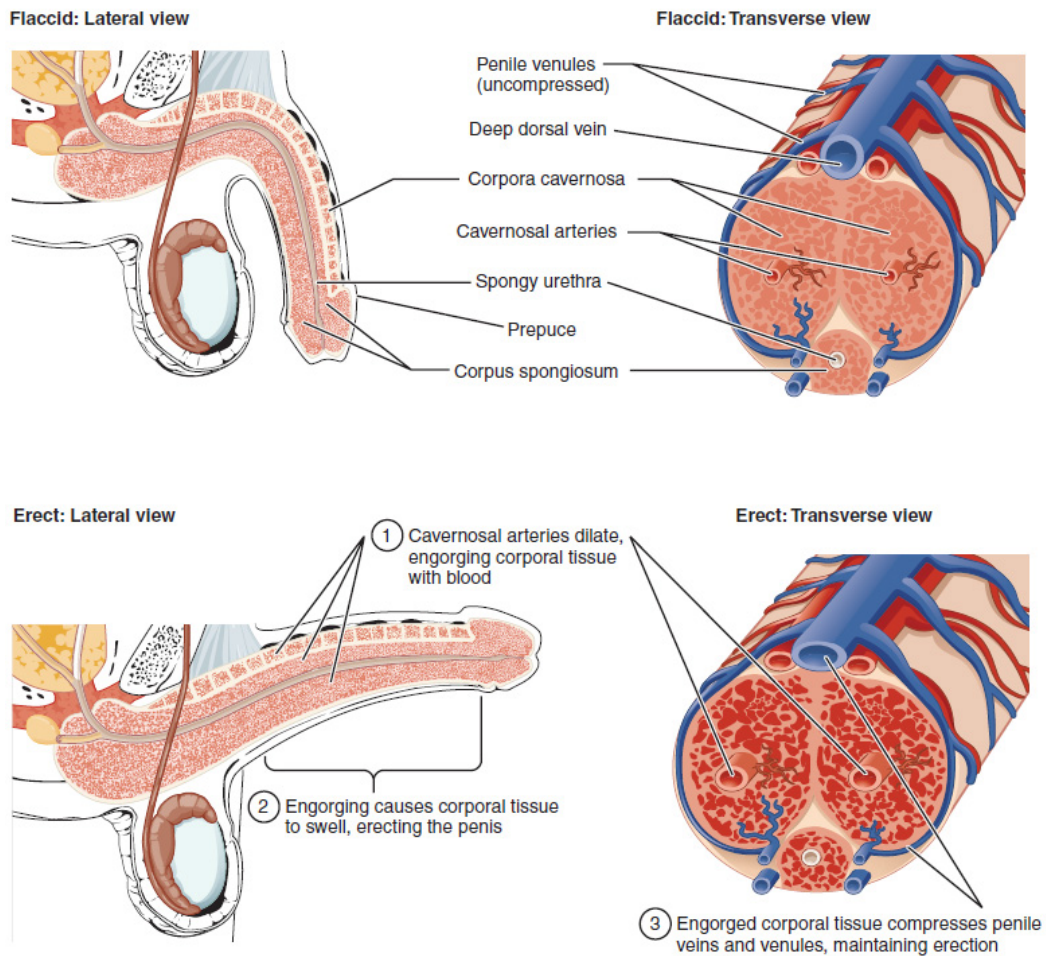


Figure 1. Penis with three chambers of erectile tissue make up most of the volume of the penis.

The attached portion of the penis at the perineum is called the **Root**, beginning directly below the bulbourethral glands. The elongated portion of the penis is known as the **shaft**. The shaft surrounds the urethra and comprises three column-like chambers of erectile tissue that span the length of the shaft. The two larger chambers, each called a **corpus cavernosum** (plural = corpora cavernosa), are located at

the dorsolateral surface of the shaft and terminate at the distal shaft of the penis. Together, these make up the bulk of the penis.

The **corpus spongiosum**, which can be felt as a raised ridge on the erect penis, is a smaller chamber located at the inferior and middle of the penis. This surrounds the spongy (penile) urethra, and continues till the end of the penis within the glans.

The end of the penis, called the **glans penis**, has a high concentration of nerve endings, resulting in very sensitive skin that influences the likelihood of ejaculation. The skin from the shaft extends down over the glans and forms a collar called the **prepuce** (or foreskin). The foreskin also contains a dense concentration of nerve endings and lubricates and protects the sensitive skin of the glans penis.

Clinical Correlation

Circumcision

A surgical procedure to remove the foreskin, prepuce, typically done within days of birth. It is often performed for religious or social reasons. Circumcision is associated with lower risk of sexually transmitted infections, including HIV. It can also decrease the risk of penile cancer and cervical cancer in sexual partners.

Erection and Ejaculation

Both erection and ejaculation are under the control of the autonomic nervous system stimulated at sexual arousal.

Sexual excitement causes parasympathetic division activation, causing erection. Penile erections are the result of congestion, or engorgement of the tissues because of more arterial blood flowing into the penis than is leaving in the veins. During sexual arousal, nitric oxide (NO) is released from nerve endings near the blood vessels within the corpora cavernosa and spongiosum. Release of NO activates a signaling pathway that results in relaxation of the smooth muscles that surround the penile arteries, causing them to dilate. This dilation increases the amount of blood that can enter the penis and induces the endothelial cells in the penile arterial walls to also secrete NO and perpetuate the vasodilation. The rapid increase in blood volume fills the erectile chambers, and the increased pressure of the filled chambers compresses the thin-walled penile venules, preventing venous drainage of the penis. This increased blood flow to the penis and reduced blood return from the penis causes an erection. Depending on the flaccid dimensions

of a penis, it can increase in size slightly or greatly during erection, with the average length of an erect penis measuring approximately 15 cm.

With continuous stimulation, the sympathetic nervous system gets activated, leading to emission and movement of semen into the urethra, followed by smooth muscle contraction of the penis, forcing semen out of the urethra and ejaculation to occur.

Medication Intake

Viagra is the trade name for a medication known as sildenafil. These pills work by augmenting the effect of nitric oxide (NO) in the body, including the penis, and are commonly prescribed for managing erectile dysfunction (ED). It's important to note that Viagra does not boost sexual desire; instead, it assists in the natural physiological process of attaining and sustaining an erection when stimulated sexually.

Take Home Message

- The penis is the male organ used for copulation.
- Parasympathetic stimulation leads to erection, while sympathetic division is responsible for ejaculation.

Image Sources

- **Figure 1.** “Cross-Sectional Anatomy of the Penis.” is from [OpenStax Anatomy & Physiology 2E](#), licensed [CC BY 4.0](#). Access for free at [OpenStax Anatomy and Physiology 2E online](#).

Ejaculate

The fluid coming from the three accessory glands combines with sperms from the testes to make **semen**. When it is released during intercourse, the semen is called **ejaculate**. The ejaculate is normally about 3-5 ml in volume and contains 200-500 million sperm. Any disturbance of semen quantity or quality will interfere with the capability of fertilization and conception. Evaluation of the semen could be done to detect sperm morphology and motility as a first line for dealing with infertility. An individual can have up to 40% abnormal sperm and still be considered fertile.

Normal Structure of Sperm

Sperm are smaller than most cells in the body; in fact, the volume of a sperm cell is 85,000 times less than that of the female gamete. Approximately 100 to 300 million sperm are produced daily, whereas women typically ovulate only one oocyte per month.

Sperm have a distinctive head, mid-piece, and tail region (Figure 1).

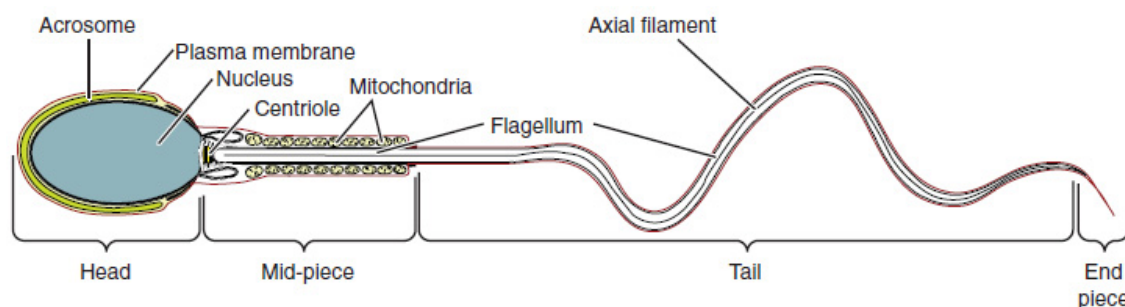


Figure 1. The sperm cell consists of a head, mid-piece, and a tail. The acrosome covers the head.

The head of the sperm contains an extremely compact nucleus with a haploid number of chromosomes and very little cytoplasm. These contribute to the overall small size of the sperm (the head is only 5mm long). A structure called the **acrosome** covers the anterior 2/3 of the nucleus at the head of the sperm cell, the “**Acrosomal cap**”. This cap is filled with lysosomal and hydrolytic enzymes that participate and initiate acrosomal reactions at the time of fertilization. The acrosomal reaction helps sperm bind and burrow through the Zona Pellucida surrounding the egg and complete the process of fertilization.

The constriction between the head and the mid-piece called the neck.

The mid-piece of the sperm contains a tightly packed **mitochondrion** that provides the ATP and energy

required for movement. The **tail**, which extends from the mid-piece, consists of a principal flagella structure around 45µm long that is highly mobile, and an end piece, a 5 µm long fibrous sheath of disorganized flagellum structure. Movement of the entire sperm cell occurs through the tail.

Clinical Correlation

Abnormal Semen Disorders

- **Aspermia** is simply the condition in which an individual cannot produce an ejaculate, while **Azoospermia** is the condition in which a male makes ejaculate, but it is completely devoid of spermatozoa.
- **Oligospermia** is when a semen sample has less than 20 million spermatozoa per milliliter of semen.
- **Teratospermia** is the condition when over half of the sperms present in the ejaculate are of abnormal shape.
- **Asthenospermia** is when over half of the sperm cells are immobile.

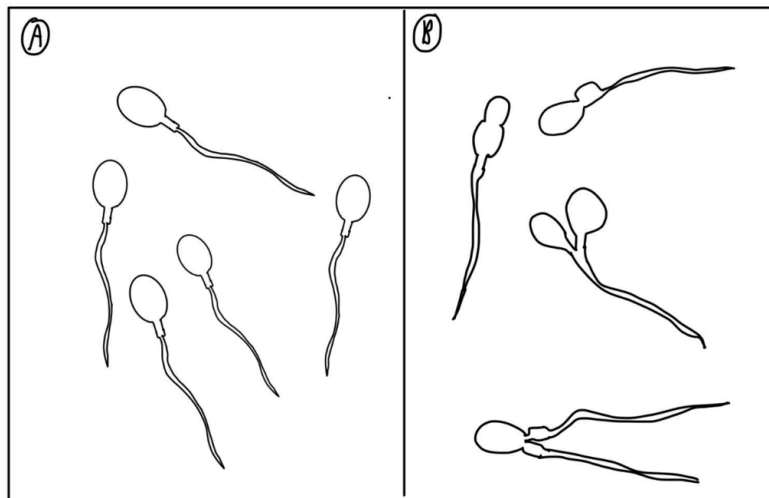


Figure 2. Normal (a) and abnormal (b) sperm morphology.

Take Home Message

- Good quantity and quality of sperms are necessary for the process of fertilization and male fertility.

Image Sources

- **Figure 1.** “The sperm cell” is from [OpenStax Anatomy & Physiology 2E](#), licensed [CC BY 4.0](#). Access for free at [OpenStax Anatomy and Physiology 2E online](#).
- **Figure 2.** “Normal (a) and abnormal (b) sperm morphology” is from [Dusdn via Wikimedia Commons](#), licensed [CC BY SA 4.0](#).

Male Endocrinology

Hormonal Regulation in the Male Reproduction

Hormonal regulation of the male body is largely connected to the endocrine glands located in the brain and Hypothalamic-Pituitary axis. The hypothalamus initiates the synthesis and secretion of Gonadotropin Releasing Hormone (GnRH). GnRH stimulates the anterior pituitary and causes the secretion of Follicle Stimulating Hormone (FSH) and Luteinizing Hormone (LH). FSH and LH hormones circulate in the bloodstream and act at the testes to produce testosterone and stimulate the process of spermatogenesis.

LH positively affects the **Leydig cells** located within the interstitial spaces between the seminiferous tubules and stimulates the cells to produce testosterone. FSH acts at **Sertoli cells** located within the seminiferous tubules and stimulates the process of spermatogenesis. FSH does this by stimulating Sertoli cells to produce **antigen binding protein (ABP)**, which leads to testosterone hormone uptake, increases its concentration within the seminiferous tubules, and initiating the production of sperms by the spermatogenic cells inside the tubules.

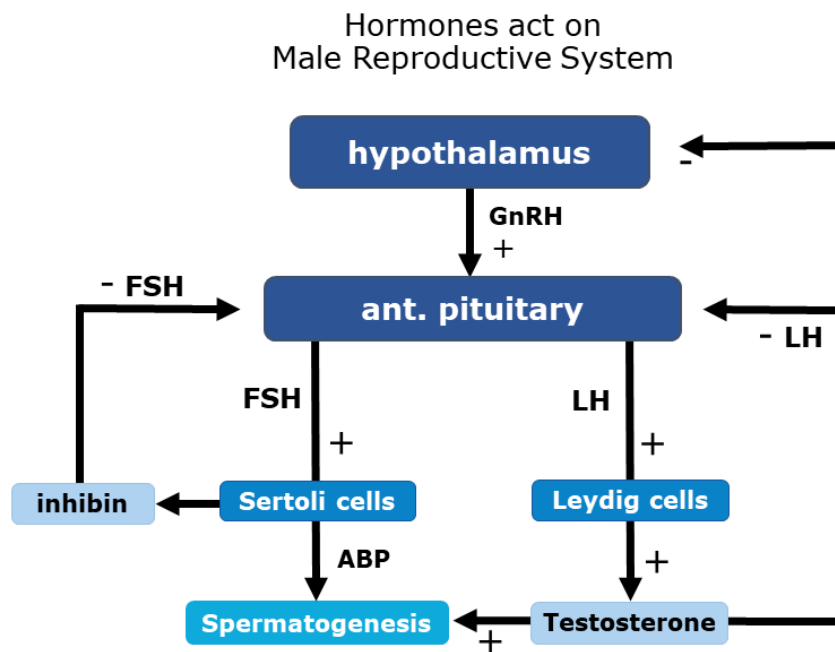


Figure 1. Hormonal control of the male reproductive system is mediated by the hypothalamus, anterior pituitary and testes.

The Effect of Testosterone

Testosterone also enters circulation and transport around the whole body, targeting many cells and organs. Once reaching skeletal muscle, testosterone increases protein synthesis and increases muscle growth. Testosterone also travels to the brain, where it boosts sexual desire and stimulates the synthesis and release of Growth Hormone (GH), supporting bone growth.

The surge in testosterone during adolescence explains why males often attain greater height than females. Along with making a taller, stronger body, testosterone plays a pivotal role in the initiation and maintenance of secondary sexual characteristics in males during puberty.

Lastly, testosterone influences male fetal development. It impacts Wolffian duct development and aids in the development of male reproduction structures during embryogenesis.

Negative Regulation of Spermatogenesis

While testosterone has many initiative properties, its excess contributes to a negative feedback effect of the hypothalamus and anterior pituitary. The excess of testosterone causes a decrease in its synthesis and secretion either directly by suppressing pituitary gland production of LH, or indirectly by participating in negative feedback on GnRH at the hypothalamus higher center.

Another hormone produced by Sertoli cells is **inhibin**. As Sertoli cells increase the production of inhibin hormone, it is not surprising that inhibin decreases the synthesis of sperms and inhibits spermatogenesis by suppressing the pituitary gland and inhibiting of FSH production.

Clinical Correlation

Some athletes use anabolic steroids to increase muscle mass and get stronger. These steroids act like natural male testosterone and could affect male reproductive organs and sperm production, as they cause hormonal imbalance and may suppress spermatogenesis by the negative hormonal effect at the higher center of the brain, hypothalamus, and pituitary glands.

Take Home Message

- Testosterone is the primary male sex hormone. It is produced by Leydig cells in testes.
- Testosterone has a negative hormonal action at the hypothalamus and pituitary gland.

Stages of Life

Puberty

Puberty is the stage of development at which individuals become sexually mature. Though the outcomes of puberty for males and females are very different, the hormonal control of the process is very similar. In addition, though the timing of these events varies between individuals, the sequence of changes that occur is predictable for male and female adolescents. Figure 1 shows a concerted release of hormones from the hypothalamus (GnRH), the anterior pituitary (LH and FSH), and the gonads (either testosterone or estrogen) is responsible for the maturation of the reproductive systems and the development of **secondary sex characteristics**, which are physical changes that serve auxiliary roles in reproduction.

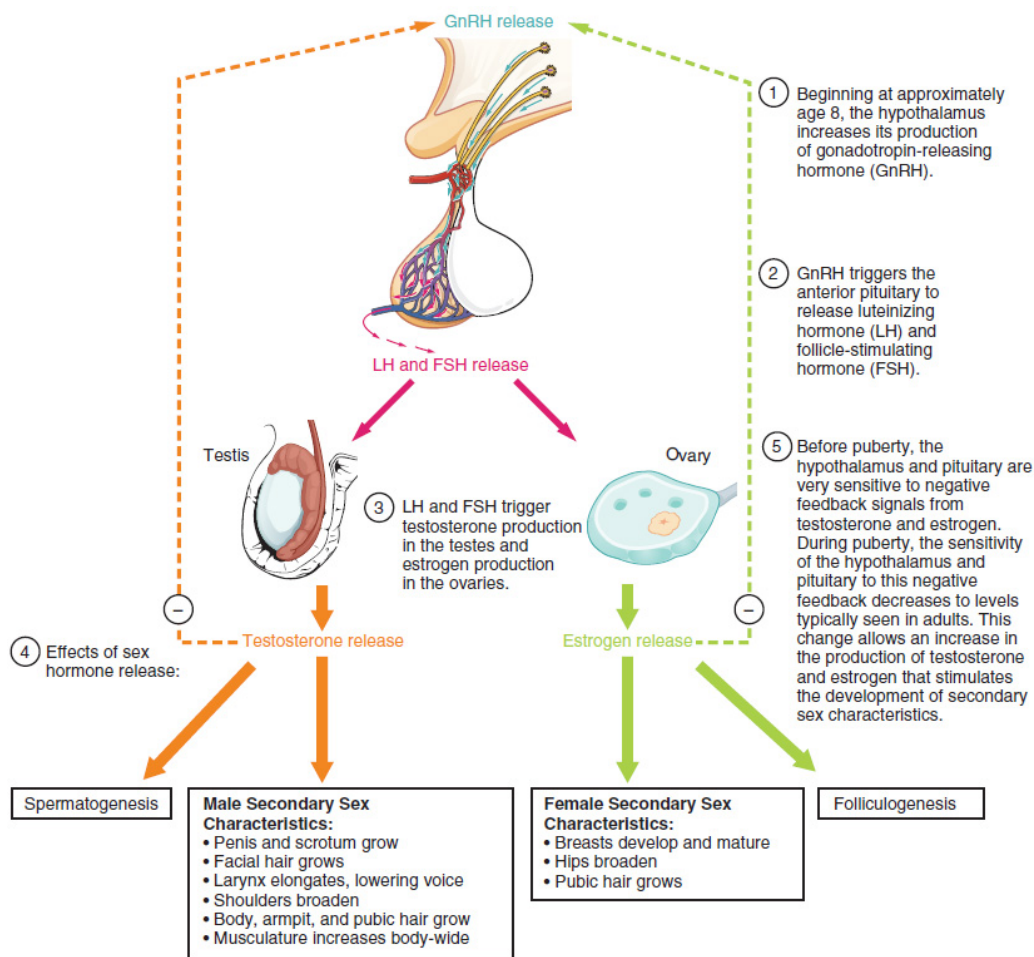


Figure 1. Hormones of Puberty During puberty, the release of LH and FSH from the anterior pituitary stimulates the gonads to produce sex hormones in both male and female adolescents.

The first changes begin around the age of eight or nine when the production of LH becomes detectable.

The release of LH occurs primarily at night during sleep and precedes the physical changes of puberty by several years. In pre-pubertal children, the sensitivity of the negative feedback system in the hypothalamus and pituitary is very high. In other words, very low concentrations of androgens or estrogens will cause negative feedback onto the hypothalamus and pituitary, keeping the production of GnRH, LH, and FSH low.

As an individual approaches puberty, two changes in sensitivity occur. The first is a decrease of sensitivity in the hypothalamus and pituitary to negative feedback, meaning that it takes increasingly larger concentrations of sex steroid hormones to stop the production of LH and FSH. The second change in sensitivity is an increase in sensitivity of the gonads to the FSH and LH signals, meaning the gonads of adults are more responsive to gonadotropins than the gonads of children. As a result of these two changes, the levels of LH and FSH slowly increase and lead to the enlargement and maturation of the gonads, which in turn leads to the secretion of higher levels of sex hormones and the initiation of spermatogenesis and folliculogenesis.

In addition to age, multiple factors can affect the age of onset of puberty, including genetics, environment, and psychological stress. One of the more important influences may be nutrition; historical data demonstrate the effect of better and more consistent nutrition on the age of menarche in girls in the United States, which decreased from an average age of approximately 17 years of age in 1860 to the current age of approximately 12.75 years in 1960, as it remains today. Some studies indicate a link between puberty onset and the amount of stored fat in an individual. This effect is more pronounced in females but has been documented in both sexes. Body fat, corresponding with the secretion of the hormone leptin by adipose cells, appears to have a strong role in determining when menarche occurs. This may reflect, to some extent, the high metabolic costs of gestation and lactation. In individuals who are lean and highly active, such as gymnasts, there is often a delay in the onset of puberty.

Signs of Puberty

Different sex steroid hormone concentrations between the sexes also contribute to the development and function of secondary sexual characteristics.

Female Puberty

As a female reaches puberty, typically the first change that is visible is the development of the breast tissue due to the unopposed low dose estrogen stimulation for about two years before the first menses. This is followed by the growth of axillary and pubic hair. A growth spurt normally starts at approximately age 9 to 11, and may last two years or more. During this time, there is weight gain and an increase in body fat distribution, especially in the hips and thighs. Height can increase 3 inches a year.

Changes in the reproductive organs happen as the vagina lengthens and the labia majora and minora become thickened and rugated. These are followed by the start of menstruation and the first bleeding, **menarche**. Usually, menarche occurs two years after breast bud development due to fluctuating estrogen levels associated with follicle development. The age of menarche has currently declined to 12.2 years in the United States. Ovulation usually occurs within six months from the first episode of vaginal bleeding.

Male Puberty

In males, the growth of the testes is typically the first physical sign of the beginning of puberty and begins at a mean age of 11.6. This is followed by growth and pigmentation of the scrotum and growth of the penis. The adult size and shape of the penis and scrotum is achieved between ages 12 and 17 with an average of about 15 years of age. Next, increased hair growth occurs, including in the armpit, pubic, chest, and facial hair. Pubic hair development is complete at 15 years of age. Testosterone stimulates the growth of the larynx and thickening and lengthening of the vocal folds, which causes the voice to drop in pitch, at an average age of 13.

Spontaneous erection and nocturnal emission may occur, which decrease gradually. The first fertile ejaculations typically appear at approximately 15 years of age, but this age can vary widely across individuals. Unlike the early growth spurt observed in females, the male growth spurt occurs toward the end of puberty, at approximately age 11 to 13. The growth spurt continues over time, with 45% of the adult skeletal mass acquired between age 11 and age 18. A youth's height can increase as much as 4 inches a year. In some males, development can continue through the early 20s.

Table 1.: Examples of secondary sexual characteristics are listed.

Male	Female
Increased larynx size and deepening of the voice	Deposition of fat, predominantly in breasts and hips
Increased muscular development	Breast development
Growth of facial, axillary, and pubic hair, and increased growth of body hair	Broadening of the pelvis and growth of axillary and pubic hair

Image Sources

- **Figure 1.** “Hormones of Puberty” is from [OpenStax Anatomy & Physiology 2E](#), licensed [CC BY 4.0](#). Access for free at [OpenStax Anatomy and Physiology 2E online](#).

Menopause

Menopause is a permanent cessation of menses because of a loss of ovarian activity, usually identified retrospectively when an older female has not had a period for over a year. The age of menopause varies depending on various inherited and environmental factors. The average age of menopause in American women is 51 (range 48-55 years). If menopause happens before the age of 40, that is considered **premature menopause**. Some factors like cigarette smoking, living at high altitudes, exposure to some chemotherapeutic agents, or hysterectomy tend to slightly lower the age of menopause and cause the final cessation of ovulation leading to early menopause.

Perimenopause

Perimenopause is the time just before and after menopause, around the age of 45-55 years. This time is considered a transition to menopause. It is associated with the early onset of symptoms like mood swings, vasomotor flushes, sleep disturbances, headaches, memory problems, decreased libido, urinary incontinence, and irregular cycles. It is accompanied by fluctuations in ovarian function, decreased number and maturation of the remaining follicles, and decreased sensitivity to gonadotropin. Fertility rates are markedly reduced, but conception can occur, as exhaustion of all follicles is not complete yet.

Hormonal changes at menopause

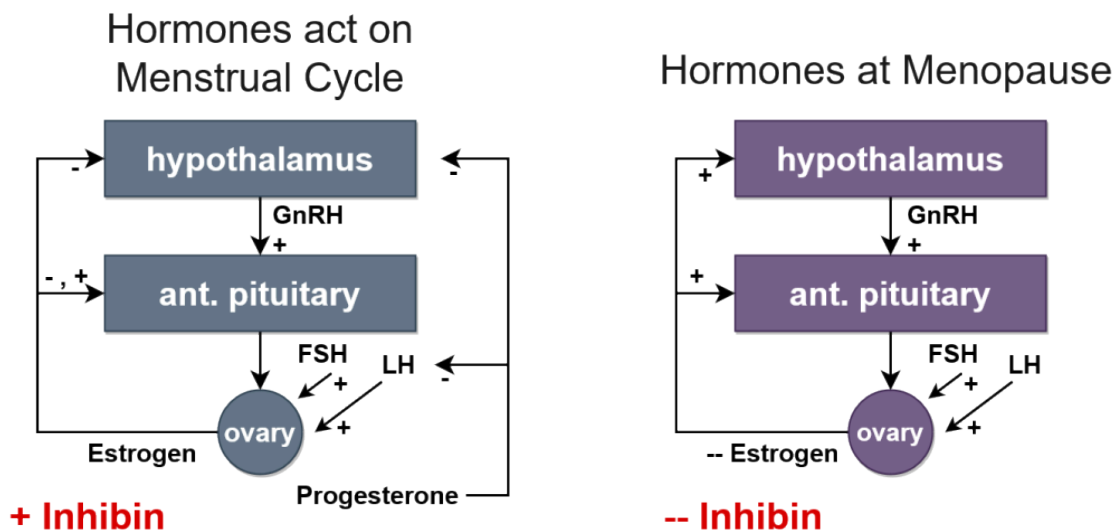


Figure 1. Hormones during the menstrual cycle and at menopause.

During the transition from menses to menopause, there are some hormonal changes due to the decrease in ovarian cells' sensitivity to gonadotropin stimulation, exhaustion of the supply of ovarian follicles, and loss of ovarian cells that secrete estrogen and progesterone. As a result, estrogen and inhibin levels are reduced. Decreased estrogen and inhibin remove the negative feedback on the higher centers. As the negative feedback is removed, gonadotropin, FSH, and LHs level are increased (Figure 1). A state of hypergonadotropic-amenorrhea develops among menopausal women.

Effects of Estrogen Deficiency

The deficiency of estrogen can cause many physical complaints and changes in menopausal women, which include:

Vasomotor Instability

The most common complaint, and approximately 70% of symptoms presented in menopausal women, relate to vasomotor instability. This includes hot flashes due to inappropriate stimulation of the body's heat-releasing mechanisms by the hypothalamus, and can last up to 2 years in women. Vasomotor instability can also cause vasodilation, redness, palpitations, and tachycardia. Vasomotor instability can be severe at night, during stress, or when eating hot or spicy foods.

Urogenital Changes

Urogenital changes are marked by vaginal dryness, vaginal irritation, and itching. Loss of vaginal elasticity, size, vascularization, and decrease in vaginal acidity occur, leading to dyspareunia, or painful intercourse.

The atrophy of external genitalia occurs, the labia majora lose its fat, and the labia minora lose pigmentation and became pale. Weakness of the pelvic ligaments increases the tendency of uterine prolapse. Atrophy of the urethra and bladder mucosa occurs, leading to loss of urinary wall elasticity and urinary incontinence. Urogenital atrophy can cause recurrent genital and urinary tract infections.

Cardiovascular Changes

Estrogen deficiency also increases the incidences of cardiovascular disease. In non-menopausal women, estrogen can stimulate coronary and cerebral blood flow and affect the lipid profile by increasing the

HDL/LDL ratio and inhibiting plaque formation. As estrogen decreases in menopause, the HDL/LDL ratio decreases, and LDL levels rise, increasing the potential for heart attacks and strokes.

Skin Changes

Other physical symptoms of postmenopausal women include an increase in facial hair due to a relative increase in androgens, atrophy of glandular tissue in the mammary glands and its replacement by fatty tissue, and the loss of collagen fibers in the dermis, leading to thin, dry skin with dark spots. Low estrogen at menopause could also decrease cognitive function and lead to mood instability.

Osteoporosis

There is a direct relationship between the lack of estrogen and osteoporosis. An individual experiencing menopause has a high chance to develop osteoporosis due to decreased estrogen levels. Osteoporosis is usually accelerated 5 to 7 years after menopause. An activation of osteoclast bone cells is increased, leading to a decrease in bone density and loss of bone matrix and minerals.

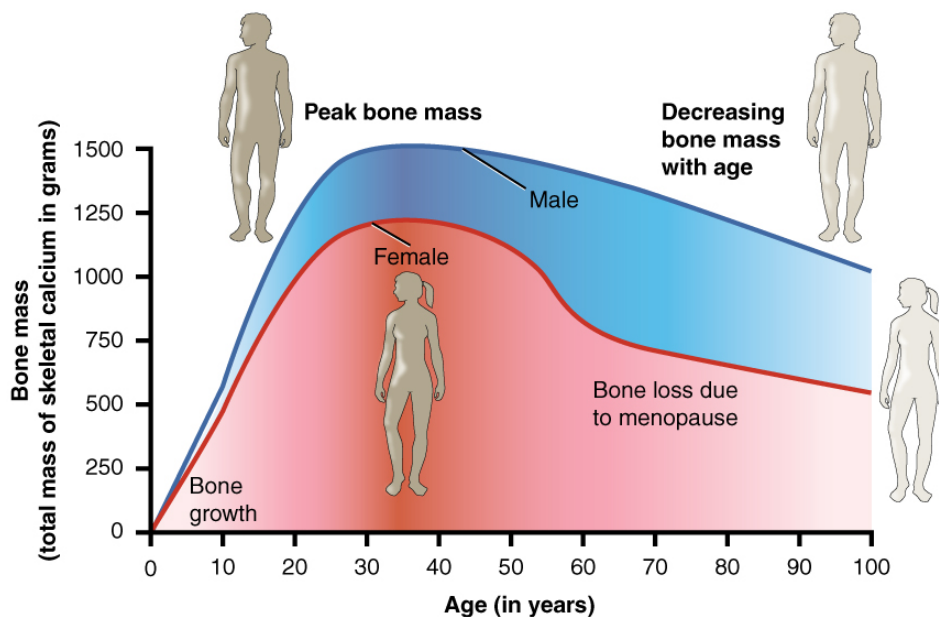


Figure 2. Graph showing relationship between age and bone mass.

Menopausal women have a high tendency to have brittle bones and an increased risk of pathologic bone fractures and spinal deformities. Kyphosis may be developed. Osteoporosis can be prevented by increasing calcium and protein intake along with exercise. Estrogen hormones may be recommended in severe cases.

Estrogen Replacement Therapy (ERT)

To reverse the effects of menopause, some women may be advised to partake in estrogen replacement therapy (ERT). ERT significantly improves vasomotor instability, night sweats, and hot flashes. It also relieves most urogenital symptoms, dryness, itching, and pain during sex. However, ERT does not relieve vaginal stenosis. ERT can also relieve depression, insomnia, and improve mood changes. Estrogen replacement plays a vital role in inhibiting osteoclast activity, preventing bone resorption and bone loss. Thus, estrogen replacement helps in reducing the incidence of wrist, hip, and vertebral fractures.

Estrogen replacement also increases the survival rate in menopausal women with a previous coronary stenosis or heart attack. It lowers blood cholesterol and increases coronary blood flow, causing a 50% reduction in cardiovascular danger and reducing the risk of stroke.

Estrogen Replacement and Cancer Development

Correlating estrogen intake and cancer development is controversial. While estrogen replacement can reduce the risk of colon cancer, an over-intake of estrogen stimulates endometrial cell proliferation, leading to endometrial hypoplasia and endometrial cancer. Studies have also shown that the prolonged intake of estrogen more than 10 years could increase the risk for breast cancer development.

Andropause

Menopause in men starts with the decrease in androgen, called **andropause**. Andropause does not occur as an abrupt and noticeable event like in women, but it occurs gradually. Androgen (Testosterone) levels begin to decline gradually around the age of 40, about 1% per year. That decline is not enough to account for any decrease in libido or erectile function. However, as testosterone level continues to decline with advanced age, facial hair growth may decrease, the penis and scrotum may shrink, a slight decrease in libido may occur, and erections may take a longer time to achieve.

Male aging may also be accompanied by some changes in adrenal function. Adrenal glands androgenic hormones may continue decreasing, leading to decreased vigor and muscular flexibility, and a decline in muscle mass and strength. The chance of osteoporosis in men also increases.

Research has suggested that the administration of the steroid DHEAS in middle-aged men can increase lean body mass. However, that may lead to a potential enlargement of the prostate, increase of testicular shrinkage, and limited sperm production. Its administration should be taken under extreme supervision.

Image Sources

- **Figure 1.** “Hormones during the menstrual cycle” was developed for this volume and available under the same license.
- **Figure 2.** “Graph showing relationship between age and bone mass” is taken from [OpenStax Anatomy & Physiology](https://openstax.org/books/anatomy-and-physiology/), licensed [CC BY 4.0](https://creativecommons.org/licenses/by/4.0/). Access for free at <https://openstax.org/books/anatomy-and-physiology/>.

Gametogenesis, Fertilization, and Implantation

Gametogenesis

Mitosis and meiosis are the two important cell cycles that aid in the growth and development of the human body and reproduction. Mitosis aids in the growth and replacement of old cells, a process called cytogenesis. Mitosis is a type of asexual reproduction, wherein a single parent diploid cell undergoes division, yielding two diploid daughter cells that are genetically identical to the parent cell.

In contrast, meiosis is a crucial mechanism for generating new cells through sexual reproduction. Meiosis involves two distinct stages, meiosis I and meiosis II, which are essential during gametogenesis to produce four unique haploid daughter cells.

In both cycles, DNA replication occurs first, where the nuclear membrane breaks down and the organism's DNA condenses to form chromosomes. A key difference between mitosis and meiosis is that during meiosis, when the chromosomes come together, they “cross over,” which allows for the exchange and “mixing” of the DNA coding. After that, the chromosomes separate and migrate to the opposite ends of the cell. Upon the completion of meiosis I and II, the cell divides into 4 distinct, haploid daughter cells, each with its own characteristics.

Gametogenesis is the process of producing gametes, specialized reproductive cells. This process occurs through the cell cycle of meiosis and produces cells with a haploid number of chromosomes. The process of producing gametes in males is called **spermatogenesis**, and in females, it is called **oogenesis**. Spermatogenesis leads to the formation of sperm, while oogenesis results in the development of eggs (ova). These processes occur in the testes for males and the ovaries for females, respectively, and are essential for sexual reproduction.

Spermatogenesis

Spermatogenesis occurs in the seminiferous tubules that form the bulk of each testis. The process begins at puberty, after which time sperm are produced constantly throughout the lifespan. One production cycle, from spermatogonia to formed sperm, takes approximately 64 days. A new cycle starts approximately every 16 days, although this timing is not synchronous across the seminiferous tubules. The total number of sperms a man produces slowly declines after age 35, and some studies suggest that smoking can lower sperm counts irrespective of age.

The process of spermatogenesis begins with mitosis of the diploid spermatogonia. Because these cells are diploid ($2n$), they each have a complete copy of the father's genetic material, 46 chromosomes.

However, mature gametes are haploid ($1n$), containing 23 chromosomes—meaning that daughter cells of spermatogonia must undergo a second cellular division through the process of meiosis.

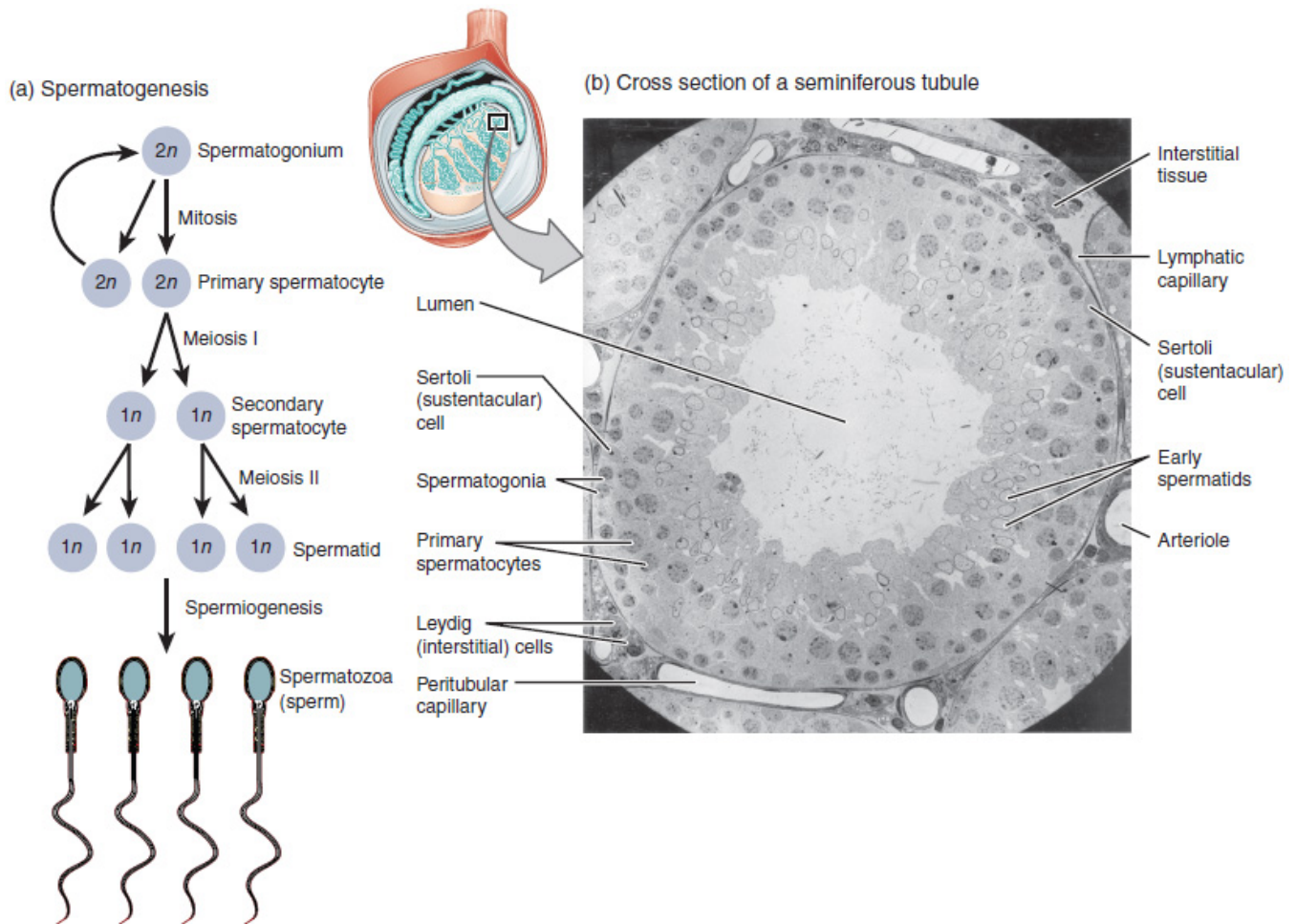


Figure 1. Spermatogenesis (a) Mitosis of a spermatogonial stem cell involves a single cell division that results in two identical, diploid daughter cells (spermatogonia to primary spermatocyte). Meiosis has two rounds of cell division: primary spermatocyte to secondary spermatocyte, and then secondary spermatocyte to spermatid. This produces four haploid daughter cells (spermatids). (b) In this electron micrograph of a cross-section of a seminiferous tubule from a rat, the lumen is the light-shaded area in the center of the image. The location of the primary spermatocytes is near the basement membrane, and the early spermatids are approaching the lumen (tissue source: rat). EM \times 900.

The cycle starts at puberty, where the spermatogonium cell goes through mitosis. Two identical diploid cells result from spermatogonia mitosis. One of these cells remains a spermatogonium, and the other becomes a primary **spermatocyte**. The next stage is the process of spermatogenesis. As in mitosis, DNA is replicated in a primary spermatocyte before it undergoes a cell division called meiosis I. During meiosis I, each of the 23 pairs of chromosomes separates. This results in two cells, called secondary spermatocytes, each with only half the number of chromosomes. Then, a second round of cell division (meiosis II) occurs in both secondary spermatocytes. During meiosis II, each of the 23 replicated

chromosomes divides, similar to what happens during mitosis. Thus, meiosis results in separating the chromosome pairs. This second meiotic division results in four cells with only half the number of chromosomes. Each of these new cells is a **spermatid**. Although haploid, early spermatids look very similar to cells in the earlier stages of spermatogenesis, with a round shape, central nucleus, and a large amount of cytoplasm. A process called **spermiogenesis** transforms these early spermatids, reducing the cytoplasm and beginning the formation of the parts of a true sperm. The fifth stage of germ cell formation—spermatozoa or formed sperm—is the end result of this process, which occurs in the portion of the tubule nearest the lumen. Eventually, the sperm are released into the lumen and are moved along a series of ducts in the testis toward a structure called the epididymis for the next step of sperm maturation.

Oogenesis

Oogenesis process begins with the ovarian stem cells, or **oogonia**. Oogonia are formed during fetal development and divide via mitosis, much like spermatogonia in the testis. Unlike spermatogonia, however, oogonia forms primary oocytes in the fetal ovary prior to birth. These primary oocytes are then arrested in this stage of meiosis I, only to resume it years later, beginning at puberty and continuing until the woman is near menopause (the cessation of a woman's reproductive functions). The number of primary oocytes present in the ovaries declines from one to two million in an infant, to approximately 400,000 at puberty, to zero by the end of menopause.

The initiation of **ovulation**—the release of an oocyte from the ovary—marks the transition from puberty into reproductive maturity in females. From then on, throughout the reproductive years, ovulation occurs approximately once every 28 days. Just prior to ovulation, a surge of luteinizing hormone triggers the resumption of meiosis in a primary oocyte. This initiates the transition from primary to secondary oocyte. However, as shown in the figure below, this cell division does not result in two identical cells. Instead, the cytoplasm is divided unequally, and one daughter cell is much larger than the other. This larger cell, the secondary oocyte, eventually leaves the ovary during ovulation. The smaller cell, called the first **polar body**, may or may not complete meiosis and produce second polar bodies; in either case, it eventually disintegrates. Therefore, although oogenesis produces up to four cells, only one survives.

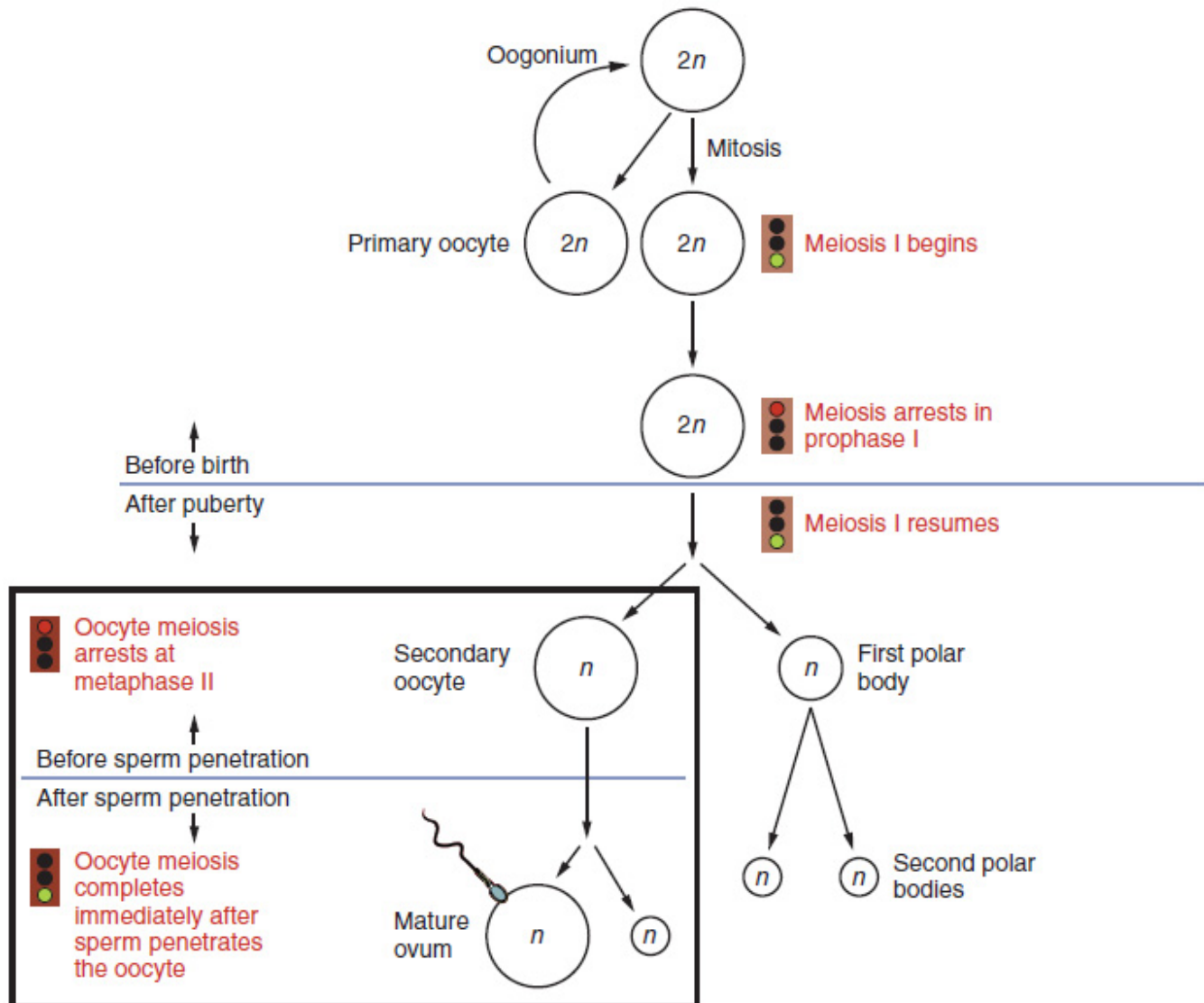


Figure 2. Oogenesis The unequal cell division of oogenesis produces one to three polar bodies that later degrade, as well as a single haploid ovum, which is produced only if there is penetration of the secondary oocyte by a sperm cell.

How does the diploid secondary oocyte become an **ovum**—the haploid female gamete? Meiosis of a secondary oocyte is completed only if a sperm succeeds in penetrating its barriers. Meiosis II then resumes, producing one haploid ovum that, after fertilization by a (haploid) sperm, becomes the first diploid cell of the new offspring (a zygote). Thus, the ovum can be considered a brief, transitional, haploid stage between the diploid oocyte and diploid zygote.

The larger amount of cytoplasm contained in the female gamete is used to supply the developing zygote with nutrients between fertilization and implantation into the uterus. Interestingly, sperm contribute only DNA at fertilization—not cytoplasm. Therefore, the cytoplasm and all of the cytoplasmic organelles

in the developing embryo are of maternal origin. This includes mitochondria, which contain their own DNA. Scientific research in the 1980s determined that mitochondrial DNA was maternally inherited, meaning that you can trace your mitochondrial DNA directly to your mother, her mother, and so on back through your female ancestors.

Take Home Message

- Spermatogenesis starts at puberty while oogenesis starts before birth.
- A spermatid is a large cell that loses its cytoplasm and eventually becomes sperm.
- Primary oocytes enter meiosis and stop at the prophase stage of meiosis I. They complete meiosis I at ovulation.
- An LH peak is required for secondary oocyte development.
- Fertilization stimulates the completion of meiosis II and ova development.

Image Sources

- **Figure 1.** “Spermatogenesis” is from [OpenStax Anatomy & Physiology 2E, CC BY 4.0](#). Access for free at [OpenStax Anatomy and Physiology 2E online](#). Micrograph image provided by the Regents of University of Michigan Medical School © 2012.
- **Figure 2.** “Oogenesis” is from [OpenStax Anatomy & Physiology 2E, CC BY 4.0](#). Access for free at [OpenStax Anatomy and Physiology 2E online](#).

Fertilization

Fertilization is the process by which gametes (an egg and sperm) fuse to form a zygote. Through it, a number of steps and reactions occur. During ejaculation, hundreds of millions of sperm (spermatozoa) are released into the vagina. Almost immediately, millions of these sperm are overcome by the acidity of the vagina (approximately pH 3.8), and millions more may be blocked from entering the uterus by thick cervical mucus. Of those that do enter, thousands are destroyed by phagocytic uterine leukocytes. The race into the uterine tubes, the most typical site for sperm to encounter the oocyte, is reduced to a few thousand contenders. The sperms must make their way into one of the two uterine tubes (fallopian tubes) to meet the egg, and overcome the cilia that work only in the direction of the uterine cavity. Approximately 100–1000 sperms reach the ampulla, the site of fertilization, where about 20–200 sperms meet the oocyte cell mass.

The journey through the female reproductive system to reach the oocyte is thought to be facilitated by uterine contractions which usually take around 30 minutes to 2 hours. A healthy sperm could reach the ampulla within 30 minutes. If the sperm do not encounter an oocyte immediately, they can survive in the uterine tubes for another 48–72 hours. Thus, fertilization can still occur if intercourse takes place a few days before ovulation. In comparison, an oocyte can survive independently for only approximately 24 hours following ovulation. Therefore, intercourse more than a day after ovulation will usually not result in fertilization.

During the journey, fluids in the female reproductive tract prepare the sperm for fertilization through a process called **capacitation**, or priming. The fluids improve the motility of the spermatozoa. They also deplete cholesterol molecules embedded in the membrane of the head of the sperm, thinning the membrane in such a way that will help facilitate the release of the lysosomal (digestive) enzymes needed for the sperm to penetrate the oocyte's exterior once contact is made. Sperm must undergo the process of capacitation to have the “capacity” to fertilize an oocyte. If they reach the oocyte before capacitation is complete, they will be unable to penetrate the oocyte's thick outer layer of cells.

Contact Between Sperm and Oocyte

Upon ovulation, the oocyte released by the ovary is swept into—and along—the uterine tube. Fertilization must occur in the distal uterine tube because an unfertilized oocyte cannot survive the 72-hour journey to the uterus. The released oocyte is a secondary oocyte surrounded by two protective layers. The **corona radiata** is an outer layer of follicular (granulosa) cells that form around a developing oocyte in the ovary and remain with it upon ovulation. The underlying **zona pellucida** (pellucid =

“transparent”) is a transparent, but thick, glycoprotein membrane that surrounds the cell’s plasma membrane.

As the oocyte is swept along the distal uterine tube, the oocyte encounters the surviving capacitated sperm, which stream toward it in response to chemical attractants released by the cells of the corona radiata. To reach the oocyte itself, the sperm must penetrate the two protective layers. The sperm first burrow through the cells of the corona radiata. Then, upon contact with the zona pellucida, the sperm bind to receptors in the zona pellucida. This initiates a process called the **acrosomal reaction**, in which the enzyme-filled “cap” of the sperm, called the acrosome, releases its stored digestive enzymes. These enzymes clear a path through the zona pellucida, allowing sperm to reach the oocyte. Finally, a single sperm makes contact with sperm-binding receptors on the oocyte’s plasma membrane. The plasma membrane of the sperm then fuses with the oocyte’s plasma membrane, and the head and mid-piece of the “winning” sperm enter the oocyte interior.

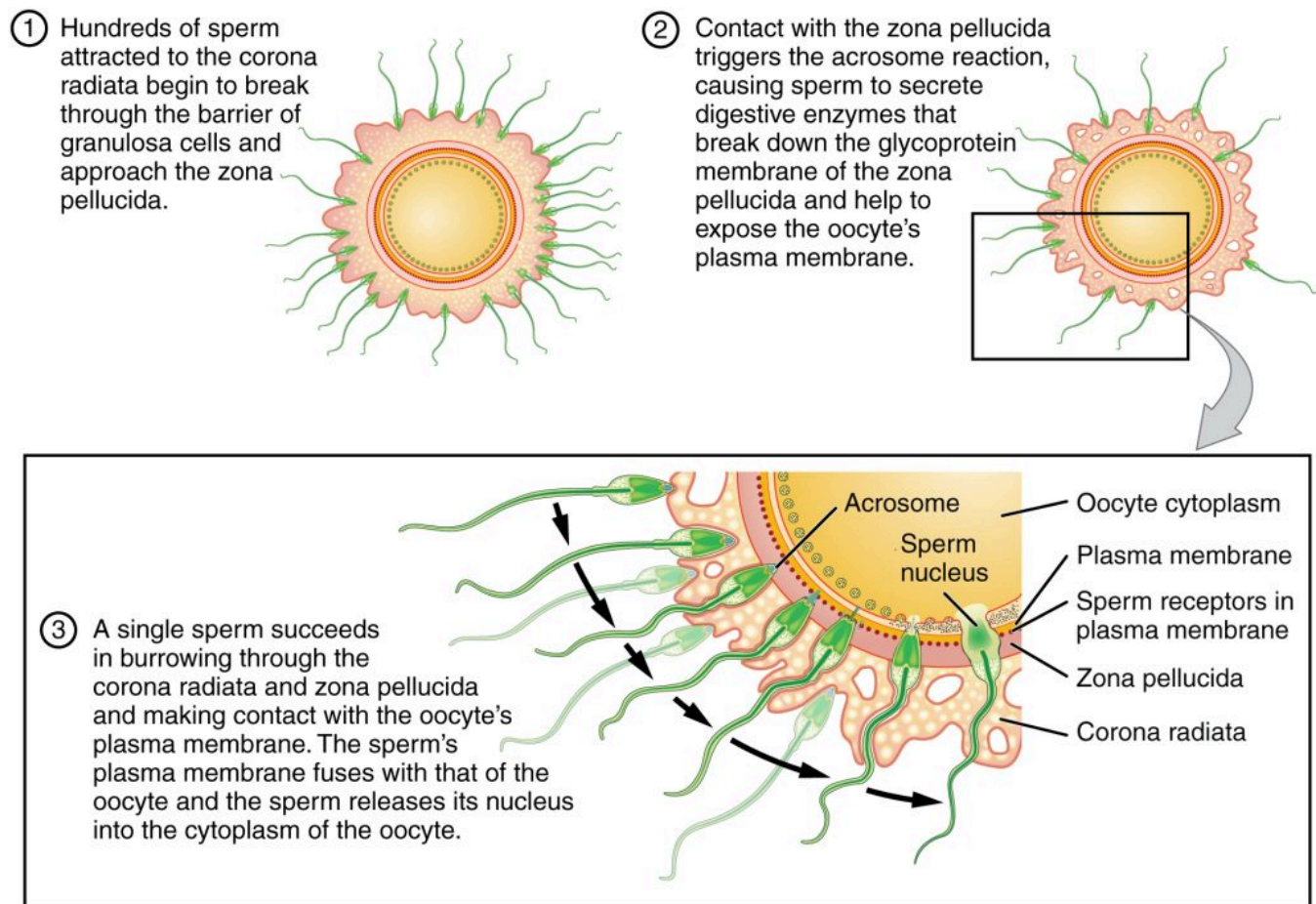


Figure 1. The fertilization process (Image Source: [OpenStax Anatomy & Physiology 2E](#), CC BY 4.0. Access for free at [OpenStax Anatomy and Physiology 2E online](#))

How do sperm penetrate the corona radiata? Some sperm undergo a **spontaneous acrosomal reaction**,

an acrosomal reaction that is not triggered by contact with the zona pellucida. The digestive enzymes released by this reaction digest the extracellular matrix of the corona radiata. As you can see, the first sperm to reach the oocyte is never the one to fertilize it. Rather, hundreds of sperm cells must undergo the acrosomal reaction, each helping to degrade the corona radiata and zona pellucida until a path is created to allow one sperm to contact and fuse with the oocyte's plasma membrane.

Consider the loss of millions of sperm between entry into the vagina and degradation of the zona pellucida. Taking this into account, you can understand why a low sperm count can cause male **infertility**.

When the first sperm fuses with the oocyte, the oocyte deploys two mechanisms to prevent **polyspermy**, or penetration by more than one sperm. Preventing polyspermy is critical because if more than one sperm were to fertilize the oocyte, the resulting zygote would be a triploid organism with three sets of chromosomes, and incompatible with life.

The first mechanism is the **fast block**, which involves a near-instantaneous change in sodium ion permeability upon the binding of the first sperm, depolarizing the oocyte plasma membrane and preventing the fusion of additional sperm cells. The fast block sets in almost immediately and lasts for about a minute.

At the same time, an influx of calcium ions following sperm penetration triggers the second mechanism, the **slow block**. In this process, referred to as the **cortical reaction**, cortical granules sitting immediately below the oocyte plasma membrane fuse with the membrane and release zonal inhibiting proteins and mucopolysaccharides into the space between the plasma membrane and the zona pellucida. Zonal inhibiting proteins cause the release of any other attached sperm and destroy the oocyte's sperm receptors, thus preventing any more sperm from binding. The mucopolysaccharides then coat the nascent zygote in an impenetrable barrier that, together with the hardened zona pellucida, is called a **fertilization membrane**, or **eggshell**.

Recall that at the point of fertilization, the oocyte has not yet completed meiosis; all secondary oocytes remain arrested in metaphase of meiosis II until fertilization. Only upon fertilization does the oocyte complete meiosis. The unneeded complement of genetic material that results is stored in a second polar body that is eventually ejected. At this moment, the oocyte has become an **ovum**, the female haploid gamete. The two haploid nuclei derived from the sperm and oocyte and contained within the egg are referred to as **pronuclei**. They decompress, expand, and replicate their DNA in preparation for mitosis. The pronuclei then migrate toward each other, their nuclear envelopes disintegrate, and the male- and female-derived genetic material intermingles. This step completes the process of fertilization and results in a single-celled diploid **zygote** with all the genetic instructions it needs to develop into a human. Sex, hair and eye color determination happen at this point.

Clinical Correlation

Fraternal Twins

Fraternal twins, also known as dizygotic twins, are a type of twins that result from the simultaneous release and fertilization of two different eggs (oocytes) by two different sperm cells. Fraternal twins are essentially like any other siblings, with the key difference being that they share the same womb during pregnancy.

Because they develop from separate fertilized eggs, they have their own unique genetic makeup and can be of the same gender (two brothers or two sisters) or of different genders (a brother and a sister). They share approximately 50% of their genes, like any other siblings born at different times.

Early Pregnancy Factor

Early pregnancy factor (EPF) is a protein that has been used to describe a substance in the mother's blood that seems to be present within hours after conception (fertilization), before the embryo even reached the uterus. This factor might be involved in preventing the mother's immune system from rejecting the developing embryo. Ongoing research is attempting to identify and characterize the specific molecules or factors involved in early pregnancy, although a universally accepted explanation has yet to be established.

Take Home Message

- An acrosomal reaction is necessary for sperm to penetrate an oocyte.
- Once fertilization occurs, a hardening of the eggshell occurs, preventing polyspermy.
- The fusion of the ovum and sperm's pronucleus leads to zygote development.
- Early pregnancy factor (EPF) may be used as an indication that fertilization has occurred.

Image Sources

- **Figure 1.** “The fertilization process” is from [OpenStax Anatomy & Physiology 2E](#), licensed [CC BY 4.0](#). Access for free at [OpenStax Anatomy and Physiology 2E online](#).

Post Fertilization and Pre-Embryonic Stage

Cleavage and Blastocyst Development

Following fertilization, the zygote and its associated membranes, together referred to as the **conceptus**, continue to be projected toward the uterus by peristalsis and beating cilia. During its journey to the uterus, the zygote undergoes five or six rapid **mitotic** cell divisions. The rapid, multiple rounds of cell division are termed **cleavage**. Although each cleavage results in more cells, it does not increase the total volume of the conceptus. Each daughter cell produced by cleavage is called a **blastomere**.

Approximately 72 hours after fertilization, a 16-cell conceptus reaches the uterus. The cells that had been loosely grouped are now compacted and look more like a solid mass. The name given to this structure is the **morula**.

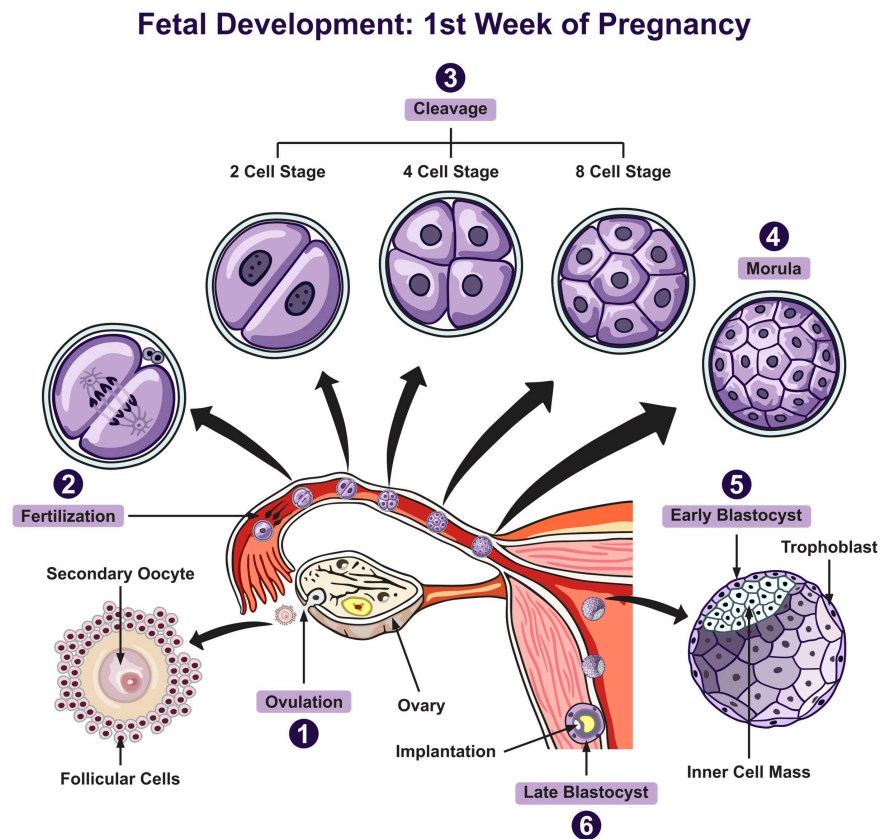


Figure 1. The figure shows cleavage and early division.

Once inside the uterus, the conceptus floats freely for several more days. It continues to divide, creating a ball of approximately 100 cells and consuming nutritive endometrial secretions called uterine milk while the uterine lining thickens. The ball of the tightly bound cells starts to secrete fluid and form a central fluid-filled cavity. At this developmental stage, approximately 5 days after ovulation, the conceptus is referred to as a **blastocyst**.

Within the blastocyst, the cells arrange themselves into two layers. A group of cells forms into an **inner cell mass** which is fated to become the embryo. The cells that form the outer shell, called **trophoblasts**, will develop into the **placenta** (the organ of nutrient, waste, and gas exchange between mother and the developing embryo).

As the blastocyst forms, the trophoblast excretes enzymes that begin to degrade the zona pellucida. In a process called “hatching,” the conceptus breaks free of the zona pellucida in preparation for implantation.

Clinical Correlation

Embryonic Stem Cell Research

Up to the 8-cell stage of cleavage, the cells of the conceptus are pluripotent cells, where each cell has the potential to differentiate into any cell type in the human body, and each can be independently developed into an identical conceptus. These cells are called **embryonic stem cells (ESC)** and are widely used in scientific research to better understand early human development, study diseases, and develop potential treatments. ESCs provide a valuable model for studying cell differentiation and developmental processes; however, research involving ESCs has been a topic of ethical debate because their extraction usually involves the destruction of human embryos.

Identical Twins

Identical twins are the result of a single fertilized egg (oocyte) splitting into two embryos. This splitting typically occurs shortly after fertilization, but it can happen at various stages of development, including before the 16-cell stage.

When the single fertilized egg splits into two embryos, these twins share the same genetic material, making them genetically identical. Because they come from the same fertilized egg, they are of the same sex and usually share a strong resemblance in terms of physical appearance. Identical twins are sometimes called “**monozygotic twins**” to highlight their single-egg origin.

Take Home Message

- The process by which the cells go into mitotic division after fertilization is known as cleavage.
- The solid mass at 16-cell conceptus is called morula.
- The blastocyst is the fluid-filled space within the conceptus developed approximately 5 days after ovulation.

Image Sources

- **Figure 1.** “Fetal development first week of pregnancy ” by [udaix](#) was licensed through Adobe Stock for educational use.

Implantation

Implantation occurs when the conceptus adheres to the wall of the uterus, signaling the end of the pre-embryonic stage of development.

As the zona pellucida begins to fragment, the blastocyst is able to attach to the uterine endometrium. By this time, progesterone and estrogen produced by the corpus luteum lead to the proper proliferation and differentiation of the endometrium. As the endometrium continues its maturation, a **decidua** layer is formed. The maturation of the endometrium and formation of a secretory endometrium is called **decidualization**. Around the end of the first week, the blastocyst comes into contact with the secretory uterine wall and adheres to it, embedding itself in the uterine lining via the trophoblast cells. Thus begins the process of **implantation**.

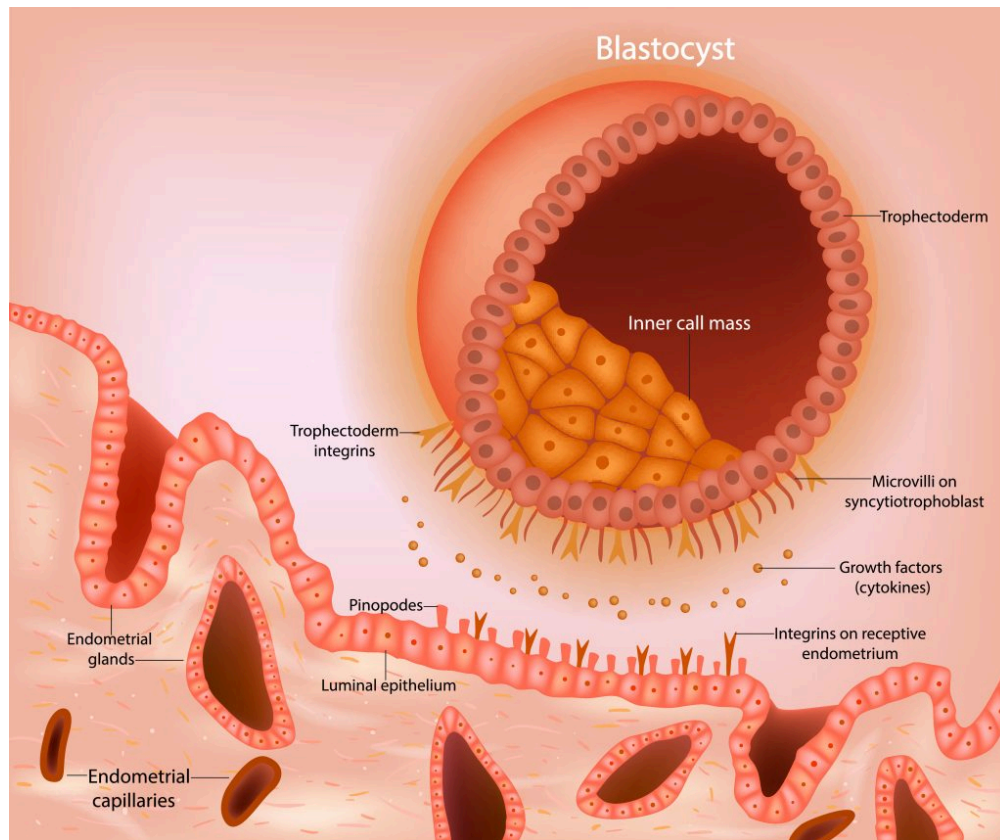


Figure 1. The graphic shows the trophoblastic tissue, inner cytotrophoblast and outer syncytiotrophoblast.

The inner cell layer of the trophoblast of the blastocyst, called the **cytotrophoblast**, forms the fetal surface of the placenta. The outer layer of the trophoblast, known as the **syncytiotrophoblast**,

contributes to the maternal surface of placenta that fuses with endometrial cells. The syncytiotrophoblast cells lose their cell walls and become the working interface of the placenta. The cytoplasm of the cells fuse and form a multinucleated cytoplasm. Then, the syncytiotrophoblast layer invaginates into the decidua and is surrounded by lakes of maternal blood, allowing the efficient transfer of oxygen, nutrients, and waste products bidirectionally without the direct mixing of maternal and fetal blood.

The syncytiotrophoblast cells produce **human chorionic gonadotropin (hCG)**, a hormone that directs the corpus luteum to survive, enlarge, and continue producing progesterone and estrogen to suppress menses. These functions of hCG are necessary for creating an environment suitable for the developing embryo. As a result of this increased production, hCG accumulates in the maternal bloodstream and is excreted in the urine. Implantation is complete by the middle of the second week. Just a few days after implantation, the trophoblast has secreted enough hCG for an at-home urine pregnancy test to give a positive result. hCG is the marker used for **mass pregnancy tests**.

Implantation can be accompanied by minor bleeding. The blastocyst typically implants in the fundus of the uterus or on the posterior wall. However, if the endometrium is not fully developed and is not ready to receive the blastocyst, the blastocyst will detach and find a better spot. A significant percentage (50–75 percent) of blastocysts fail to implant; when this occurs, the blastocyst is shed with the endometrium during menses. The high rate of implantation failure is one reason why pregnancy typically requires several ovulation cycles to achieve.

Clinical Correlation

Precise timing of endometrial lining and implantation

The time from ovulation to implantation takes approximately 10–12 days. Proper timing for the arrival of the conceptus into the uterine cavity is essential for implantation. During IVF techniques, the maturation of the endometrium must be coordinated precisely with the developmental stage of the conceptus transferred into the uterus for optimal pregnancy rates. Attempts at tubal re-anastomosis may be followed by too short of the oviduct (<4cm). Short tubes might accelerate the transport of the conceptus through the tubes and diminish pregnancy rates.

Take Home Message

- Trophoblast cells produce hCG, the marker used for mass pregnancy tests.
- A positive pregnancy test is an indication that implantation has occurred.

Image Sources

- **Figure 1.** “Blastocyst implantation” by [sakurra](#) was licensed through Adobe Stock for educational use.

Placenta Development

The placenta is a vital organ for fetal development. It arises from the trophoblastic layer of the blastocyst. At 14 days after fertilization, the cytotrophoblast, the trophoblast layer facing the fetal side, develops the chorion layer that wraps around the baby. The outer layer of the trophoblast, the syncytiotrophoblast, forms on the maternal side of the placenta.

The placenta gradually takes over the corpus luteum's duties in the secretion of estrogen and progesterone. By the end of the first trimester, the placenta becomes the primary source of estrogen and progesterone and is responsible for the continuation of pregnancy, taking over the role of feeding the embryo.

The placenta usually connects to the conceptus via the **umbilical cord**, which contains the umbilical vessels. The spaces within the cord and around the blood vessels are filled with Wharton's jelly, a mucous connective tissue. The umbilical cord and vessels aid in the transfer of oxygen, nutrients, and waste products without mixing maternal and fetal blood. Deoxygenated blood and waste leaves the fetus through two umbilical arteries, while nutrients and oxygen are carried from the mother to the fetus through a single umbilical vein. The umbilical cord is surrounded by the amnion. The placenta's initial development as an organ is complete by weeks 14–16 after fertilization.

The placenta grows like an expanding disk. By week 20, the placenta covers half of the uterine wall and weighs about 200g. At term, it is about 700g and 20cm in diameter. The placenta is highly vascular and if the baby dies or is delivered, the placenta can keep growing.

Because blood cells cannot move across the placenta, the maternal and fetal blood do not co-mingle. This separation prevents the mother's cytotoxic T cells from reaching and subsequently destroying the fetus, which bears "non-self" antigens. Further, it ensures the fetal red blood cells do not enter the mother's circulation and trigger antibody development (if they carry "non-self" antigens) until the final stages of pregnancy or birth. This separation is why, even in the absence of preventive treatment, an Rh- mother doesn't develop antibodies that could cause hemolytic disease in her first Rh+ fetus.

Although blood cells are not exchanged, the placenta is permeable to lipid-soluble fetotoxic substances: alcohol, nicotine, barbiturates, antibiotics, certain pathogens, and many other substances that can be dangerous or fatal to the developing embryo or fetus. For these reasons, pregnant women should avoid fetotoxic substances.

The placenta is normally attached and situated in the upper one-third of the anterior or posterior uterine wall within the endometrium. This placement is conducive to the growth and development of the embryo.

Clinical Correlation: Abnormal Attachment of the Placenta

Placenta Previa

Implantation of the placenta occurs in the lower part of the uterus. A placenta can result in the partial or complete coverage of the cervical os. As the highly vascularized nature of the placenta, bleeding may occur with the growing uterus, and early or partial separation of the placenta may happen, and continuation of pregnancy will be jeopardy.

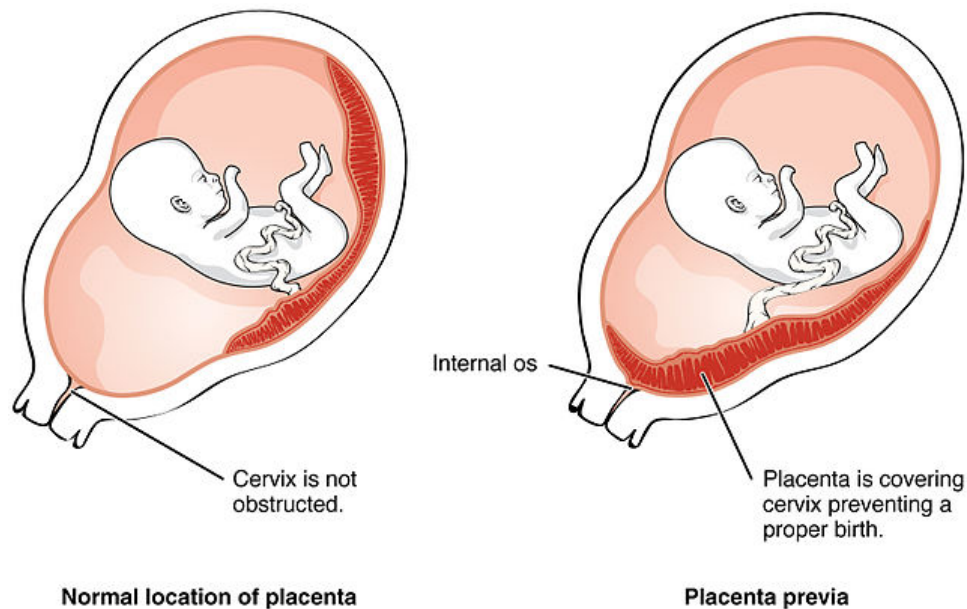


Figure 1. An embryo that implants too close to the opening of the cervix can lead to placenta previa, a condition in which the placenta partially or completely covers the cervix.

Placenta Accreta

A condition characterized by placenta attachment directly into the myometrium, placenta accreta is often caused by defective decidual endometrial layers, uterine inflammation, or old scar tissue from previous cesarean or uterine surgery. Tied placental implantation in the myometrium will impair placental separation after birth, resulting in massive bleeding and hemorrhage that may even lead to the death of the mother.

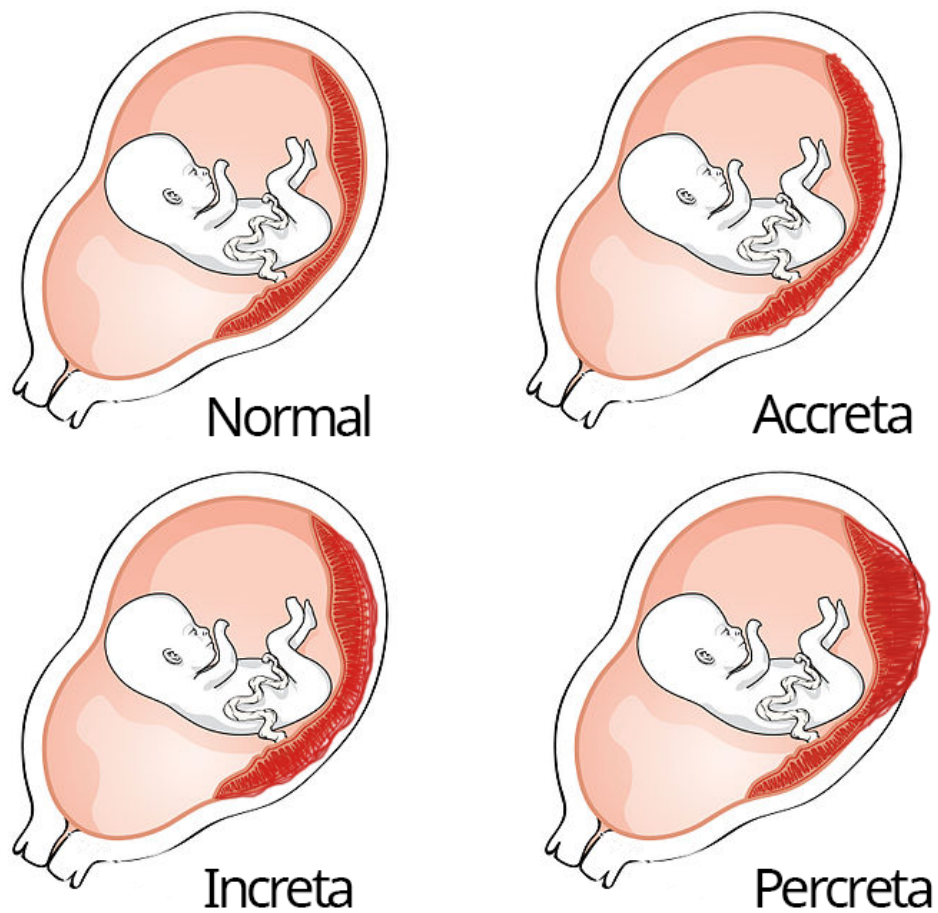


Figure 2. Accreta, Increta, and Percreta placenta growth.

Take Home Message

- The placenta is a necessary organ for fetal growth.
- The placenta's growth is independent of fetal growth.
- Attachment of placenta is typically in the upper 1/3 of the endometrium.

Image Sources

- **Figure 1.** "Placenta Previa" is from [OpenStax Anatomy & Physiology 2E](#), licensed [CC BY 4.0](#).

Access for free at [OpenStax Anatomy and Physiology 2E online](#).

- **Figure 2.** “Accreta, Increta, and Percreta placenta growth” is adapted by Abbey Elder from “Placenta Previa” in [OpenStax Anatomy & Physiology 2E](#), licensed [CC BY 4.0](#). Access for free at [OpenStax Anatomy and Physiology 2E online](#).

Embryogenesis

Embryogenesis is a very complex system with a slim chance of achieving infant life. Statistical analysis shows that out of 100 oocytes in the presence of sperm, “84 are fertilized, 69 are implanted, a week later 42 are still alive, 37 survive to the sixth week or pregnancy, and only 31 survive to birth.”¹ In over half of these instances, the cause for zygote death and miscarriage are due to chromosomal abnormalities. Furthermore, many complex cellular steps conducted during pregnancy have to be carried out perfectly to ensure a healthy infant.

After implantation, the inner cell mass of the blastocyst that will become the embryo differentiates into two layers: the **epiblast** and the **hypoblast**. The epiblast then gastrulates into three germ layers: the ectoderm, mesoderm, and endoderm, and develops the embryo. At the same time, the hypoblast will form the extra-embryonic membranes: the yolk sac, amnion, and allantois.

Throughout fetal growth, many terms correlate to the cell division and the formation of the epiblast. Following the initial two weeks of development, the term “**pre-embryo**” is used to refer to the developing structure. From three to eight weeks post-fertilization, the pre-embryonic cells become distinct and become the “**embryo**”. Subsequently, from eight weeks post-fertilization until birth, the developing organism is referred to as the “**fetus**.”

During early development, cells in the embryo go through a process of differentiation, which involves becoming specialized to perform specific functions. The position of a given cell relative to others can play a crucial role in determining its fate or the specific genes it will express. This concept is known as spatial patterning, or **positional information**, and implies that the location of a cell within the developing embryo influences the genes it activates and the type of cell it will become.

In addition to the differentiation of various cell types, many essential structures and organs form to support the growing embryo and fetus, including the **placenta**, **umbilical cord** and **amniotic fluid**. As the embryo develops into a fetus, these supportive structures become increasingly important for the well-being of the growing fetus. They play critical roles in ensuring that the fetus receives the necessary nutrients, oxygen, and protection for healthy development. The placenta, umbilical cord, and amniotic fluid are intricately linked in their functions, forming a nurturing environment for the fetus throughout pregnancy.

1. Grobstein, Clifford. “External Human Fertilization.” *Scientific American*, vol. 240, no. 6, 1979, pp. 57–67.

Morphogenesis

Morphogenesis refers to the shaping and structuring of an organism's form. It encompasses a series of intricate processes responsible for the emergence of the body's diverse systems and organs. This developmental journey is a continuous maturation, with all systems and organs initiating their formation in the early stages of pregnancy, primarily within the first eight weeks of gestation, and their progression continues throughout the gestational period. This gradual maturation prepares the fetus for its eventual transition to life outside the womb. Three critical organs that undergo development and determine the potential for fetal survival and health are the heart, lungs, and nervous system. Their maturation and functions are discussed below.

The **cardiovascular system**, including the heart, is one of the earliest functional systems to develop, with the sound of the heartbeat becoming audible as early as five weeks through vaginal probe or by normal stethoscope at week twelve.

Lung maturity is a critical aspect of fetal development and occurs toward the end of pregnancy, with the proper production of **surfactant**, a substance produced by special cells in developing fetal lungs. Surfactant plays a crucial role in reducing surface tension in the alveoli (tiny air sacs in the lungs). The maturation of the lungs refers to the readiness of a fetus's lungs to function effectively in supporting respiration once the infant is born.

The formation of the nervous system, including the **central nervous system (CNS)** and **peripheral nervous system (PNS)**, begins very early in embryonic development. The neural tube, which eventually becomes the brain and spinal cord, forms as others during the first eight weeks after conception. Fat deposition and myelin formation occur later in fetal development, typically in the third trimester. Myelin is a fatty substance that surrounds nerve fibers and plays a crucial role in the rapid transmission of nerve impulses. This process continues throughout pregnancy and even after birth.

Clinical Correlation

Preterm or Premature Infants

Infants who are born before they have reached full term are at higher risk for various complications because some of their organs and systems may not have fully matured. For example, the risk of respiratory distress in premature infants is a significant concern because the lungs typically require the last few weeks of pregnancy to develop fully and become fully functional at birth.

Medical professionals closely monitor lung maturity, especially when managing pregnancies that might

be at risk for preterm birth. When necessary, interventions may be taken to support lung development, including the administration of corticosteroids to stimulate surfactant production in the lungs and improve lung maturity.

Developmental Milestones

Uncontrolled urination or defecation in a newborn, often referred to as “involuntary voiding” or “involuntary bowel movements,” is indeed a common occurrence. This is primarily due to the immaturity of the nervous system and the myelin sheath at birth.

As the nervous system and myelin sheath continue to mature after birth, infants gradually gain control over these functions. By the age of 2 or 3, most children have developed the ability to voluntarily control urination and bowel movements and have achieved toilet training milestones.

Reproductive System Development

The reproductive system is one of the few systems that matures differently based on the sex of embryos. Sex determination is completed at fertilization. It is well known that females have two X chromosomes, while males have one X and one Y. Since all eggs carry X chromosomes, the determination of sex is reliant on the sperm’s contribution. If the sperm has the Y chromosome, the SRY gene is activated, which initiates the expression of the Testis-Determining Factor (TDF) and leads to the development of the testes. Nevertheless, it is important to note that it takes time for the gonads to differentiate into their final form.

Internal and External Genitalia Differentiation

At week five of development, a paired bulge is present near the midline at the back of the abdominal cavity. These are the genital ridges and are indifferent in males and females. Germ cells from the yolk sac will then migrate toward the genital ridges. Only a week later, indifferent accessory ducts are present. These are the paramesonephric and mesonephric ducts. It is important to note that external genitalia of the different genders also arise from the same structures: the genital tubercle, urogenital folds, and labioscrotal swellings.

At week seven, male structures begin to develop. Primordial germ cells that are XY develop the testis, which secrete testosterone. In males, the paramesonephric ducts degenerate, and the mesonephric ducts develop the accessory ducts and glands of the reproductive system. Until two months before birth, the testes are located in the pelvic cavity. Once stimulated by testosterone the testes then descend into the

scrotum. The scrotum is an external structure developed from labioscrotal swelling due to testosterone influence. This hormone also causes the genital tubercle to enlarge, forming the penis and the urogenital fold to form the ventral aspect of the penis.

At week eight, female structures begin to develop. Primordial germ cells that are XX develop the ovaries that eventually descend into the pelvic cavity to be stopped by the broad ligament at the pelvic brim. Degeneration of the mesonephric ducts occurs, and the paramesonephric ducts develop into the oviduct and female genital tract. In the absence of testosterone, the genital tubercle develops into the clitoris, the urethral groove remains open to develop into the vestibule, the urogenital fold becomes the labia minora, and the labioscrotal swellings form into the labia majora.

Genetic Disorders

Genetic Disorders

Pregnancy is a complex process and can sometimes result in the development of an abnormal fetus. In fact, nearly 3% of all deliveries are associated with a major birth defect. Abnormal fetal development can result from either developmental factors or genetic disorders.

Developmental Factors

Developmental factors are associated with 10% of all birth defects. Developmental factors can be due to a teratogenic agent, infectious agent (e.g. rubella virus, herpes virus), or metabolic disorder (eg. diabetes, phenylketonuria). Teratogenic agent exposure is seen in less than 50% of all birth defect cases. Information important to teratogenic exposure defects includes the agent type, dose, length of exposure, and developmental stage at the time of exposure.

Genetic Disorders

Genetic disorders are a much more common cause of abnormal fetal development and are associated with 20-25% of birth defects. In fact, 42% of spontaneously aborted fetuses are associated with a genetic disorder. Genetic disorders are also the cause of nearly 4000 different human diseases.

A genetic disorder is a medical condition caused by abnormalities in an individual's DNA, which can result in various health problems. In a typical human, there are 22 pairs of autosomes (non-sex chromosomes) and 1 pair of sex chromosomes, with one chromosome from each pair inherited from each parent. When a genetic disorder occurs, there is an alteration in either the number or structure of these chromosomes. This alteration can affect either the autosomes or the sex chromosomes. However, it is worth noting that autosomal disorders often tend to be associated with more severe birth defects than abnormalities in the sex chromosomes. In the following discussion, we will explore several types of genetic number disorders.

Chromosomal Number Disorders

There are several different types of chromosomal number disorders that can occur amongst the autosomes. The general term for an abnormal number of chromosomes is **aneuploidy**. If **nondisjunction** occurs, where chromosomes fail to separate or disjoin properly, two specific types of aneuploidy can

occur: trisomy and monosomy. **Trisomy** occurs when there is an extra chromosome ($2n+1$), while **monosomy** results from a missing chromosome ($2n-1$), where 'n' represents the number of chromosomes in a single set.

Monosomy

Monosomy, which involves the presence of a single copy of a particular chromosome in a diploid organism, typically leads to severe developmental abnormalities and is often not compatible with life. This situation can indeed result in spontaneous abortion (miscarriage) in many cases because the embryo's genetic imbalance and missing genetic material are not viable.

Trisomy

Trisomy, which involves the presence of an extra copy of a particular chromosome, is more commonly observed and can lead to genetic disorders. Some trisomies, such as Trisomy 21 (Down's Syndrome), are survivable, although they can result in a range of developmental and health challenges. The impact of trisomy can vary depending on the specific chromosome involved and the extent of the genetic imbalance.

Two additional important terms related to chromosomal number disorders are polyploidy and triploidy.

Polyploidy

Polyploidy refers to the presence of more than two complete sets of chromosomes in an organism's cells. While most humans are diploid, meaning they have two sets of chromosomes ($2n$), polyploid organisms may have three (triploid, $3n$), four (tetraploid, $4n$), or more sets of chromosomes. Polyploidy is relatively less common in animals, including humans.

Triploidy

Triploidy is a specific type of polyploidy where an individual has three sets of chromosomes ($3n$). It often results from the fertilization of an egg by two sperm cells or, less commonly, from the fusion of a haploid sperm with a diploid egg. Triploidy is associated with significant developmental abnormalities and usually leads to miscarriage or stillbirth in humans. It's considered a type of **aneuploidy**, where there is an abnormal number of chromosomes.

An Example of Autosomal Chromosome Number Disorder

Down's Syndrome

Down's Syndrome can result from two main causes:

- **Nondisjunction:** Trisomy 21 is typically related to nondisjunction during meiotic division. If nondisjunction is related to the maternal side, **maternal age** is a significant factor. Older mothers have a higher risk of giving birth to a child with Trisomy 21 because the chances of nondisjunction increase with maternal age.
- **Translocation:** This form of Down's Syndrome is less common and occurs when a portion of chromosome 21 breaks off and attaches itself to another chromosome (usually chromosome 14). This type can be hereditary and may involve a rearrangement of genetic material between different chromosomes. It's important to note that translocation Down's Syndrome is not typically associated with maternal age but may have a **familial genetic** component.

Down's Syndrome can result in a variety of physical, intellectual, and developmental expressions. The specific features and their degree of severity may differ from one individual to another.

Sex Chromosome Number Disorders

There are several chromosomal number disorders that can occur in the sex chromosomes. We will go over some of the most common.

Klinefelter Syndrome

Klinefelter syndrome is caused by the presence of an additional X sex chromosome. For instance, 47XXY. It is caused by maternal meiotic nondisjunction, the incidence of which increases with maternal age. There is no increased risk of reoccurrence: if it happens once, it is not likely to happen again. Rather, it is the same risk of occurrence as in the general population.

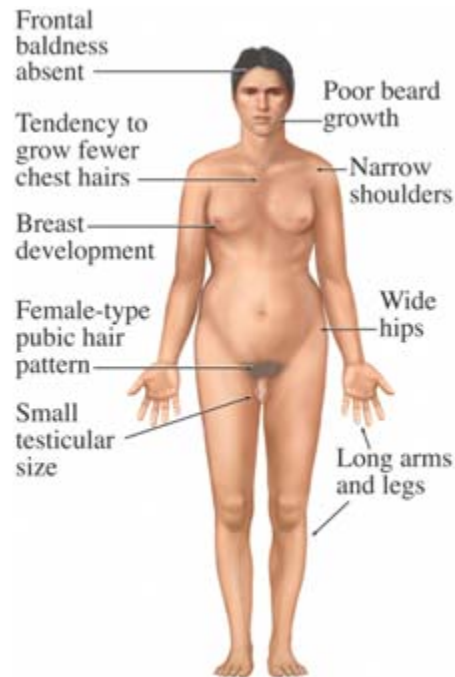


Figure 1. The symptoms of Klinefelter's syndrome in a human male.

Klinefelter syndrome affects 1 in 1,000 newborn boys and is most often undiagnosed preceding puberty. Those with Klinefelter syndrome tend to be taller than average with incomplete musculature, enlarged breasts, small testis, decreased testosterone production, male infertility, and decreased motor skills and dexterity (Figure 1). However, those with Klinefelter Syndrome can usually be sexually active without much issue.

Turner's Syndrome

Turner's syndrome is caused by having only one X chromosome (45, X). Like Klinefelter's syndrome, there is no increased risk of reoccurrence of Turner's syndrome. Turner's syndrome may be noted at birth and affects 1 in 2,500 newborn girls.

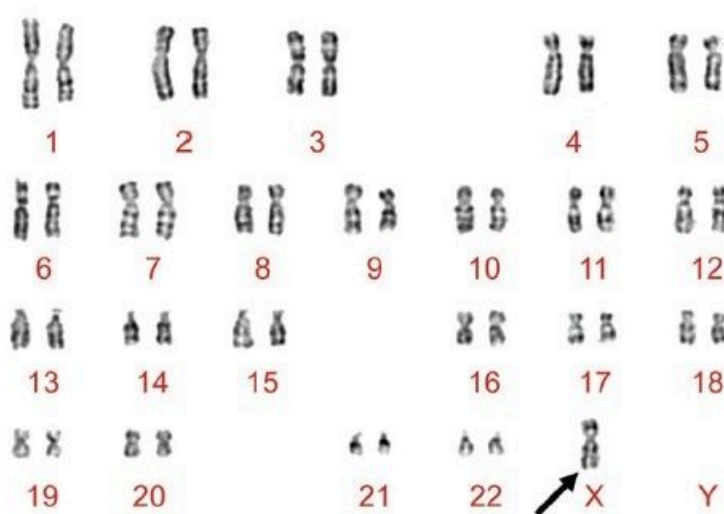


Figure 2. Turner syndrome karyotype demonstrating 45, X chromosome complement.

It results in improper development of the reproductive system, including degeneration of ovaries into fibrous streaks. It also results in a lack of development at puberty, minimal breast bud development, and is the most common cause of primary amenorrhea. Those with Turner's syndrome often have short heights, a webbed neck, widely separated nipples, a malformation of the aorta, and excess fluid in the extremities resulting from malfunctioning of the lymphatic system.

True Hermaphrodite

True hermaphrodites are quite rare. They result from the fusion of two sperm, one of which carries an X chromosome and the other a Y chromosome. Half of the cells in a true hermaphrodite are XX and the

other half are XY. Thus, a true hermaphrodite will have both ovarian and testicular development. Thus, the genitalia of a true hermaphrodite will be ambiguous.

Pseudohermaphrodite

A pseudohermaphrodite will have gonads matching that of their chromosomal sex. However, the external genitalia will not match that of their chromosomal sex. Rather, the external genitalia will match those of the opposite sex.

A male pseudohermaphrodite is an individual who possesses testes as their gonads but has external genitalia that appear female. This condition is often associated with disorders like **Androgen Insensitivity Syndrome (AIS)** and **defective testosterone synthesis**. AIS is a genetic condition in which the body is unable to respond to androgens (male sex hormones), resulting in incomplete masculinization of the external genitalia and the development of female secondary sexual characteristics. Defects in testosterone synthesis can further contribute to the feminization of external genitalia in individuals who have male gonads. These conditions highlight the complexity of sex development and the role of hormonal factors in determining an individual's sexual characteristics.

A female pseudohermaphrodite is an individual with ovaries as their gonads, who has male external genitalia that have formed due to the fusion of the labia majora. This condition is often associated with an increase in androgen hormones. Female pseudohermaphrodites account for approximately 50% of all human intersexuality cases.

The development of a female pseudohermaphrodite is often attributed to hormonal influences during pregnancy, including the excess production of androgens, such as in the case of **adrenal hyperplasia**, or the **administration of hormones like progesterone** to the mother. These hormonal imbalances or exposures during fetal development can disrupt the typical differentiation of the external genitalia, leading to the formation of male-like genitalia in individuals with female gonads.

Image Sources

- **Figure 1.** “Klinefelter’s syndrome” is from Third Age, shared via [Wikimedia Commons](#), licensed [CC BY SA 3.0](#).
- **Figure 2.** “Turner syndrome karyotype” is from [Suttur, Mysore, Krishnamurthy, and Nallur](#), licensed [CC BY 4.0](#).

Prenatal Diagnosis and Genetic Counseling

Prenatal diagnosis and genetic counseling usually help detect genetic disorders and birth defects before the third trimester. This early diagnosis gives the parent the option to terminate their pregnancy early if necessary, or at the very least, the time to emotionally acclimate to the situation. It also improves the management of pregnancy, delivery, and the neonatal period accordingly.

Methods and procedures for prenatal diagnosis

Genetic History

Obtaining and documenting a thorough genetic history alone is important. It can help narrow down and possibly rule out chances of a genetic disorder or birth defect. Health status and history of first-, second-, and third-degree relatives will be gathered. Any history of repetitive spontaneous miscarriage, stillbirths, and anomalous fetuses will be recorded. The ethnicities, ages, and any drug exposure of the mother and father will also be recorded.

Fetal Ultrasound

Fetal ultrasounds are a harmless process to the fetus and mother. It is important to have ultrasounds of the fetus taken during the pregnancy, as this gives the doctors the ability to analyze the developmental progress of the fetus. At 5 weeks post-conception, a vaginal probe can be performed. At 12 weeks post-conception an abdominal ultrasound can be performed. A fetal ultrasound could detect fetal size, growth, number of fetuses, viability, and amniotic fluid volume. Ultrasounds done at centers specialized in the care of high-risk pregnancies can also help detect structural abnormalities in the many organs.

Maternal Serum Alpha Fetoprotein (AFP)

Maternal serum alpha fetoprotein (MSAFP) levels can be tested at 15 to 17 weeks of gestation. A low level of MSAFP is indicative of an increased risk of trisomy in the fetus. A high level of MSAFP is indicative of a risk for open defects of the neural tube or GI tract.

Genetic Amniocentesis

Genetic amniocentesis is a procedure that involves puncturing the amniotic sac with a needle to gather a sample of fetal cells from the amniotic fluid. This procedure can be performed from 16 to 18 weeks of gestation via the withdrawal of about 30 mL of amniotic fluid. The fetal cells gathered can be used for fetal DNA analysis and fetal karyotype. A pregnant woman should be offered this option if she meets the following criteria: 35 years or older, history of multiple miscarriages, family history of genetic disease, or abnormal levels of MSAFP detected.

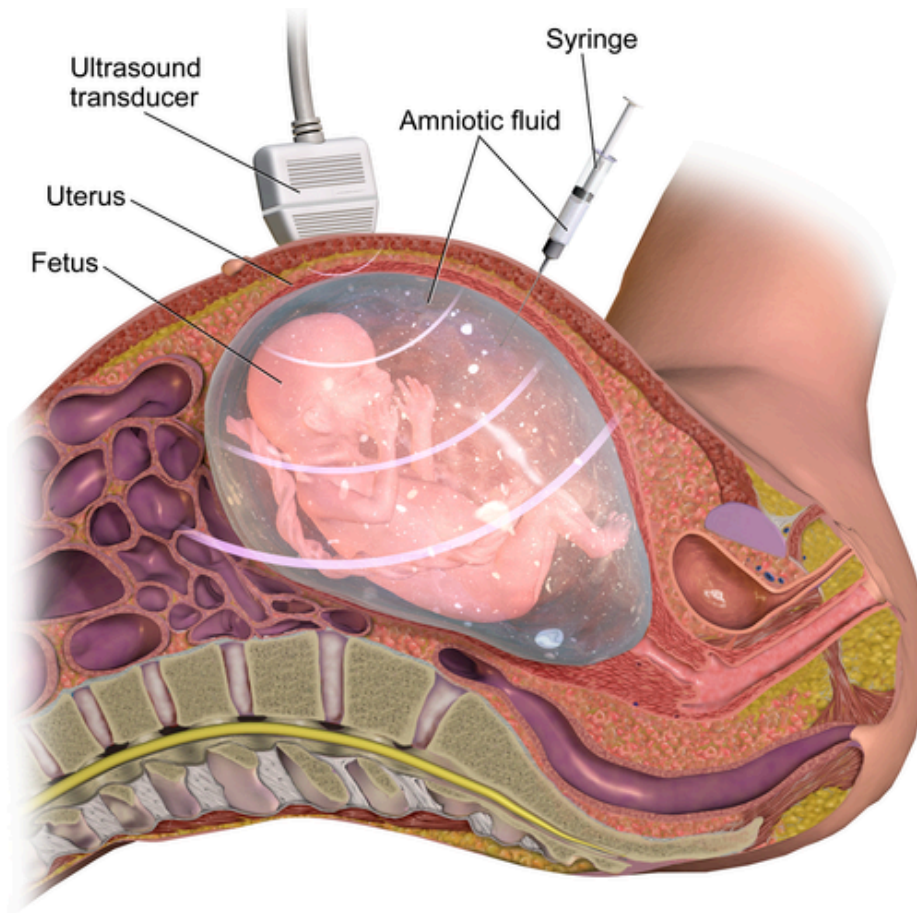


Figure 1. Amniocentesis.

Amniocentesis is an invasive and high-risk procedure. It may lead to the leakage of amniotic fluid, spontaneous labor, or puncture of the fetus. The incidence of spontaneous abortion may result in approximately 1/200 to 1/400 of cases after amniocentesis.

Chorionic Villi Sampling (CVS)

Chorionic villi sampling (CVS) involves either a catheter being inserted into the cervix guided by a trans-vaginal ultrasound, or a needle inserted trans-abdominally into the placenta to aspirate chorionic villi cells from the placenta. CVS can be performed from 9 to 12 weeks of gestation, but it is associated with a 1% risk of fetal loss. The aspirated cells can be used for fetal DNA analysis and fetal karyotype; however, the results may be ambiguous.

Percutaneous Umbilical Cord Blood Sampling (PUBS)

Percutaneous umbilical cord blood sampling (PUBS) is a procedure involving an ultrasound-guided needle which is punctured into the fetal umbilical blood vessels to get a sample of fetal blood. This fetal blood sample can be used for fetal DNA analysis, fetal karyotype, fetal blood count, or assessment of the fetal acid base status. This procedure can be done at 18 weeks of gestation, but has a fairly high risk of fetal loss at 2-3%.

Genetic Council and Termination of Pregnancy

There are many different genetic disorders to look out for when it comes to pregnancy. It is very important for a pregnant woman or even a woman thinking of getting pregnant to get genetic counseling as well as prenatal diagnosis when necessary. This empowers the prospective parents to make informed decisions if a genetic disorder is identified, including whether to continue or terminate the pregnancy.

It is important to recognize that there are legal regulations in place governing an individual's choice to terminate a pregnancy at different stages of gestation. During the first trimester, the decision to terminate lies entirely with the pregnant woman and her physician. During the second trimester, there may be state regulations imposed with respect to the mother's health. During the third trimester, abortion may be regulated by the state unless the mother's health is of concern.

These regulations highlight the significance of early diagnosis in pregnancy, allowing sufficient time for thoughtful decision-making, taking into account both medical and legal considerations.

Take Home Message

- Ultrasounds are a safe and easy method to detect fetal anomalies.
 - CVS has the highest risk of losing a fetus during prenatal diagnosis of congenital malformation.
-

Image Sources

- **Figure 1.** “Amniocentesis” is from [Bruce Blaus via Wikimedia](#), licensed [CC BY SA 4.0](#).

Normal Pregnancy

Endocrinology of Pregnancy

Pregnancy is the period during which a fetus develops inside the womb. Pregnancy usually lasts about 40 weeks, or just over 9 months, as measured from the last menstrual period to delivery. These 40 weeks are broken up into trimesters. The first trimester starts on the first day of the pregnant person's last period and ends on the last day of week 12. The second trimester starts on week 13 and ends on the last day of week 27. Finally, the third trimester starts on the first day of week 28 and ends sometime during the 38th to 40th week of pregnancy.

Hormonal Changes During Pregnancy

Hormones play a major role throughout pregnancy. Different hormonal levels and types are found in pregnant women compared to non-pregnant women. Some of these hormones are newly found in the pregnant individual, or their levels may be varied compared to non-pregnant people. The sources of these hormones may come from the newly developed placenta, the fetus, or from the mother's tissues.

The hormones that have been detected during pregnancy have been studied to distinguish between normal and abnormal pregnancies, detect fetal conditions, and identify any complications that may occur during pregnancy. Significant hormones present during pregnancy are listed below.

Human Chorionic Gonadotropin (HCG)

This hormone is produced by the syncytiotrophoblast of the placenta. HCG can be detected as early as six to eight days following conception and throughout the rest of the pregnancy. It can be detected in blood first, and is later noticeable in urine. HCG has a specific pattern during pregnancy. Its levels rise rapidly 8 days after conception, doubling every two to three days and reaching its peak at 80 days after fertilization. Then it drops to a plateau for the remainder of the pregnancy.

HCG is used to detect both normal uterine and ectopic pregnancies. Its pattern and peak run at a much lower level in ectopic pregnancies than in normal pregnancies, and in conditions with poor placental function or fetal demise. HCG levels will be duplicated in multiple pregnancies with multiple placenta, and can reach very high levels in trophoblastic neoplasms. During pregnancy, HCG functions to prompt the corpus luteum to produce progesterone, and prompts male fetus' Leydig cells to produce testosterone. HCG is similar to LH hormones and also helps induce ovulation.

Human placental Lactogen (hPL)

Like HCG, this hormone is also produced by the syncytiotrophoblast of the placenta. hPL is formed as early as three weeks post conception and can be detected in a maternal bloodstream around six weeks post conception. hPL rises steadily in the first and second trimesters, and it disappears rapidly after delivery. hPL is a growth hormone, and its level correlates directly to the weight of the fetus and placenta. Very high maternal levels of hPL are often associated with multiple gestation, twins, or triplets.

The hPL has a significant effect on fetal development. It favors protein synthesis and ensures a source of amino acids for fetal growth. It promotes the formation of insulin-like growth factors and induces the growth of all fetal tissues.

In the mother, hPL has a diabetogenic effect. It induces insulin resistance and carbohydrate intolerance, inhibiting glucose uptake in the mother. This can lead to the elevation of maternal blood sugar in those predisposed to high blood sugar.

Prolactin

Prolactin is a hormone produced by both the mother's and fetus's pituitary glands. It is also produced by the decidualized tissues of the maternal endometrium. Prolactin can be detected in maternal serum as well as maternal amniotic fluid. Maternal prolactin levels rise to a maximum of 100ng/ml near term.

Prolactin stimulates the production of milk by the mammary glands and prepares them for lactation after birth. The decidual prolactin secreted by the endometrium is thought to be important for electrolyte regulation of the amniotic fluids.

Higher levels of prolactin in a non-pregnant woman would indicate a hyperactive or tumor function of the pituitary gland.

Alpha-fetoprotein (AFP)

AFP is a hormone produced by the yolk sac and liver of the fetus. It can be detected in the amniotic fluid at five to twelve weeks following conception and in the pregnant woman's bloodstream around 15 to 17 weeks following conception. The exact role of alpha-fetoprotein remains a question, but it is known that it is mainly found in large amounts in the fetus's central nervous system (CNS). Abnormal direct contact of fetal CNS with the amniotic fluid, as in neural tube defect, results in elevated amniotic fluid and maternal blood levels of alpha-fetoprotein. In pregnancies involving a fetus with Down's syndrome (DS), the level of alpha-fetoprotein measured in maternal serum and amniotic fluid is reduced to about 70 percent of the level attained in typical pregnancies.

Progesterone

Progesterone is produced by the corpus luteum follicle. In a non-conception cycle, progesterone is produced during ovulation at an amount of up to 25 mg per day. In the conception cycle, during the luteal phase, hCG stimulates more progesterone secretion by the corpus luteum and progesterone levels increase gradually and slowly. Progesterone continues to be produced by the corpus luteum until 7 to 10 weeks of gestation. Around 10 weeks post-conception, the placenta takes form and supplements the corpus luteum. Progesterone continues to be produced by the placenta until the delivery time. Its level is increased rapidly during pregnancy until the time of parturition up to -250mg/day. A very high level of progesterone could be indicative of multiple gestation.

Progesterone is required for decidualization and preparation of the endometrium for implantation. It also helps to maintain a relaxed myometrium until labor occurs. Interruption of progesterone levels or its action may lead to the termination of pregnancy. Progesterone serves as a major precursor to critical fetal hormones during pregnancy. The fetal adrenal cortex glands use placental progesterone as a precursor for corticosteroids, and fetus testes use placental progesterone as a precursor for testosterone.

Estrogen

The estrogen hormone is unique in that the mother, placenta, and fetus produce it. Estriol, the primary form of estrogen involved in pregnancy, is synthesized in the second trimester and is produced in increasing amounts until term. This surge in estriol is what causes the total amount of estrogen to increase 1,000 times more than that of a non-pregnant woman. Estrogen levels are indicative of both a fetus's and placenta's well-being. If the level of estrogen appears low or does not increase from the second trimester until term as expected, this may indicate pregnancy complications, fetal demise, or fetal growth retardation.

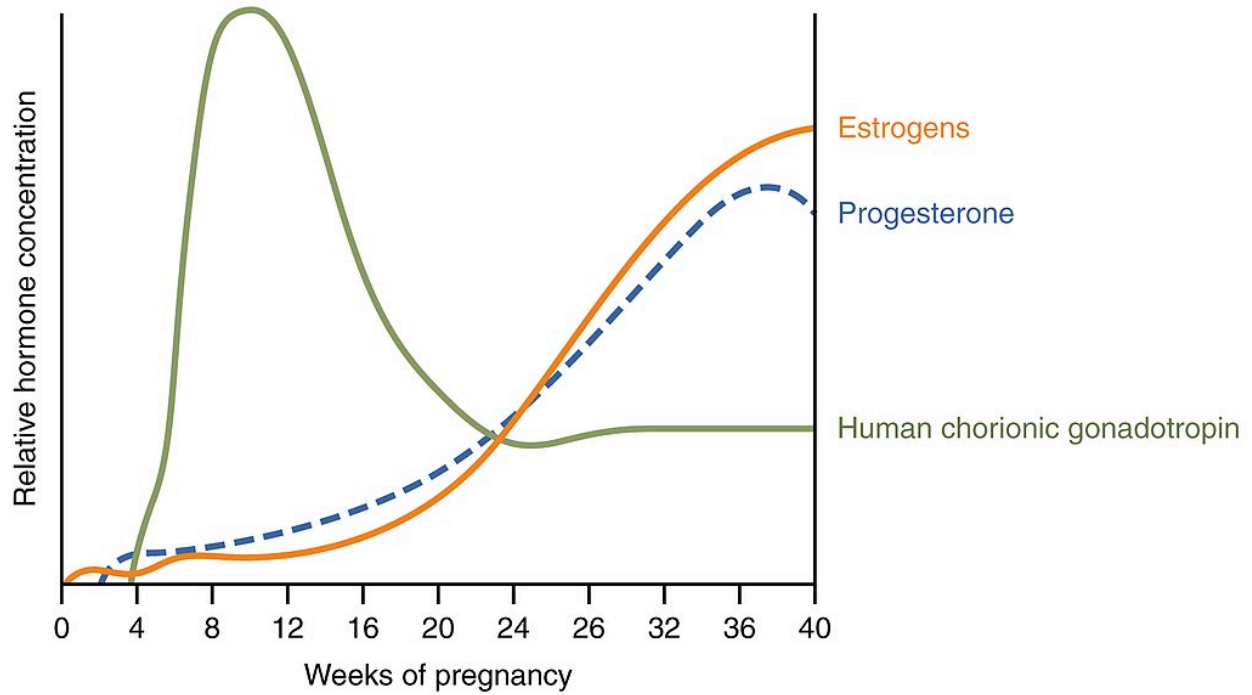


Figure 1. Hormones during pregnancy.

Image Sources

- **Figure 1.** “Hormones during pregnancy” is from [OpenStax Anatomy & Physiology](https://openstax.org/books/anatomy-and-physiology/pages/1-introduction), licensed [CC BY 4.0](https://creativecommons.org/licenses/by/4.0/). Access for free at <https://openstax.org/books/anatomy-and-physiology/pages/1-introduction>

Physiological Changes During Pregnancy

Hematologic System

Along with changes to the endocrine system during pregnancy, some changes occur to other systems within the pregnant individual. For instance, there are several changes to the hematologic system. These changes include a 50% increase in the volume of plasma, a 30% increase in the volume of red blood cells (RBC's), and an increase in the amount of white blood cells (WBC's). These changes to the hematologic system serve several purposes. The overall increase in the volume of blood circulating is in preparation for the expected loss of blood during the birthing process. However, the 50% increase in plasma versus the 30% increase in RBC's results in the level of hemoglobin being 10.5 to 11.5 g/dl, resulting in dilutional anemia.¹

Another change to the hematologic system includes an increase in factors that help with coagulation. A fibrin degradation inhibitor is also synthesized by the placenta. All of these changes to the hematologic system contribute to pregnancy being in a state of hypercoagulability, making pregnant women more prone to thromboembolic disease.

Cardiovascular System

Pregnant individuals also have altered cardiovascular systems. Increases in stroke volume and pulse can lead to an overall increase in cardiac output. Conversely, peripheral vascular resistance is decreased, and in the second trimester there is often a decrease in blood pressure. Approximately 9 out of 10 pregnant individuals have an S3 gallop and systolic ejection murmur.

Respiratory System

The respiratory system also undergoes several changes during pregnancy. The increase in estrogen causes the mucosa of the nasal cavity to swell with excess mucous and fluid. The respiratory rate and

1. Gandhi MH, Gupta V. Physiology, Maternal Blood. In: StatPearls. Treasure Island (FL): StatPearls Publishing; 2023. <https://www.ncbi.nlm.nih.gov/books/NBK557783/>

tidal volume are greater than normal, and the residual volume is less than normal. Toward the later stages of pregnancy, it is normal for a woman to experience some difficulty breathing. One of the possible causes of dyspnea is the enlarged uterus pressing up against the lungs, reducing the volume of oxygen that can be exchanged in one breath.²

Renal System

Several changes to the renal system occur during pregnancy as well. For instance, the glomerular filtration rate (GFR) and renal plasma flow (RPF) rise by 50 and 75 percent, respectively. The amount of plasma filtered of creatinine per unit time also rises. The kidneys themselves also get larger and, in turn, weigh more. The ureters, which connect the kidneys to the bladder, also enlarge, making their central cavity wider than normal. The bladder, which usually resides in the pelvis, becomes situated in the abdomen. Due to all these changes in the renal system, it is more common for pregnant people to have to urinate more often and sometimes not have total control over urination. Pregnant individuals are also more prone to kidney infection, and, if they are involved in a traumatic incident affecting the abdomen, a ruptured bladder will often be observed.

Gastrointestinal (GI) System

During pregnancy, the levels of progesterone are increased, impacting the movement of waste through the GI system. This can lead to constipation. Increased progesterone can also cause nausea and vomiting during the early stages of pregnancy, and in more severe cases may lead to hyperemesis gravidarum. It is also common for pregnant women to feel as if they are not hungry even though they have not eaten for a while. Due to the stomach and esophagus being pushed upon and moved by the enlargement of the uterus, many pregnant people will also experience heartburn during pregnancy.

Integumentary System

Noticeable changes to the integumentary system, especially around the abdominal area, occur during pregnancy. As the uterus grows with the developing fetus, stress is put on the surrounding skin, often resulting in stretch marks. This is due to the collagen in the skin parting and can result in an itchy feeling

2. McCormack, Meredith C., and Robert A. Wise. "Respiratory Physiology in Pregnancy." *Humana Press*, 2009, pp. 19–26. https://doi.org/10.1007/978-1-59745-445-2_2.

in the affected area. The last 20 weeks of pregnancy are when women will start to see striae gravidarum on their stomach, which post-pregnancy will become striae albicans (stretch marks).

Reproductive System

The last major system that changes during pregnancy is the reproductive system. The uterus goes from 70 gm to 1100 gm, often causing lower back and leg pain. The amount of blood supplying the uterus also increases from around 2-3% to approximately 10-15% during pregnancy. The cervix and vagina also change during pregnancy. They receive more blood flow, which can be seen via **Chadwick's sign**, a bluish discoloration in the area. There is also an increase in the amount of mucus secreted by the cervix. Due to these changes, the vagina is often more sensitive, which is noticeable during sexual intercourse while pregnant. The breasts also change during pregnancy as they get larger, more sensitive, and often somewhat lumpy. The nipple and areola will also become noticeably darker in color.

Nutrition and Pregnancy

There are several nutritional factors that need to be taken into consideration for pregnant individuals. For instance, as the weight of the pregnant person correlates with the weight of the infant at birth, it is concerning if the mother does not gain weight during pregnancy. The normal amount of weight to gain depends on the individual's weight before pregnancy. For instance, a person who is within the normal weight range for their size should gain about 20 lbs during pregnancy, whereas an underweight individual should gain around 30 lbs, and an overweight individual should only gain about 16 lbs. This weight gain comes from multiple things: the fetus (7.5 lbs), the placenta and amniotic fluid (3 lbs), the blood (4 lbs), the breasts (1–2 lbs), and fat (4 lbs).

Daily dietary requirements for common nutrients

It is also very important that a pregnant person consumes adequate amounts of calories, proteins, minerals, and vitamins to maintain the health of their developing baby.

Calories and Protein intake

When it comes to calories, pregnant women need to increase their daily caloric intake by about 15%, which means that weight loss programs are not an option during pregnancy. As for protein, the pregnant person should intake 1.3 mg more per day than usual.

Minerals

For minerals, there are two that are important during pregnancy and need to be ingested at a certain level per day: iron and calcium. 30 to 60 mg of **iron** needs to be consumed per day, and a daily amount of 1200 mg of **calcium** needs to be consumed, which will help with leg cramps. Note that the amount of sodium ingested may remain as normal.

Vitamins

Vitamins are also important during pregnancy. One vitamin in particular should be regulated. This vitamin is folate, and it should be consumed at an amount of 1 mg per day during pregnancy. This vitamin is necessary to make heme. If a woman has previously had a child with an abnormal neural

tube, to prevent this issue in any further pregnancies, the mother will need to consume 4 mg of folate per day for a month preceding pregnancy and three months during pregnancy.

Lifestyle During Pregnancy

Physical Activities, Immunizations, and Dental Care

Pregnant individuals will need to limit some of their activities and adhere to new ways of living for their health; for example, only participating in mild exercise rather than anything too strenuous. Sexual activities may continue if there are no complications in the pregnancy that require restricted sexual activity for the safety of the fetus and mother. When it comes to water, there are no restrictions other than refraining from water sports at high velocity which could result in injury. Douching is also acceptable if there are no contradicting complications with the pregnancy.

Those who are pregnant should make sure to have at least one general dental care appointment, and they are not restricted from getting any specific dental work done. Immunizations are allowed and getting or maintaining regular vaccinations is encouraged as long as they are not live virus vaccines. When it comes to traveling, there are no restrictions; however, the pregnant person will need to stretch and walk around every two hours.

Smoking

Another change of lifestyle that a pregnant person may need to make is to stop smoking. Smoking decreases the size of the fetus and makes perinatal death more common. Smoking increases the amount of carbon monoxide a person inhales, which competes for binding of hemoglobin with oxygen, leading to lower oxygen saturation levels. This can cause issues in the health and development of the growing fetus as well as the health of the mother. The nicotine in cigarettes also causes blood vessels to narrow, which lessens the perfusion of the placenta. Finally, smoking makes it difficult for women to maintain and gain the necessary weight because it curbs hunger.

Alcohol

Pregnant individuals should not drink alcohol as this can cause damage to the developing fetus. A major consequence of drinking alcohol while pregnant is **fetal alcohol syndrome**. This occurs in those whose mothers consumed three or more ounces of alcohol in a day while pregnant. Health complications related to fetal alcohol syndrome are abnormal facial structuring, heart abnormalities, behavioral issues, and mental disabilities.

Medications

Medication must be taken with care during pregnancy. The fetus will be exposed to anything that the mother consumes. In the case of medication, it is important to discuss different risks associated with medications and whether the reward is worth the risk. There is one specific medicine that should be avoided during pregnancy: **aspirin**. This is because ingesting aspirin can push back the time of labor, restrict the growth of the fetus, separate the placenta from the uterine wall, and remove bilirubin from protein binding sites.

Health Check-ups

For a pregnant individual to ensure that they and their baby are healthy throughout pregnancy, it is important that they maintain regular doctor appointments. From conception up until 32 weeks, it is recommended that the pregnant person have a doctor's visit once a month. From 32 to 36 weeks, they are recommended to have a doctor's appointment every other week. Finally, from 36 weeks until the birth of the child, the pregnant person is expected to have a doctor's appointment once a week. At these appointments, the doctor will check for multiple things including contractions of the uterus, heart rate and movement of the fetus, amniotic fluid volume discrepancies, and bleeding from the vagina.

In summary, pregnancy is a complex process. It includes several different stages which involve changes in levels of different hormones. The change in different hormone levels serves many purposes but can also cause several complications. During pregnancy, a several changes in lifestyle may be required to ensure the health of both the mother and their baby. The pregnant individual may need to change several aspects of her life, from what she consumes to how strenuously she exercises.

Labor and Birth

Labor and Birth

Labor involves the continuous dilation of the cervix accompanied by contractions over several different stages. Usually, labor comes at the end of a woman's third term of pregnancy; however, under certain circumstances, it may come earlier. The form and fashion that labor occurs in is not universal to every person. Some mothers will give birth naturally, and others will undergo a cesarean birth. In addition, some mothers will opt for medicine to reduce pain during pregnancy while others will not. We will be discussing the following: signs of labor, hormones of labor, stages of labor, natural versus cesarean birth, medications and tools used during labor, and complications associated with labor and birth.

Signs of Labor

There are several indications of the onset of labor. These signs are mainly observed in the cervix, abdomen, and vagina. Some of these signs are commonly known such as "water breaking" and Braxton Hicks contractions, but there are several other more subtle signs. Here, we will go through each of the most common signs that labor is imminent.

Lightening

Lightening is the process of the baby moving inferiorly, or deeper, into the pelvis. The time at which this happens varies between individuals. For instance, in those that are having their first child, lightening can occur several weeks or just a few hours before labor. Conversely, in those that have already had a child, lightening occurs very close to labor. Indications of lightening are increased pressure in the pelvis, increased frequency of urination, and decreased shortness of breath.

Braxton Hicks

Braxton Hicks contractions do *not* indicate that labor is imminent. In fact, Braxton Hicks are known as "false labor pains." Braxton Hicks do not come at a regular pace but are somewhat sporadic. They also do not cause dilation of the cervix like true contractions do.

Rupture of Membranes (ROM)

Rupture of Membranes is the technical phrase for saying that a mother's water has broken. The phrase

“water has broken” means that the amniotic sac has ruptured, releasing fluid and indicating that labor is imminent. Not all women experience this the same. Some experience a burst of water, and others have a slow stream or trickle. Once a mother’s water has broken, it is important that she immediately go to the hospital to minimize the risk of infection.

Cervical Changes

The cervix undergoes several changes to get ready for delivery through the birthing canal. These changes include ripening, effacement, and dilation. **Ripening** is cervical softening, **effacement** is cervical thinning, and **dilation** is cervical opening. Dilation is a term commonly heard throughout pregnancy as the doctor measures the amount of dilation to the cervix over time until full dilation has been reached and it is time to deliver.

Additional Signs

There are several additional signs of labor. For instance, vaginal discharge tends to thicken as labor nears. This is due to the mucous plug from the cervix getting displaced into the vaginal canal, and is often an indication that the cervix is starting to dilate. Sometimes, there is some blood in this discharge, which is common. Another sign of labor is **nesting**, a set of behaviors from the mother that involve an excess need to organize, clean, and prepare everything before the baby arrives. Additionally, a slight drop in weight can signal labor.

Hormones of Labor

There are several hormones involved in the onset of labor. Here, we will go through each of the hormones and what purpose they serve. **Corticotropin-Releasing Hormone (CHR)** is a hormone released from the hypothalamus during labor stress that supports the development of the hormone **Corticotropin (ACTH)**. ACTH is produced by the pituitary gland, and stimulates cortisol production by the adrenal glands, which leads to the release of estrogen that prepares the mother for childbirth. **DHEA-sulfate**, which is a steroid, comes into play in the last stage of pregnancy as an estrogen substrate.

Other more common hormones that come into play in preparation for labor are estrogen, progesterone, and prostaglandins. Estrogen is produced by the ovaries and fetal placenta. It helps to soften the cervix in preparation for dilation, and is involved in the manufacture of prostaglandins that participate in uterine muscle contraction. Progesterone is produced by the placenta and inhibits uterine contractions. A significant drop in progesterone during pregnancy is what initiates labor at the placental site by no longer inhibiting uterine contractions.

The ratio of estrogen to progesterone is important during labor. Prostaglandins are produced by tissue cells, and their main function is to help promote labor by stimulating the uterus muscle to contract. Fetal cortisol levels are also important, as they stimulate the production of enzymes that help regulate the development of placental alternatives, such as the lungs and liver, after birth.¹

Lastly, oxytocin is a hormone produced by the pituitary gland and placenta. Oxytocin release helps stimulate the contraction of the uterine muscles and increase prostaglandin release to further increase contractions and dilate the cervix. There are oxytocin receptors located in both the myometrium and parietal decidua of the uterus. There are several different types of oxytocin that play a role in labor: placental, pituitary, and synthetic. Labor initiation is assisted by placental oxytocin. Contractions and prostaglandin release are further coaxed by a physician when they administer synthetic oxytocin. Upon every contraction, pituitary oxytocin is released and assists in decreasing pain, anxiety, and stress in the person going through labor. In fact, this form of oxytocin stimulates the parasympathetic nervous system to offset the sympathetic nervous system during labor. Pituitary oxytocin also increases activity in the reward centers of the brain which produces feelings of pleasure.²

-
1. Liggins, Graham Collingwood. "The Role of the Hypothalamic-pituitary-adrenal Axis in Preparing the Fetus for Birth." *American Journal of Obstetrics and Gynecology*, vol. 182, no. 2, Feb. 2000, pp. 475-77. [https://doi.org/10.1016/s0002-9378\(00\)70241-9](https://doi.org/10.1016/s0002-9378(00)70241-9).
 2. Dawood M.Y., Raghavan, K.S., Pociask, C., & Fuchs, F. "Oxytocin in human pregnancy and parturition." *Obstet Gynecol.* vol. 51, no. 2, Feb. 1978, pp. 138-43. PMID: 622223.

Stages of Labor

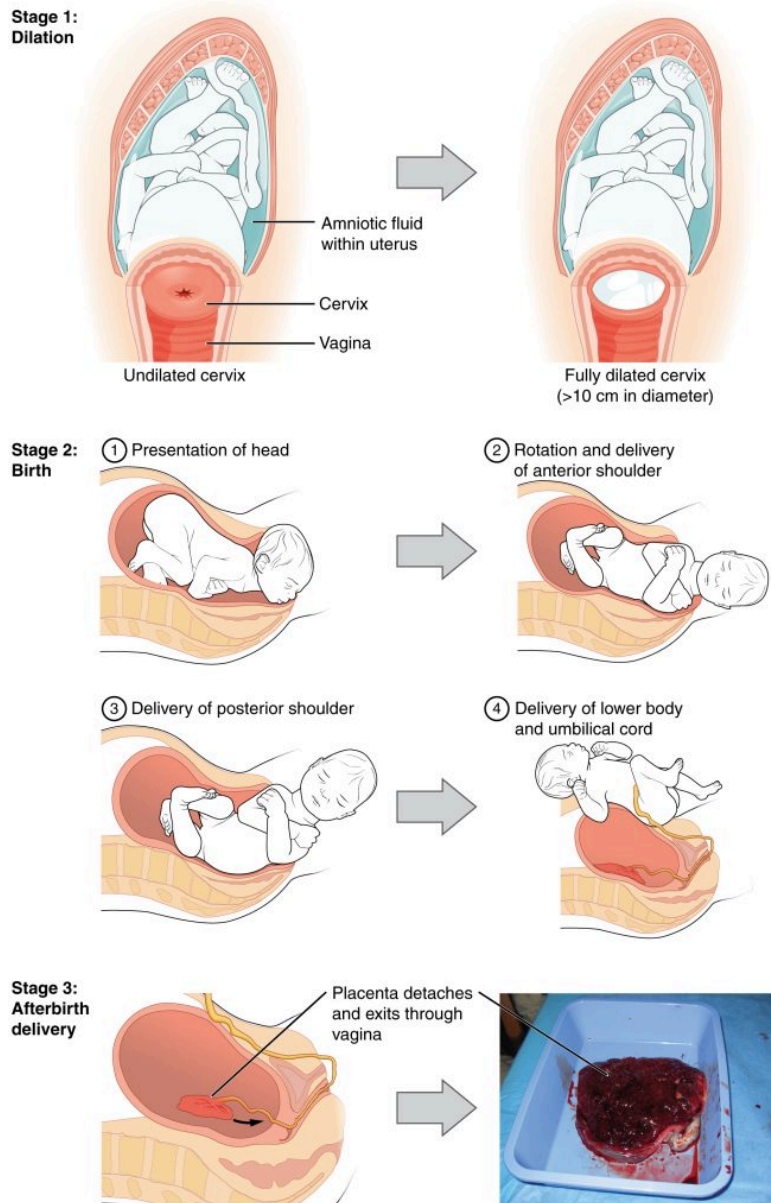


Figure 1. Stages of Childbirth.

Stage 1: Cervical Effacement and Dilation

The first stage of labor is the longest, lasting approximately 20 hours for individuals who are giving birth for the first time and less than 14 hours for those who have given birth before. The first stage of labor is composed of two different phases: latent and active.

During the **latent phase**, the cervix dilates from 0 to 6 cm. During the **active phase**, the cervix dilates from 6 to 10 cm (full dilation). If there is a halt to cervical change or contractions after 4 or 6 hours respectively, this is a sign of labor complications.

Stage 2: Expulsion of the Fetus

The second stage of labor involves the process of the fetus exiting through the birthing canal. This stage can last approximately 2 hours for those who are giving birth for the first time or up to 30 minutes for those who have given birth before. During this stage, contractions typically last for 1 minute with 2 to 3 minute periods of relaxation in between. The baby will start to “crown” during this stage, with the head approaching the exterior of the birthing canal. Since the skull bones of the baby are not fused, their head may appear cone-shaped. In a normal birth, the baby’s head will be delivered first, followed by its shoulders. Once the shoulders pass through, the rest of the body should deliver easily as the shoulders are the widest part to pass through the birthing canal. Once the baby has been delivered, it will take its first breath or be stimulated to cry and take its first breath. In an uncomplicated delivery, the umbilical cord will be cut within minutes of delivery. If the delivery had complications, there will be a further assessment on whether or not to cut the umbilical cord right away.

Stage 3: Birthing of the Placenta

The third and final stage of labor involves the delivery of the placenta. This process usually takes no longer than 30 minutes to complete. If it takes longer than 30 minutes, there is an increased risk of hemorrhage. During this stage, oxytocin is still at work stimulating contractions of the uterus to get the placenta to detach and exit the birthing canal. There are several signs that the placental birthing process has started, and these include the elongation of the umbilical cord, fundus position, and a short increase in blood flow from vagina. Once the placenta has been birthed, there are several options for how it might be used. For example, the hemopoietic cells of the placenta might be used in cancer patients. It can also be frozen and used if the baby falls ill later on.

Different Types of Birth

Natural Birth

A natural birth is a birth through the vagina with no additional medical procedures. Natural birth can occur with or without medicine. Without medicine, breathing and relaxation techniques can be used to relax the mother as much as possible during labor. Medicine can also be used during a natural birth, such as an epidural, to reduce pain for the mother. There are several risks associated with a natural birth, which include but are not limited to tearing, infection, and loss of blood. There are additional risks in labor when an epidural is used, including infection, nerve damage, and seizures.

Cesarean Birth

An alternative to a natural birth is a cesarean birth (or c-section), which involves medical intervention via abdominal and uterine surgery to remove the baby from the womb. There are several reasons why a cesarean birth may be performed instead of a natural birth, including but not limited to unprogressive labor, baby in distress, abnormal baby positioning, multiple gestation birth, umbilical cord prolapse, placental issues, a previous c-section, or health concerns. Cesarean birth is a surgical procedure and it does have some more risk associated with it than a natural birth. This risk includes infection, clotting, blood loss (hemorrhage), and associated surgical injuries. However, cesarean births are not uncommon. In fact, in 2021, there were 1,174,545 deliveries via c-section and 2,486,856 deliveries via natural birth.³

Image Sources

- **Figure 1.** “Stages of Childbirth” is from [OpenStax Anatomy & Physiology](#), licensed [CC BY 4.0](#). Access for free at <https://openstax.org/books/anatomy-and-physiology/pages/1-introduction>

3. Centers for Disease Control and Prevention. Birth-Methods of delivery. National Center for Health Statistics. 2021. <https://www.cdc.gov/nchs/fastats/delivery.htm>

Labor Medication and Tools

Epidurals Medication

An **epidural** is an optional medication that a mother can be administered to reduce the pain of labor. It is important to note that an epidural reduces labor pains but does not completely block sensation as it allows the mother to still feel contractions. An epidural is administered via injection into the epidural space surrounding the spinal cord (See Figure 1).

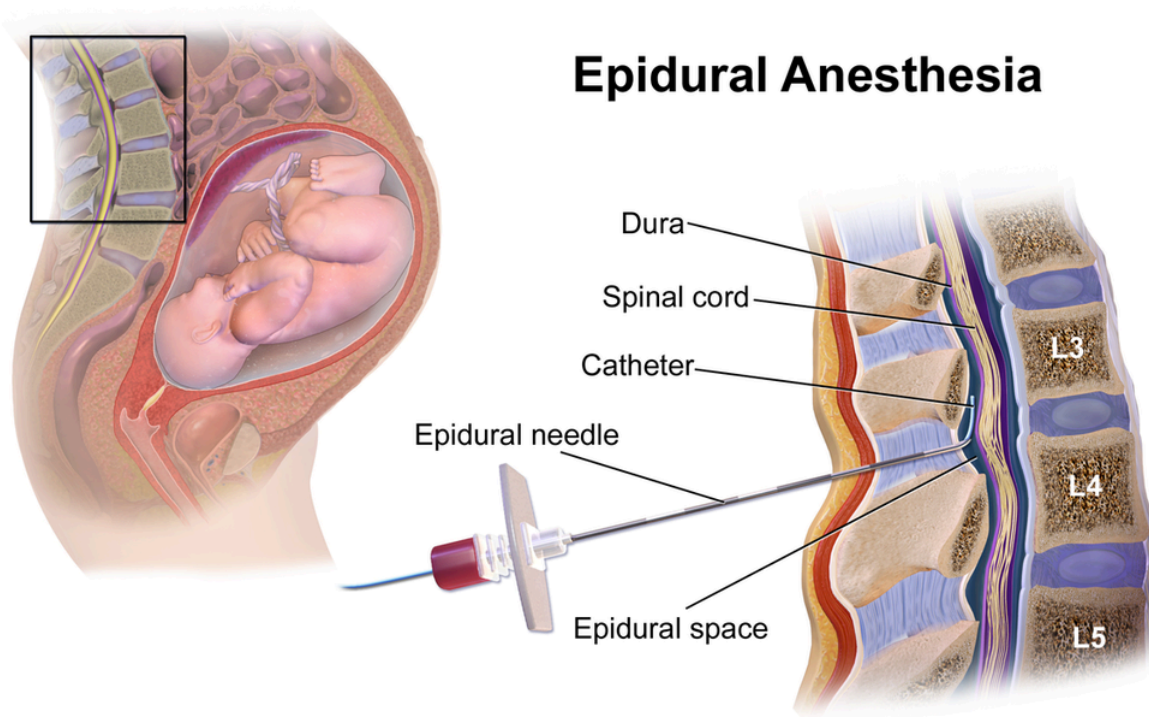


Figure 1. Epidural Anesthesia.

The epidural will become effective approximately 10 to 20 minutes following administration and is long-lasting to provide pain relief throughout labor. The composition of an epidural is a combination of anesthetics and opioids such as bupivacaine, ropivacaine, and fentanyl. There are several additional risks that come with using an epidural. These risks include increased difficulty in pushing, lowered blood pressure, halted labor, and difficulty walking due to numbness.

Other Pain-Reducing Methods

There are several other options besides an epidural to manage pain during labor. These options include spinal block, combined spinal-epidural block, intravenous pain medication, and pudendal block. The spinal block provides nearly instant relief from pain and lasts from 1 to 2 hours. Spinal blocks are normally seen in an elected c-section. The most common medications used in a spinal block are bupivacaine, morphine, and fentanyl. Another method to minimize the pain of the mother during labor is called a combined spinal-epidural block, and it is a combination of a spinal block and epidural where it provides nearly immediate relief that is long-lasting.

Another method that can be used for pain relief during labor is by administering intravenous pain medication. This method is often used when the mother is unable to do a spinal block or epidural. One of the downsides of intravenous pain medication is that it can cause drowsiness in the mother and baby. Once a mother reaches the stage of labor where they are pushing, they have the option for a pudendal block. This block reduces feeling in the birth canal and is often combined with other pain relief methods. A pudendal block is commonly composed of lidocaine or chlorprocaine.

The Use of Birth Tools

Several tools can also be used to help with the vaginal birthing process. Two common tools used are forceps and a vacuum. Forceps are tongs shaped to fit snugly around the baby's head and help to gently guide the baby out of the birthing canal. A vacuum is as it sounds. It is a vacuum that ends in a cup that suctions to the baby's head, allowing for the baby to be gently guided out of the birthing canal. These tools are not always used during labor. They are reserved for several situations, including if the baby is not well-positioned or has discontinued movement along the birth canal, if the mother is no longer able to continue pushing, if the baby's heartbeat alters, or if the mother has an underlying medical condition that could cause issues. In all these cases, manual tools can be used to prevent the need to move to a surgical birth, such as a cesarean. Note that there are several risks associated with the use of manual tools. For instance, the mother can suffer lacerations to the vagina, anus, and urethra, which could lead to further blood loss. The mother may also not be able to control her bladder for a time following the use of tools. Finally, there are some risks to the baby including facial injuries, skull fracture, facial muscle weakness, and additional bleeding.

Image Sources

- **Figure 1.** “Epidural Anesthesia” is from [Bruce Blaus via Wikimedia Commons](#), licensed [CC BY SA 4.0](#).

Complications During Pregnancy and Labor

There are several factors that can put a pregnancy at increased risk for labor and birth complications. These risk factors include a premature birthing history, a multiple gestation pregnancy, a significantly young or old mother, or drug use during pregnancy. Here we will talk about the different types of complications that can occur, their risk factors, and how to best handle these complications.

Abnormal Labor Duration

Prolonged Labor

A prolonged labor is when labor is taking more than 20 hours. Prolonged labor can be due to several reasons, including the mother having a small pelvis, the baby being overly large, the mother's cervix dilating very slowly, and stress on the mother. This issue is most concerning once the active stages of labor have been reached. There are several strategies to move a prolonged labor along, including labor inducers, relaxation methods, and the use of a c-section.

Rapid labor

Also known as a precipitous labor, **rapid labor** is when all stages of labor are undergone and finished within 3 to 5 hours. Several factors may be indicative of a rapid labor, including the baby being small, uterine contractions being very efficient, the mother having rapid labor previously, and the birth being exceptionally strong. A rapid labor has several risks associated with it. For instance, there is an increase in the possibility of tearing and laceration of the vagina and cervix during labor. As a result, there can be excess hemorrhaging from the vagina and cervix. This hemorrhaging can result in the mother going into shock. Further, because rapid labor happens so fast, another complication is that the mother may not make it to the hospital in time to give birth and may instead have her baby in an unclean environment, which can increase the risk of infection for the baby. The baby may also undergo aspiration of amniotic fluid, which can put the baby in respiratory distress and be life-threatening.

Preterm Labor

A preterm labor is when labor occurs between week 20 and week 37 of pregnancy. There are several indications of preterm labor, including a multiple gestation pregnancy, a short cervix, a history of preterm labor, and drug use during pregnancy. A preterm labor can pose several risks to both mother

and baby. These risks include a premature birth of a baby resulting in low birth weight, respiratory issues, immature organs, and vision issues. A premature birth also puts the baby at a higher risk of having cerebral palsy, learning disorders, and behavioral issues. In the worst cases, a premature death can mean the death of a baby. To avoid preterm labor, it is important that the mother regularly visits their doctor, does not use drugs, and gives ample time between pregnancies. There are also several ways to stop preterm labor from occurring, including medication and manually closing the cervical opening so nothing can pass through; however, these methods may or may not work.

Abnormal Fetal Positioning

There are several fetal positions that are considered abnormal and deemed a complication during labor and birth. These positions include fetal dystocia, breech, occiput posterior, shoulder dystocia, umbilical cord prolapse, and fetal distress. Fetal dystocia is when the fetus is smaller or larger than normal or in an abnormal position. This can lead to the umbilical cord being compressed. Breech position encapsulates complete, incomplete, frank, or footling breech. A complete breech is when the baby's feet are closest to the birth canal and the knees are bent. An incomplete breech is when one of the baby's knees is bent and close to the birth canal. A frank breech is when the baby's legs are folded up near their face, and their bottom is nearest the birth canal. A footling breech is when the baby's feet are closest to the birth canal and delivered first. Occiput posterior positioning is the most common abnormal fetal positioning and is when the occipital bone of the fetus is touching the mother's sacrum.

Shoulder dystocia is when the head of the baby has exited the birth canal, but the shoulders get stuck. In this case, an episiotomy is an option to get the baby free. This positioning can result in injury such as fracture, brachial plexus, or brain injury to the baby if forced through. Another abnormal position is umbilical cord prolapse, which is when the umbilical cord comes through the birth canal before the fetus. Umbilical cord prolapse is a dangerous position, and a little under 10 percent of cases lead to fetal death. Lastly, fetal distress is when there is an irregular heartbeat coming from the baby. This is common in pregnancies at or past 42 weeks.

Preeclampsia

Preeclampsia is a special name for a case where a mother has high blood pressure during pregnancy. For women with initially normal blood pressure, preeclampsia usually presents around 20 weeks or more into the pregnancy. It is important for a mother and her doctor to keep on the lookout for signs of preeclampsia, including high blood pressure, excess protein in the urine, and edema in the legs. Preeclampsia is a pregnancy risk for both mother and baby, so if it does occur, it is important that the

mother get oral or intravenous medication to stabilize the baby for birth. Often, a mother will need to consider the risk versus the reward of delivering early or going to term.

Miscarriage

A miscarriage is when a woman's pregnancy terminates before 20 weeks. Miscarriages are the most common way to lose a pregnancy, with 10 to 20 percent of pregnancies resulting in miscarriage. Miscarriage usually occurs due to poor or irregular development of the fetus or due to the age and health of the mother. High fetal cortisol levels can also increase the chances of a miscarriage occurring. Although there are medications to lessen complications of a miscarriage, there are no known ways to stop a miscarriage once it has been initiated. There are several ways to indicate that a miscarriage may be imminent, including the passage of fluid, blood, or tissue out of the vagina, abdominal pain, or lower back pain. Miscarriages are one of the most physically and emotionally distressing processes for a mother to endure.

Still Birth

A still birth is when there is fetal death inside the mother following 20 weeks of pregnancy. Usually, a still birth happens some time before labor, but sometimes it can occur during labor. Although still births are not quite as common as miscarriages, they do occur in approximately 1 out of 175 labors.¹ Several factors that can increase the chance of a still birth pregnancy are obesity, high blood pressure, diabetes, and drug use. However, still births can also occur in women without any of these risk factors. Once a still birth is found, it is critical it is removed to prevent any further complication or infection. There are several ways to remove the fetus, depending on how far along the pregnancy is. Some removal methods include cervical dilation and evacuation, induction of labor, and c-section.

Excessive Hemorrhaging

Hemorrhaging can be a major issue related to labor and birth since a mother can have complications, including shock if they lose too much blood. During a normal vaginal birth, the mother typically loses around 500 mL of blood. During a c-section birth, a mother usually loses around 1000 mL of blood. Any more blood loss than this is considered excessive hemorrhaging. Most of this bleeding occurs after the

1. Centers for Disease Control and Prevention. *What is Stillbirth?* <https://www.cdc.gov/ncbddd/stillbirth/facts.html>

placenta has been delivered. Certain situations put a mother at higher risk for excessive hemorrhage, including placental abruption, prolonged labor, assisted delivery, infection, blood clotting disorders, and obesity.

Vaginal and Anal Tearing

Labor and birth can result in vaginal or anal tearing. The risk of tearing is increased in situations such as rapid labor or an abnormally large baby. There are also several different degrees of tearing. A first-degree tear is when the skin between the vagina and rectum tears. A second-degree tear is when there is a tearing of the perineal muscles. A third-degree is when there is a tearing of the perineal muscles and anal sphincter. Finally, a fourth-degree tear is when there is a tearing of the mucous membrane lining the rectum. Tearing can cause several issues for the mother, including fecal incontinence and dyspareunia.

Amniotic Fluid Embolism

An amniotic fluid embolism is when the amniotic fluid of cells from the fetus enter the mother's bloodstream. The immune system reacts to these foreign bodies, leading to irregular clotting in the lungs and blood vessels. An amniotic fluid embolism is a rare but very serious condition, as it can lead to the death of the mother.

Conclusion

In conclusion, labor and birth can vary from one situation to another. There are multiple signs of impending labor, and there are also false signs of labor. Labor has several different stages and involves the birthing of both the baby and the placenta. The birthing process has several different forms, including natural and cesarean births. During labor and the birthing process, there are several medications and tools that can be used to help reduce pain and ease the process along more smoothly. Lastly, labor and birth are often somewhat long and strenuous processes with many different variables that can lead to complications.

Contraception

Natural Contraception

There are many options for contraception and family planning. There are many options, such as natural methods, barrier methods, hormonal oral contraception, implants and injections, mechanical insertions of IUD, and/or the use of surgical sterilization. These methods have different effectiveness, side effects, and relations to the act of intercourse.

Natural Family Planning

Natural family planning is used in many ways, mostly by being aware of fertile times called **fertility awareness methods**. Abstaining from intercourse during fertile times can be calculated by tracking cycles and the lifespan of the ovum and sperm. For example, knowing that near ovulation, cervical secretion increases and becomes clear and stretchy and the cervix becomes softer and wider. After ovulation, basal body temperature increases due to progesterone.

During the first year, the failure rate of natural family planning methods is 25%, with only a 1-9% of failure rate with perfect use. Most couples use instructors initially to help interpret their fertility signs. Fertility signs are more difficult to interpret in those who have recently been on hormonal contraception, are near menarche or menopause, or who are just postpartum or post-breastfeeding.

Coitus Interruptus

Coitus interruptus is the withdrawal method, when the male withdraws the penis before ejaculation. This is the primary means of contraception in at least 2% of couples in the United States. The failure rate is 4% during the first year, with a 19% failure rate with typical use. This method has no cost and no side effects. This method requires high motivation and does not protect from STDs.

Barrier Contraception Methods

Barrier contraceptive methods include condoms, diaphragms, cervical caps, and vaginal spermicides.

Male Condoms

Male condoms are safe, effective, inexpensive, and have reversible effects. Male condoms that successfully prevent pregnancy are manufactured using latex, lamb caecum, or polyurethane. For patients with latex allergies, polyurethane condoms are a good alternative. Latex condoms should only be used with water-based lubricants (KY jelly, spermicidal agents). Oil-based lubricants such as lotion, petroleum jelly, or massage oil may damage the condom. Male condoms prevent pregnancy and protect from STDs (cervical cancer). In the first year, failure rates with condom use are 3% with perfect use.¹ Failures occur more frequently when condoms are not used than when condoms are used with malfunctions such as slippage or breakage.

Female Condoms

Female condoms are loose plastic pouches that line the vagina, with the inner end covering the cervix and the outer end covering the labia. Female condoms should also be used with spermicides. They can be inserted 8 hours before intercourse and should be removed after coitus before the female stands up. The failure rate of female condoms is between 5-20%. The use of female condoms lowers the transmission of STDs.

1. Majra, JP. "Use of condoms: clarifying the message." *Indian journal of community medicin : official publication of Indian Association of Preventive & Social Medicine* vol. 35,2 (2010): 362. doi:10.4103/0970-0218.66860

Female Diaphragm

The female diaphragm contraceptive is made of latex and has a dome shape. When using the diaphragm, it rests between the posterior aspect of the symphysis pubis and the posterior fornix of the vagina, covering the anterior vaginal wall and the cervix. It prevents sperm penetration into the cervical canal and cervical mucous from neutralizing vaginal acidity, which is hostile to sperm.

Female diaphragms should also be used with spermicidal cream. When using a diaphragm, it is best to use the largest comfortable size. It should be placed up to 6 hours before intercourse and left in place for 6 hours after intercourse. It should be worn for no more than 24 hours total. The diaphragm has a 20% failure rate with typical use. The diaphragm has a 6% failure rate over the first year with perfect use. The effects are reversible and have few side effects, such as urinary tract infections, but do not protect against STDs.



Figure 1. Contraceptive diaphragm.

Cervical Caps

Cervical caps have the same effectiveness as the diaphragm but are harder to fit because they are held by suction. Cervical caps must be left in place for at least 6 hours after intercourse and used with spermicides. They can be left in place for 36 hours total. The cervical cap has a 20% failure rate with typical use. The cervical cap has a 6% failure rate over the first year with perfect use.

Vaginal Sponge

Vaginal sponges are used with polyurethane and nonoxynol 9. They release spermicides during coitus, absorb sperm, and block the entrance of the cervix canal. They can be inserted up to 24 hours before intercourse but must be removed after 30 hours. The failure rate of vaginal sponges is 10-15%.

Spermicides

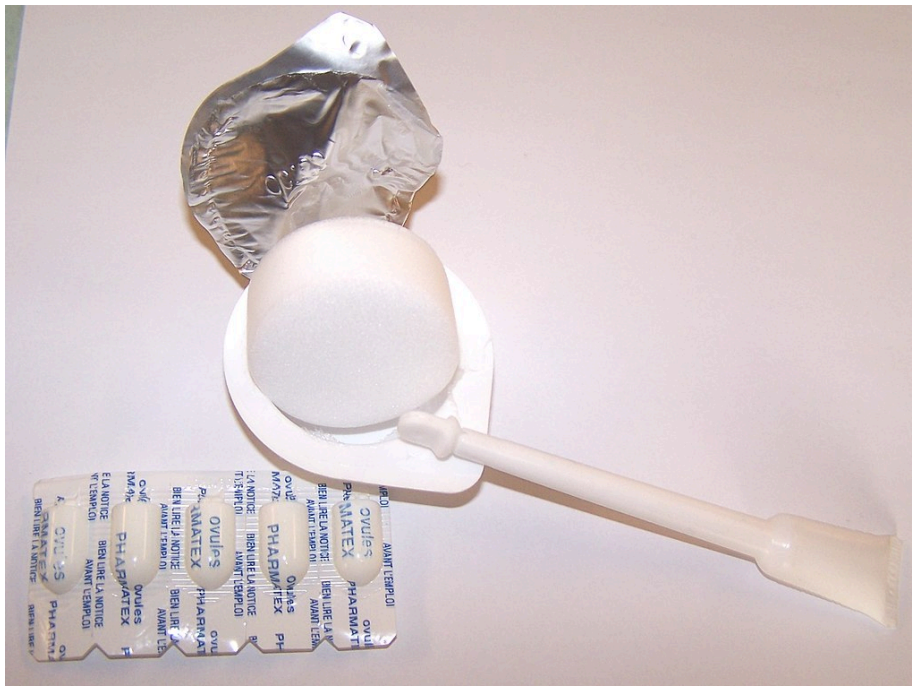

Figure 2. Three types of spermicide including vaginal sponge and spermicidal cream.

Spermicides contain a gel, foam, cream, film, suppository base, and an active chemical agent such as nonoxynol-9. Spermicides can be used alone, with the diaphragm or cervical cap. The failure rate is 5-25% within the first year of use. Spermicide must be used at least 15 minutes before intercourse to allow it to adequately disperse. They are accessible, easy to use, safe, and enhance the efficiency of other forms of contraception. Decrease the risk of STDs by approximately 25%. Spermicides are not good options for patients who are allergic to any spermicide component or if the vaginal anatomy is abnormal.

Image Sources

- **Figure 1.** “Contraceptive diaphragm” is from [HiGyn via Wikimedia Commons](#), licensed [CC BY SA 4.0](#).
- **Figure 2.** “Spermicide” is from [Ceridwen via Wikimedia Commons](#), licensed [CC BY SA 2.0 France](#).

Oral Contraception Pills (OCP)

Oral contraceptives are used by approximately 14 million women in the United States; about 60 million women worldwide use oral contraceptive pills. Oral contraceptive pills contain both estrogen and progesterin. The action of oral contraceptives include the blockage of ovulation, the thickening of cervical mucus, and a flat and inactive endometrium. Oral contraceptives block ovulation through the **hypthalamic suppression** of FSH, LH and the LH surge. The thickening of cervical mucus is done to decrease sperm motility and penetration. The flat and inactive endometrium is to prevent implantation. There is also a decrease in tubal transport and sperm capacitation.

Side Effects of OCP

The most common side effect of OCP is breakthrough bleeding, bleeding outside of the menstrual cycle caused by estrogen and progesterone deficiency or missing pills. Side effects caused by excess estrogen may include nausea, water retention, and vascular headaches. Side effects caused by excess progestin may include an increase in appetite and weight gain, acne, depression, and pill amenorrhea. Newer anti-androgenic progestins may experience a decrease in libido. Most women experience mild to no side effects with low-dose formulations of less than 50 micrograms of ethinyl estradiol.

Complications of OCP

Complications of OCP may include cardiovascular complications, neoplasia or post-pill amenorrhea. Cardiovascular complications include myocardial infarction, cerebrovascular accident, or thromboembolism. Cardiovascular complications take place in women over 35 who smoke and in some women who have underlying medical problems, particularly with conditions predisposing to thrombosis. Neoplasia can take place in the breast, cervix, endometrium, and ovary. Post-pill amenorrhea occurs in up to 3% of women who discontinue OCP.

Absolute Contraindications to Oral Contraceptives

Contraindications to oral contraceptives related to estrogen components include various conditions related to the heart, liver, lungs, and cancer. Individuals should be cautious when taking oral contraceptives if they have thromboembolic disorder, cerebrovascular accident, coronary artery disease, impaired liver function, hepatic adenoma, breast cancer, endometrial cancer, other estrogen-dependent

malignancies, pregnancy, undiagnosed vaginal bleeding, or if they smoke more than 15 cigarettes per day over the age of 35. Taking oral contraceptives with these conditions can lead to further damage or more risks.

Alternative Methods of Hormonal Administration

Transdermal patch (Ortho-Evra)

Transdermal patches are an alternative method for administering combined estrogen and progestin that increases the compliance of the patient and might lower the user-failure rate of combination hormonal contraception. The transdermal patch (Ortho-Evra) are patches that are changed weekly. They are administered for 3 weeks with one week off. The use of transdermal patches has decreased since recent studies suggest they lead to an increase in cardiovascular events when compared to traditional COCs.

Vaginal ring (Nuvaring)

A contraceptive vaginal ring (Nuvaring) is an intravaginal ring that releases continuous progestin and estrogen. They are changed monthly with three weeks of ring use and one week off. The hormones that are released from the contraceptive vaginal ring are absorbed through the vaginal epithelium.

Only Progestin Administration

Progestin administration works by inhibiting ovulation, thickening the cervical mucous, and causing atrophy of the endometrial lining. Progestin can be administered in oral, injectable, or subdermal implants on a continuous basis. Women have to be compulsive for the maximum efficiency as there is no pill-free interval. The implantable or injectable forms are effective and lack the requirement of responsibility.

Progestin administration is less effective and is associated with more breakthrough bleeding than the combination of estrogen and progestin. It does have fewer serious side effects, as progestin does not promote clotting, which would not cause a risk of heart attacks or stroke regardless of age or smoking status. Progestin administration also lowers HDL but has not been shown to contribute clinically to heart disease. Although there are fewer serious side effects, the FDA requires the same thrombosis precautions on all hormonal contraceptives.

Depo-Provera

Depo-Provera is 150 mg of a medroxyprogesterone acetate in a sustained release suspension that is administered every three months. This method is extremely effective, with a failure rate of 0.3% during the first year of use. Amenorrhea is experienced in 50% of women who use depo-provera after one year of use. The most common side effects are irregular bleeding and an increase in weight. When depo-provera is no longer being used, the average return to fertility is 9-10 months.

Subdermal Implant

Implanon is a subdermal implant that is a single rod that releases etonogestrel. Implanon is very effective for three years. The mechanisms of action in this subdermal implant are very similar to the other progestin-only methods. The most common reason for discontinuation of the implant is irregular bleeding.

Intrauterine Devices

Intrauterine devices (IUDs) stay in the uterine cavity and are made of plastic, polyethylene contain barium sulfate, to make them radiographic. A sterile spermicidal inflammatory reaction is caused so very few sperm can reach the oviducts, not allowing fertilization to occur. If fertilization did occur, implantation is prohibited due to the effect that IUDs have on the endometrium.

Types of intrauterine devices

- **ParaGard** is a copper-containing IUD with an efficacy lasting 10 years.
- **Mirena** is a progestin-releasing IUD which must be replaced every 5 years. The failure rates of intrauterine devices range from 1-3%. Experienced physicians can have lower failure rates due to performing correct high-fundal insertion.

Advantages of IUD

The advantages of intrauterine devices include the ability to return to fertility after removal and are also an option for women who are unable to take estrogen. They also lack systemic side effects, have immediate high efficacy, single motivational act, and lack interference with lactation.

Disadvantages of IUD

The disadvantages of an IUD are they can lead to a slight increase risk of infection during the month following insertion, an increase in menstrual bleeding and cramps, and expulsion and perforation of the uterine fundus.

Pregnancy with Intrauterine Devices

Pregnancies can occur with the IUD in place, which causes a 55% risk of spontaneous abortion. IUDs also lead to a higher chance of having an ectopic pregnancy. Prematurity is also a risk of about 12-15% while the IUD is in situ.

Intrauterine Devices Contraindications

Contraindications to intrauterine devices include various conditions related to pregnancy, pelvic inflammatory disease, and the uterus. You are to be cautious when using an IUD if you are suspected of being pregnant or known to be and should have it removed. You should also be cautious if you have had a previous ectopic pregnancy. You should also be wary of using an IUD if you are at high risk for pelvic inflammatory disease or a partner that has multiple sexual partners. Other conditions include untreated acute cervicitis or vaginitis, conditions that have increased susceptibility to infections, postpartum or postabortal endometritis in the past 3 months, undiagnosed abnormal genital bleeding, distorted uterine cavity from leiomyomata, uterine anomalies or known or suspected cervical or uterine malignancy, including an unresolved abnormal Pap smear.

Surgical Sterilization

Female Sterilization

Surgical sterilization is either ligation or microfilament placement in the tubal region. Bilateral tubal ligation can be performed postpartum through a small intraumbilical incision or a laparoscope. A modern alternative to interval tubal occlusion involves the use of hysteroscopic transcervical microfilament placement. About 10.7 million women in the United States rely on sterilization. The failure rate for 1,000 procedures over 10 years is 18.5 pregnancies.

Surgical sterilization is permanent, effective, and has no side effects. The mortality rate of the procedure is 1-2/100,000. The risk of ectopic pregnancy is elevated at 33%, a notable increase compared to the 1.5% risk seen in the general population.

Regret occurs more often for younger patients or during postpartum when the patient's life situation changes. Tubal reversals are only successful in 43-80% of cases and are expensive. If a patient wishes to conceive after tubal ligation, in vitro fertilization is a successful option but can be very expensive.

Male Sterilization

Surgical sterilization in men is accomplished through a procedure known as vasectomy. Vasectomy is recognized for its superior safety, cost-effectiveness, and efficacy when compared to female sterilization. In the United States, approximately 4.2 million men opt for vasectomy as their sterilization method of choice. The one-year failure rate for vasectomy stands impressively low at 0.15%, in contrast to the 0.5% failure rate associated with female sterilization. Additionally, male sterilization costs roughly one-third of the expenses incurred with bilateral tubal ligation. Vasectomies are routinely performed in an office setting under local anesthesia. To confirm the success of the procedure, two negative semen analyses are typically required.

Contraception in Specialized Conditions

Postpartum Contraception

Postpartum contraception includes breastfeeding, fertility awareness, and barrier methods. Breastfeeding women have a longer period of postpartum infertility than women who do not breastfeed. Women who solely breastfeed and experience amenorrhea are 98% protected from pregnancy for six months following the delivery.

Fertility awareness is another method used to support postpartum contraception, but it may be difficult to practice until regular cycles are reestablished. Barrier methods such as the diaphragm and cervical cap are good contraception methods for lactating women but should be refit at six weeks postpartum. An IUD can be placed immediately postpartum but is normally placed 6-8 weeks postpartum or sterilization.

Combined birth control pills are not good options for lactating women as estrogen decreases milk supply but can be taken after three months. Women who are not breastfeeding should wait to start taking combination birth control pills until 2-3 weeks postpartum due to the risk of thromboembolism.

Emergency Contraception

Emergency contraception methods are used after intercourse to prevent pregnancy. For emergency contraception to be effective, it has to be used within 72 hours of unprotected intercourse taking place, but effectiveness is greater the sooner the contraceptive method is used. It may decrease the chance of pregnancy by 75%. Emergency contraception can be used for up to 5 days after intercourse with some efficacy but not as effective as taking it within the first 72 hours.

Morning after pill

The morning-after pill is intended for use following unprotected intercourse during the ovulation period. It contains a substantial dosage of steroids, which serves to disrupt the endometrial lining after ovulation has taken place, preventing the implantation of a fertilized egg.

Plan B

Plan B is an emergency contraception available “behind the counter,” without a prescription, for those 18 years of age or older. If you are under 18 years old, you require a prescription to take Plan B. Levonorgestrel are two 0.75 mg pills that can be taken together or taken 12 hours apart for five days.

Preven

Preven is a product with ethinyl estradiol and levonorgestrel, approved for emergency contraception. The side effects of emergency contraceptives include nausea, abdominal pain, fatigue, headache, bleeding irregularities, breast tenderness, diarrhea, and vomiting.

This method of contraception is not as effective as other methods of contraception. A pregnancy test should be used if there is any delay in the menstruation cycle. If pregnancy occurs, therapeutic abortion is recommended as it has a teratogenic effect.

Paragard IUD

Paragard is another form of emergency contraception that can be inserted within five days of unprotected intercourse.

Contraception Summary

Numerous contraception options are available to accommodate various preferences and requirements. When contemplating family planning, it is crucial to assess both the potential side effects of each method and the level of protection sought. Engaging in discussions with medical professionals can assist in determining the most suitable contraception method for individual circumstances.

Male Contraceptive Hormonal Vaccines

Hormonal vaccines for male contraception are a developing area of research and innovation in the field of birth control. These vaccines aim to provide a temporary method of contraception for men, similar to how hormonal methods are available for women. The vaccines would typically contain hormones that affect the male reproductive system, such as testosterone, follicle-stimulating hormone (FSH), or luteinizing hormone (LH).

The concept behind these vaccines is to suppress sperm production and reduce the likelihood of fertilization. Hormonal vaccines for male contraception are still in the experimental and clinical trial stages, and their effectiveness, safety, and long-term implications are actively being studied. If successfully developed and approved, they would offer men an additional option for family planning and contraception.

However, it is important to note that as of 2023, no hormonal vaccine for male contraception has been widely approved for public use. Progress in this field may have occurred since that time, so it's advisable to check the latest developments and consult healthcare professionals for the most up-to-date information on male contraception options.

Infertility

Infertility

Infertility is defined as the inability to achieve conception (pregnancy) after engaging in regular sexual intercourse without using contraception for a duration of 12 months. This period allows for a reasonable amount of time for conception to occur naturally.

In couples who are trying to conceive naturally, approximately 50% of them achieve pregnancy after trying for about three months. However, the chances of conception increase with time, and by the end of 12 months, about 92% of couples will have successfully conceived.

Types of Infertility

- **Primary Infertility:** This refers to cases where a couple has never experienced a successful conception in the past.
- **Secondary Infertility:** In these cases, at least one prior pregnancy or conception has been documented for the couple. However, despite having conceived before, they are now struggling to achieve another pregnancy.
- **Sterility:** In these cases, the cause of infertility has been identified and is deemed irreversible. In other words, the underlying reasons for the inability to conceive have been established, and there is no possibility for natural conception to occur.

Frequent Underlying Etiology of Infertility

1. **Female Factor:** Approximately 40% of infertility cases are attributed to factors related to the female reproductive system. These factors could include issues with ovulation, hormonal imbalances, fallopian tube blockages, uterine abnormalities, or other conditions that affect the ability to conceive.
2. **Male Factor:** Similarly, around 40% of infertility cases can be attributed to factors related to the male reproductive system. These factors might involve sperm-related issues such as low sperm count, poor sperm motility (movement), or abnormal sperm morphology (shape).
3. **Undetermined Etiology:** In a subset of cases (around 10-20%), despite medical evaluation, no clear cause for infertility can be identified. In other words, the underlying reason for the inability to conceive remains unknown even after diagnostic tests and examinations have been conducted.

Infertility Evaluation

1. **History and Physical Examination:** The evaluation of infertility begins with a thorough medical history and physical examination. This step aims to gather information about the individuals' medical background, lifestyle, and potential factors that might contribute to infertility. The physical examination helps identify any visible abnormalities or signs that could provide insights into the underlying causes.
2. **Sexual History:** Obtaining a detailed sexual history is also crucial in understanding a couple's sexual habits and practices, including information about the *frequency* and *timing* of sexual intercourse, as well as any factors that might affect fertility, such as the use of lubricants that could potentially impact sperm viability.
3. **Menstrual History:** A complete menstrual history for the female partner is also important, and will involve tracking the regularity and characteristics of menstrual cycles. Irregular menstrual cycles or abnormalities in menstruation could indicate hormonal imbalances or other issues affecting fertility.

Questions may be used to assess menstrual patterns:

Menstrual cycle duration:

- How long is your menstrual cycle on average?
- Is it typically within the range of 21 to 35 days, or does it fall outside this range?

Duration of menstrual bleeding:

- How many days does your menstrual bleeding usually last?
- Does it typically last between 2 to 7 days?

Presence of associated symptoms or pain:

- Do you experience any symptoms or pain during your menstrual period?
- If yes, when do these symptoms or pain occur?

Timing of symptoms/pain:

- Are the symptoms or pain experienced before, during, or after your period?

How pain is described:

- What are these symptoms or pain commonly referred to as?

Occurrence of spotting:

- Do you experience any spotting between your menstrual periods?
- When does this spotting typically occur in relation to your menstrual cycle?
- Do you think there is any potential significance or reasons for the spotting?
- Are there any specific factors or medical conditions that may be causing the spotting episodes?

Answering these questions can help gauge the characteristics of a menstrual cycle and provide insights into whether it falls within the typical or atypical range. If any concerns or irregularities are identified, it's advisable to consult with a healthcare professional for further evaluation and guidance.

Male Infertility Evaluation

There are several tests that offer insights into various aspects of sperm functionality and quality and help to identify specific factors that might be contributing to male infertility and aid in tailoring appropriate treatment strategies. Based on the results, further evaluations and discussions with a healthcare provider can lead to appropriate treatment or interventions that should be pursued.

Semen Analysis

Semen analysis is typically the initial diagnostic step when assessing infertile couples and excluding male infertility factors. This test provides crucial insights into the quality and quantity of sperm present in the semen.

Semen samples can be collected either at a laboratory or at home. If collected at home, the sample should be transported to the laboratory within 30 minutes to ensure accurate results. Men are advised to abstain from ejaculation for 48 to 72 hours before collecting the semen sample to ensure that the sample contains an adequate concentration of sperm.

The first milliliter of the ejaculate typically contains the highest concentration of spermatozoa, so it's important to include this portion in the sample. To account for natural variability in semen quality, at least two specimens should be examined on different occasions, several weeks apart. Parameters analyzed are as follows:

- A healthy sperm concentration is considered to be greater than 20 million sperm per milliliter of semen.
- The total count of sperm in the ejaculate should be above 60 million.
- The volume of the ejaculate should be more than 2.5 milliliters.
- More than 50 million sperm should exhibit motility.
- At least 50% of the sperm should be viable (alive).
- Over 60% of the sperm should exhibit normal morphology (shape).

Anti-sperm Antibody Assays

Antisperm antibodies are antibodies that target sperm cells. They can be present in either the male or female partner and may contribute to fertility impairment. These antibodies can interfere with sperm function and motility, making it difficult for sperm to reach and fertilize the egg. Assays to detect the

presence of anti-sperm antibodies, semen, blood, and vaginal fluids that fight off sperms help identify this potential factor in infertility.

Hamster Egg Penetration Test (HEPT)

The HEPT is a laboratory test used to predict the fertilizing capability of spermatozoa. It involves exposing sperm to hamster eggs and observing their ability to penetrate the egg's membrane. This test provides insights into whether sperm can successfully penetrate the egg, which might not be evident through a standard semen analysis. It evaluates factors related to the interaction between sperm and the egg's outer layer.

Sperm DNA Fragmentation Assays

Sperm DNA fragmentation assays assess the integrity of sperm DNA. High levels of DNA fragmentation can indicate damaged genetic material within sperm cells. This damage could impact the development of normal embryos and lead to fertility issues. These assays help predict the likelihood of successful embryo development.

Post Coital Test (PCT)

PCT provides insights into the interaction between sperm and cervical mucus, which is important for transporting sperm through the reproductive tract. The test should not replace a comprehensive semen analysis but serve as a supplemental assessment to evaluate specific aspects of fertility.

The PCT is typically performed during the midcycle, the period in which there is high water content in cervical mucus and the midcycle estrogen surges. This timing is chosen because cervical mucus plays a crucial role in facilitating sperm transport. The couple should engage in sexual intercourse between 8 to 24 hours prior to presenting at the clinic for the test.

PCT examines cervical mucus under a microscope to determine the presence of several progressively motile spermatozoa per high-powered field. This assessment helps evaluate sperm's ability to move effectively in the cervical environment. It can screen for the presence of anti-sperm antibodies and the adequacy of the couple's sexual activity. For example, the presence of clumpy sperm or flagellate without motility might indicate the presence of anti-sperm antibodies originating from either mucus or semen. In cases where few or no sperm are detected, potential factors to consider include improper timing of the test, oligospermia (low sperm count), suboptimal coital technique, hypospadias, the presence of anti-sperm antibodies, or the presence of naturally occurring hostile cervical mucus.

Female Infertility Evaluation

Ovarian Factor

There are several methods to detect the presence of ovulatory cycles. By employing these methods, healthcare professionals can assess and detect potential ovarian factors contributing to infertility.

1. **Monitoring Menstrual Cycles:** Regular menstrual cycles, accompanied by premenstrual symptoms, often serve as a reliable indicator of ovulation.
2. **Basal Body Temperature (BBT) Tracking:** A BBT increase of at least 0.4°F over the temperature recorded during the proliferative phase is generally considered within the normal range, suggesting the occurrence of ovulation.
3. **Serum Progesterone Analysis:** Obtaining a single serum progesterone value above 4 ng/ml between days 19 and 23 of the menstrual cycle can be indicative of ovulation.
4. **Urinary LH Surge Assessment:** The measurement of urinary luteinizing hormone (LH) surge, accomplished through various commercially available ELISA home test kits, can prospectively predict both the presence and timing of ovulation. These tests help identify the surge in LH, a hormone that triggers ovulation.

On the other hand, monitoring the common **causes of anovulation** can also be detected through physical examination and clinical assessment.

Frequent Causes of Anovulation

1. **Fluctuations in Body Weight:** Anovulation can occur due to significant deviations in body weight, both in cases of excessive weight gain and extreme weight loss.
2. **Polycystic Ovary Syndrome (PCOS):** Chronic hyperandrogenic anovulation, often associated with PCOS, is a common cause of disrupted ovulation patterns.
3. **Emotional Stress:** High levels of emotional stress can disrupt the regularity of menstrual cycles, leading to anovulation.
4. **Medications:** Certain medications, especially those affecting hormone levels, can contribute to anovulation.
5. **Systemic Illness:** Chronic or severe systemic illnesses can disrupt the body's hormonal balance, potentially leading to anovulation.
6. **Structural Lesions Affecting the Hypothalamic-Pituitary-Ovarian Axis:** Structural

abnormalities in the hypothalamic-pituitary-ovarian axis can hinder the normal ovulatory process.

7. **Initial Blood Tests:** Initial blood evaluations should typically include measuring thyroid-stimulating hormone (TSH) and prolactin levels routinely. Additionally, assessing follicle-stimulating hormone (FSH) levels and total testosterone can provide valuable insights into the underlying issues.
8. **Serial Ultrasound Examinations:** Serial ultrasound examinations are often conducted to monitor and ascertain the collapse of ovarian follicles. This helps in tracking the development and release of eggs during the menstrual cycle, aiding in the diagnosis and management of anovulation-related issues.

Tubal Factor

It's important to consider that approximately 20-30% of cases can be attributed to pelvic abnormalities, such as tubal occlusion, adhesions, and severe endometriosis.

One diagnostic approach to rule out tubal factor infertility is the use of a **Hysterosalpingogram** (HSG). This diagnostic test should ideally be conducted relatively early in the infertility investigation, following a semen analysis.

The primary purposes of an HSG are:

1. **Evaluation of Tubal Patency:** Using transuterine water-soluble contrast instillation under fluoroscopic visualization helps assess whether the fallopian tubes are open and unobstructed.
2. **Assessment of Uterine Cavity:** Additionally, the HSG can provide valuable information about the contour and adequacy of the uterine cavity.

Hysterosalpingogram (HSG) is typically performed in the follicular phase of the menstrual cycle before ovulation. In cases where the HSG results are inconclusive or further investigation is warranted, laparoscopy may be recommended.

Laparoscopy

Laparoscopy is a surgical procedure that allows for a direct visual examination of the pelvic organs. It can provide a more detailed assessment of pelvic abnormalities, including the condition of the fallopian tubes, adhesions, and endometriosis. Diagnostic laparoscopy involves the insertion of a fiberoptic scope through small incisions into the abdominal cavity, and is typically performed under general anesthesia.

During a diagnostic laparoscopy procedure, here's what you can generally expect:

1. **Exploration of the Pelvis:** Laparoscopy allows the surgeon to explore and visually examine the pelvic region. This can provide insights into potential causes of infertility, such as pelvic adhesions, endometriosis, or structural abnormalities.
2. **Hysteroscope for Uterine Cavity Examination:** In some cases, a hysteroscope (a thin, lighted tube with a camera) can also be utilized during laparoscopy to examine the uterine cavity. This helps in assessing the condition of the uterine lining and identifying any abnormalities.
3. **Transvaginal Contrast Injection:** To assess the patency of the fallopian tubes, a contrast dye can be injected through the cervix transvaginally via a canula. This allows for the visualization of dye passing through the fimbriated ends of patent (open) fallopian tubes when observed laparoscopically.

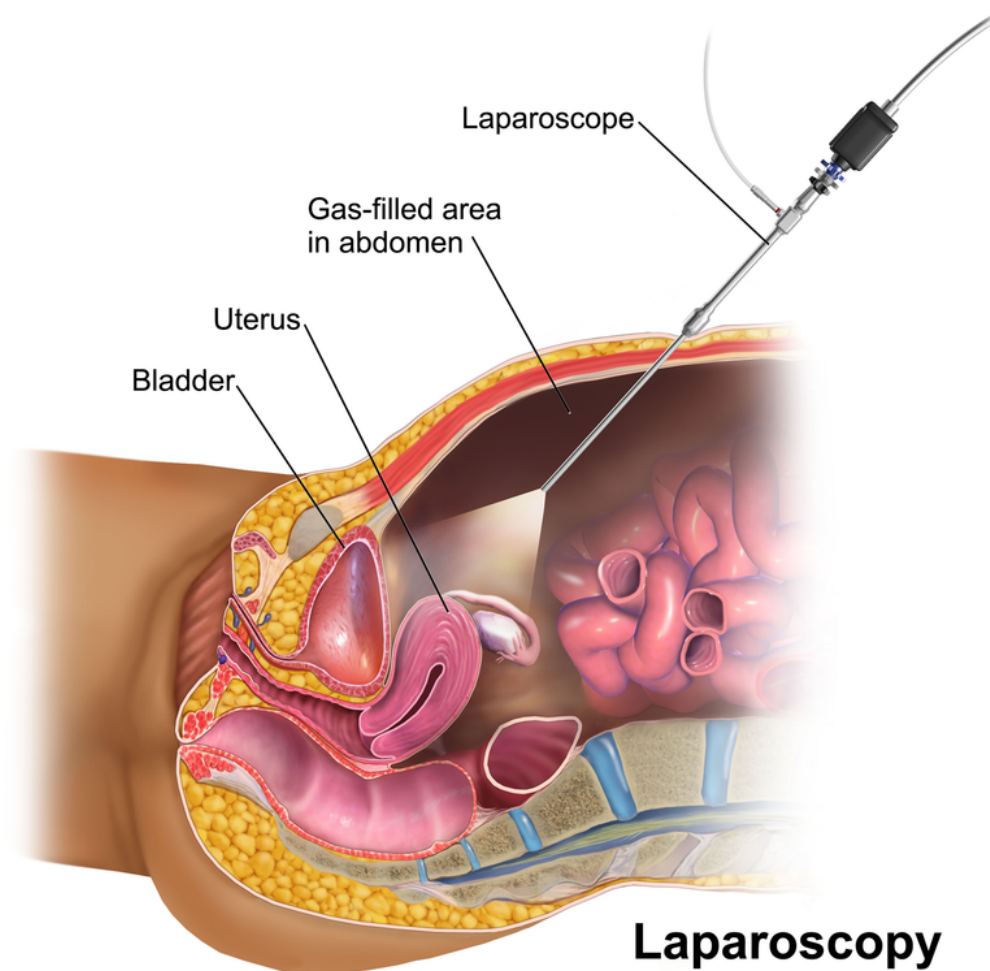


Figure 1. Illustration of a laparoscopy.

Endometrial Factor

An **endometrial biopsy** can be used to assess endometrial factors. In the context of evaluating female infertility, it is crucial to consider the quality of the endometrium, which must be suitable to facilitate implantation. If it is not, this condition is referred to as luteal phase inadequacy (LPI). The assessment of endometrial factors involves:

1. **Histological Pattern of the Endometrium:** This assessment is based on the development of endometrial glands and stroma. An office biopsy procedure is typically performed using an endometrial sample collected from the upper part of the uterus just before the onset of menstrual bleeding.
2. **Discrepancy in Timing:** To diagnose luteal phase inadequacy, a significant discrepancy of 2 or more days from the norm for the day the biopsy was taken. Consistency must be observed in two consecutive menstrual cycles. The diagnosis of luteal phase inadequacy is established when there is a consistent discrepancy in endometrial development over two consecutive cycles.

Cervical Factor

When assessing cervical factor infertility, a sample of cervical mucus is typically collected at **midcycle**, which is the time of ovulation. The evaluation involves the following steps:

1. **Sample Collection:** A small sample of cervical mucus is carefully aspirated (drawn into a pipette or tube) during the midcycle, which corresponds to the fertile window when ovulation is likely to occur.
2. **Slide Preparation:** The collected cervical mucus is placed on a glass slide.
3. **Cover Slip Application:** A cover slip is applied to the glass slide, covering the cervical mucus sample.
4. **Stretchability Measurement:** The degree to which the cervical mucus stretches is assessed. This is done by gently lifting the cover slip and observing how far the mucus extends before breaking.
5. **Optimal Stretch Length:** In the assessment, cervical mucus that stretches into columns measuring 8 centimeters or more is considered optimal for fertility. This indicates good quality cervical mucus that is conducive to sperm transport through the cervix and into the uterus.
6. **Microscopic Examination:** In addition to the stretchability assessment, the cervical mucus can also be examined microscopically. Good-quality mucus appears acellular under the microscope, meaning it doesn't contain many cells or debris. Furthermore, when dried on a slide, it forms a fern leaf-like pattern. This characteristic ferning pattern is indicative of high sodium chloride (salt) content in the mucus.

The assessment of cervical mucus quality plays a significant role in fertility evaluation, as it affects sperm transport and survival within the female reproductive tract. Healthy cervical mucus provides an environment that supports sperm motility and facilitates the journey of sperm to meet the egg for fertilization.

Image Sources

- **Figure 1.** “Laparoscopy” is from [BruceBlais via Wikimedia Commons](#), licensed [CC BY 3.0](#).

Infertility Treatment

Male Factor Infertility Treatment

Addressing male factor infertility entails a range of therapeutic strategies. Several typical methods for managing male factor infertility include:

1. **Hormonal Evaluation:** a thorough evaluation of the hypothalamic-pituitary-testicular hormonal axis is essential. This includes measuring hormone levels such as luteinizing hormone (LH), follicle-stimulating hormone (FSH), and testosterone. Imbalances in these hormones can be corrected through hormonal therapy.
2. **Replacement Hormonal Therapy:** Hormone replacement therapy may be recommended to address hormonal imbalances or deficiencies. This can help restore testicular function and improve sperm production.
3. **Vas Deferens Patency:** The patency of the vas deferens (the tubes that carry sperm from the testicles) is assessed. In cases of vas occlusion or blockage, surgical correction can sometimes restore the flow of sperm, improving fertility.
4. **Epididymal Sperm Aspiration:** In situations where the vas deferens is blocked or absent, sperm can be directly aspirated from the epididymis. While this procedure can retrieve a limited number of sperm, it may be used in conjunction with other fertility treatments.
5. **Intracytoplasmic Sperm Injection (ICSI):** ICSI is an assisted reproductive technique where a single sperm is injected directly into an egg to facilitate fertilization. This method is particularly beneficial when sperm quality or quantity is a concern. It can be used in combination with procedures like sperm aspiration to achieve fertilization.

Female Factor Infertility Treatment

The treatment approach for female factor infertility is also tailored to the specific causes or etiologies identified. Some common treatment options for female factor infertility includes:

1. **Correction of Anatomical Defects:** Surgical procedures may be performed to correct anatomical issues in the reproductive organs impeding fertility. These defects can include conditions such as uterine fibroids, polyps, or blocked fallopian tubes.
2. **Luteal Phase Insufficiency Correction:** In cases of luteal phase insufficiency, which can affect the ability of the uterine lining to support a pregnancy, supplementation of progesterone during the

luteal phase can be employed to improve fertility.

3. **Intrauterine Insemination (IUI):** IUI involves the placement of washed sperm directly into the uterus, which increases the number of healthy sperm that can potentially reach and fertilize the egg. This method is often used when the cause of infertility is related to issues such as *cervical mucus* or *mild male factor infertility*.
4. **Ovulation Induction Drugs:** Ovulation induction drugs are prescribed to stimulate the release of eggs from the ovaries. These drugs can include:
 - **Clomiphene Citrate:** An inexpensive and commonly used medication that induces ovulation in over 90% of cases. However, pregnancy rates are around 65% due to other factors affecting fertility.
 - **Human Menopausal Gonadotropins (hMG):** These medications, such as Pergonal, are more expensive and administered by injection (intramuscular or subcutaneous). They carry a higher risk of multiple gestations (15-35%) and are often used in more complex cases.
 - **Glucocorticoids:** Used to address certain hormonal imbalances that may be impacting fertility.
 - **Metformin:** Prescribed for women with polycystic ovary syndrome (PCOS) to regulate insulin and improve ovulatory function.

The choice of treatment depends on the specific causes of infertility identified through diagnostic testing. Fertility specialists work with patients to develop a personalized treatment plan to address their unique circumstances and improve their chances of conceiving.

Assisted Reproductive Techniques

Assisted Reproductive Technologies (ART) refer to a group of medical procedures and techniques designed to help individuals or couples achieve pregnancy when traditional methods have not been successful. Several notable assisted reproductive technologies include:

In Vitro Fertilization (IVF)

IVF is one of the most well-known ART methods. It involves the extraction of eggs from the ovaries, fertilizing them with sperm in a laboratory dish, and then transferring the resulting embryos into the uterus. IVF can be used for various fertility issues, including blocked fallopian tubes, male factor infertility, or unexplained infertility.

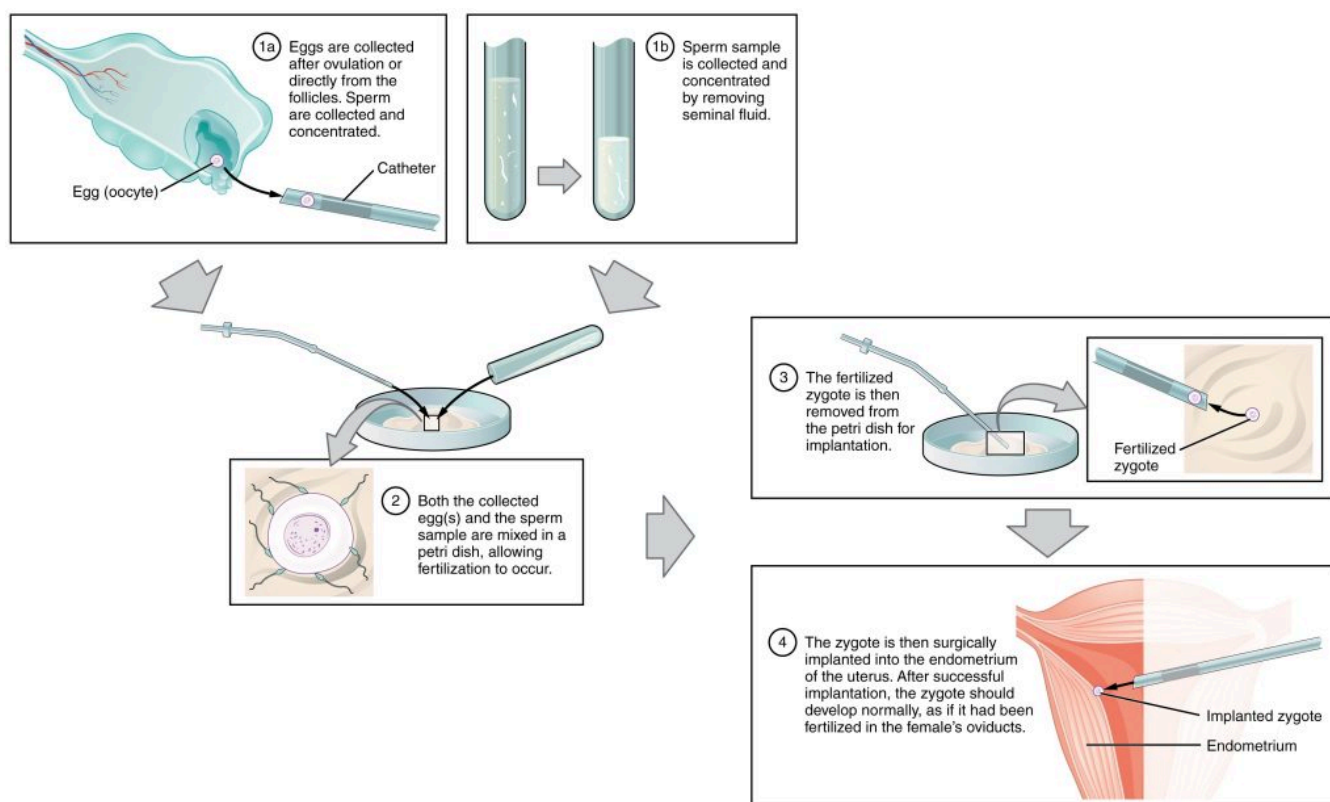


Figure. 1. In vitro fertilization involves egg collection from the ovaries, fertilization in a petri dish, and the transfer of embryos into the uterus.

Embryo Cryopreservation

After IVF, excess embryos can be frozen (cryopreserved) for future use, allowing multiple attempts at pregnancy without repeating the ovarian stimulation and egg retrieval process.

Intracytoplasmic Sperm Injection (ICSI)

ICSI is a specialized form of IVF where a single sperm is injected directly into an egg to facilitate fertilization. This method is particularly effective in cases of severe male factor infertility or when prior IVF attempts have not been successful.

Gamete Intrafallopian Transfer (GIFT)

GIFT is a technique in which eggs and sperm are collected and placed into the fallopian tubes, allowing fertilization to occur inside the woman's body. It is less commonly used today due to the popularity of IVF.

Zygote Intrafallopian Transfer (ZIFT)

ZIFT is similar to GIFT, but it involves the transfer of fertilized embryos (zygotes) into the fallopian tubes. This procedure is also less common than IVF.

Intrauterine Insemination (IUI)

IUI involves placing washed and concentrated sperm directly into the uterus, bypassing the cervix. It is often used for mild male factor infertility or when the cervix is a barrier to conception.

Donor Gametes

Donor sperm or eggs can be used when one partner is unable to provide viable gametes. This is often employed in cases of severe male or female infertility.

Preimplantation Genetic Testing (PGT)

PGT involves testing embryos for genetic abnormalities before transferring them into the uterus. It can help reduce the risk of passing on certain genetic conditions.

Surrogacy

In gestational surrogacy, another woman carries and gives birth to a baby for the intended parents, often using ART to achieve pregnancy. Traditional surrogacy involves the surrogate providing both the egg and carrying the pregnancy.

Assisted reproductive technologies have revolutionized the field of fertility treatment, offering hope to individuals and couples facing infertility. They are complex, highly regulated, and require the expertise of fertility specialists to ensure safe and successful outcomes. However, the cost of assisted reproductive technologies (ART) is very expensive and can vary significantly depending on the specific procedures, geographic location, and individual circumstances.

Image Sources

- **Figure. 1.** “In vitro fertilization” is from [OpenStax Anatomy & Physiology](#), licensed [CC BY 4.0](#). Access for free at <https://openstax.org/books/anatomy-and-physiology-2e/pages/1-introduction>

Sexual Transmitted Diseases

Sexually Transmitted Diseases

Sexual contact serves as a means of transmitting a diverse range of microorganisms. While many of these microorganisms are capable of establishing themselves in the genital region, they typically do not lead to any diseases. However, a select few of these microorganisms, capable of causing illnesses, are classified as sexually transmitted diseases (STDs).

Consequences of STDs

The consequences of STDs can encompass various health issues, including:

1. **Increased Severity of Genital Lesions:** STDs can lead to larger and more destructive genital lesions, causing discomfort and potentially affecting the overall health of the affected individual.
2. **Infertility:** Some STDs may result in infertility due to complications such as fallopian tube occlusion. This can hinder a person's ability to conceive.
3. **Weakened Immune System:** Certain STDs can compromise the immune system, especially in individuals undergoing treatments like chemotherapy or taking immunosuppressant drugs. This makes them more susceptible to infections and other health complications.
4. **Vertical Transmission:** In the case of pregnant individuals, some STDs can be transmitted to the neonate during pregnancy (antepartum) or during childbirth (intrapartum). This can lead to health issues in the newborn, necessitating medical attention.

STD Transmission

Sexually transmitted diseases (STDs) can be transmitted through various means, including:

1. **Sexual Contact:** As previously mentioned, STDs are primarily transmitted through sexual contact, including vaginal, anal, and oral intercourse with an infected partner.
2. **Blood Contact:** Sharing needles or engaging in intravenous drug use can expose individuals to bloodborne STDs like HIV and hepatitis B and C.
3. **Non-Sterilized Surgical Instruments:** Inadequately sterilized surgical instruments can pose a risk of transmitting bloodborne infections, particularly in healthcare settings.
4. **Mother-to-Child Transmission:** Some STDs, such as syphilis and HIV, can be transmitted from an infected mother to her baby during pregnancy, childbirth, or breastfeeding.
5. **Hand Contact:** While less common, some STDs, like human papillomavirus (HPV) and molluscum

contagiosum, can theoretically be transmitted through skin-to-skin contact or contact with contaminated surfaces. However, this mode of transmission is less likely compared to sexual contact.

6. **Inanimate Objects:** The risk of STD transmission from inanimate objects, such as toilets or doorknobs, is very low. Most STDs do not survive long outside the human body, making transmission through inanimate objects highly unlikely.

Correct and consistent use of latex condoms is an effective method for reducing the risk of STD transmission during sexual activity. Condoms provide a barrier that helps prevent direct contact with infected bodily fluids. Therefore, it's crucial to practice safe sex, get regular screenings, and seek prompt medical treatment when needed to prevent or manage the complications associated with STDs.

Bacterial Sexually Transmitted Infections and Diseases

Some sexually transmitted diseases (STDs) are caused by bacterial infections, while others result from viral infections. Below, some of the most prevalent bacterial sexually transmitted diseases (STDs) are described.

Gonorrhea

Gonorrhea is an STD that is caused by a sexually transmitted bacterium. The bacterium specifically associated with gonorrhea is known as *Neisseria gonorrhoeae*. This bacterium is mainly spread via sexual contact such as vaginal, anal, or oral sex. The bacterium can infect the vagina, urethra, paraurethral glands, and Bartholin glands, causing purulent inflammation of each.

In females, *Neisseria gonorrhoeae* can ascend to the cervix, uterine canal, and fallopian tubes, potentially causing inflammation and pain. In males, it can spread to the prostate and testis, leading to similar symptoms. Moreover, the bacterium can disseminate to other parts of the body, including the eyes, throat, rectum, and joints, causing inflammation even in these regions. Importantly, in many cases, there may be no symptoms associated with gonorrhea, although it is still transmissible.

Regardless of symptoms, treatment is highly recommended for all sexual partners involved to prevent further infection or complications. If left untreated, gonorrhea can lead to serious issues, such as pelvic inflammatory disease (PID) and infertility in women, as well as epididymitis and infertility in men. Additionally, it can be transmitted during **childbirth**, potentially causing neonatal conjunctival infection. Early detection and treatment are essential to mitigate the consequences of gonorrhea and reduce its spread.

Chlamydia

Chlamydia is the most prevalent sexually transmitted infection (STD) caused by the bacterium *Chlamydia trachomatis*. It is a frequent culprit behind conditions like pelvic inflammatory disease (PID) and infertility, with many cases being asymptomatic.

Chlamydia tends to affect the urethra and cervix, often resulting in discharge. There is a notable link

between Chlamydia infection and an increased risk of cervical cancer. Furthermore, individuals exposed to Chlamydia have a heightened susceptibility to contracting HIV.

During **childbirth**, Chlamydia can lead to neonatal lung and eye infections in the newborn. Due to these potential complications and the risk of transmission, it is strongly recommended that both partners receive treatment for Chlamydia. Early diagnosis and appropriate management are crucial for preventing adverse outcomes and reducing the spread of this common STD.

Syphilis

Syphilis, caused by the bacterium *Treponema pallidum*, is primarily transmitted through sexual contact. This complex disease presents several distinct stages and symptoms:

1. **Primary Stage:** It often begins with a firm, painless ulcer at the site of infection, which may not always be clinically apparent.
2. **Secondary Stage:** In this stage, gray, flattened, wart-like lesions can develop on various parts of the body. It marks the systematic spread of the infection throughout the body, leading to tissue damage.
3. **Tertiary syphilis:** a severe stage of the disease, typically manifesting 10 to 30 years after the initial infection. During this stage, syphilis can cause significant damage to internal organs, including the brain (**Neurosyphilis**), potentially leading to life-threatening complications.
4. **Congenital Syphilis:** When pregnant individuals are infected, the bacterium can **cross the placenta** as early as six months into pregnancy, causing intrauterine fetal malformation and birth defects in the unborn child.

The good news is that syphilis is curable, especially when detected and treated early. Timely treatment with antibiotics can effectively eradicate the infection and prevent its progression to more severe stages.

Viral Sexually Transmitted Infections and Diseases

Herpes Simplex Virus (HSV)

Herpes Simplex Virus (HSV) differs from the STDs we've discussed thus far, as it is a viral infection. HSV is transmitted through sexual contact and is more commonly observed in men than in women. This virus has various types, with HSV Type 2 being the most prevalent. Once an individual contracts HSV, the virus remains with them for life.

Symptoms of HSV include the formation of small vesicles and shallow ulcers on the cervix, urethra, and perineum. Those who have never been previously infected with HSV often experience more severe symptoms.

In cases where the HSV virus comes into contact with an individual's eyes, it can lead to blindness. Additionally, individuals with HSV have a heightened risk of developing cervical cancer. Pregnant women with HSV must exercise caution, as exposure of the fetus to HSV **during birth** can result in blindness or brain damage for the baby.

While it is possible to manage HSV to reduce the frequency and duration of outbreaks, it is not completely curable.

Human Papilloma Virus (HPV)

HPV, a DNA virus belonging to the Papillomaviridae family, encompasses over 200 distinct types. Approximately 40 of these variants are recognized for their ability to infect the genital region, giving rise to a variety of clinical conditions. The majority of HPV infections manifest without symptoms. However, certain HPV strains can instigate the formation of genital, anal, or surrounding warts, characterized by their raised, flat, or cauliflower-like appearance. Notably, high-risk HPV types have the potential to induce abnormal cell changes in the cervix, and in some instances, these changes may progress to cervical cancer. The administration of the HPV vaccine, such as Gardasil, can effectively thwart infection by some of the most dangerous HPV types, subsequently reducing the risk of cervical cancer.

Much like other sexually transmitted infections (STIs), HPV is primarily transmitted through sexual contact and bodily secretions. Additionally, this virus can be passed from an infected mother to her newborn during the process of **childbirth**. Infants exposed to HPV during delivery may be susceptible

to recurrent respiratory papillomatosis, a condition marked by the growth of warts in the airway, leading to respiratory difficulties.

While there is no cure for the HPV virus itself, HPV warts can be effectively managed through a range of treatment options. These include topical treatments in the form of creams, cryotherapy (which involves freezing the warts with liquid nitrogen), electrocautery (a method of burning off warts using an electrical current), and surgical removal by cutting out the affected warts. Regular monitoring and treatment are essential, often facilitated through pap smears conducted to detect abnormalities.

Human Immunodeficiency Virus (HIV) and Pregnancy

Human Immunodeficiency Virus (HIV) is classified as a **retrovirus**, a virus that carries RNA as its genetic material. It employs an enzyme known as reverse transcriptase to convert its RNA into DNA once it infiltrates a host cell. This newly generated viral DNA becomes integrated into the host's genetic material, allowing for replication and the production of additional virus particles.

HIV primarily targets immune system cells, particularly CD4+ T cells, leading to immune system impairment. In adults infected with HIV, a spectrum of symptoms may manifest, including flu-like indicators such as fever, fatigue, and swollen lymph nodes. If left untreated, HIV can progress to **Acquired Immunodeficiency Syndrome (AIDS)**, resulting in more severe health issues.

HIV shares common modes of transmission with other STI organisms. It can be transmitted from an infected mother to her newborn during childbirth, through breastfeeding, or during pregnancy. Newborns who acquire the virus may exhibit symptoms like **failure to thrive** with difficulty gaining weight or growing at a normal rate, **recurring infections**, including respiratory infections, ear infections, and gastrointestinal issues, **and developmental delays**, both physical and cognitive.

Nevertheless, with appropriate medical care and precautions, HIV-infected individuals can still give birth to healthy babies. Key steps and interventions for ensuring a healthy pregnancy include:

- The prescription of **antiretroviral medications** for HIV-positive individuals during pregnancy, labor, and postpartum to reduce viral load and prevent transmission to the baby.
- **Regular prenatal care**, including the monitoring of viral load and CD4 cell counts, to enable healthcare providers to make treatment adjustments as needed for the well-being of the mother and the baby.
- In some cases, a **scheduled cesarean section** may be recommended to reduce the risk of HIV transmission during childbirth, with the decision contingent on the mother's viral load and other factors.
- HIV-positive mothers are **advised not to breastfeed**, as HIV can be transmitted through breast milk. Instead, safe and appropriate alternatives for infant feeding are suggested to avoid transmission to the newborn. Promoting education, awareness, and access to testing and treatment are pivotal for protecting both adults and newborns from HIV.
- After birth, the infant may receive **antiretroviral prophylactic medications** to decrease the risk of transmission.

By adhering to these guidelines and working closely with healthcare providers, HIV-positive pregnant people can significantly minimize the risk of HIV transmission from mother to baby, thereby ensuring the best possible outcome for both.

Pelvic Pain

Pelvic Pain

Pelvic pain can have many causes, including the digestive, urinary, or reproductive system. It may be attributed to factors such as ovulation, dysmenorrhea, or sexually transmitted diseases (STDs), among others. Given the diverse range of underlying causes, various treatment options are available to address these symptoms. We will explore several reproductive factors and conditions linked to pelvic pain and discomfort in this chapter.

Pelvic pain unrelated to pregnancy

Menstrual-related pain

Pelvic pain that is unrelated to pregnancy may be caused by ovulation or dysmenorrhea. Pain around the time of ovulation can occur for a few hours and may last 2 days.

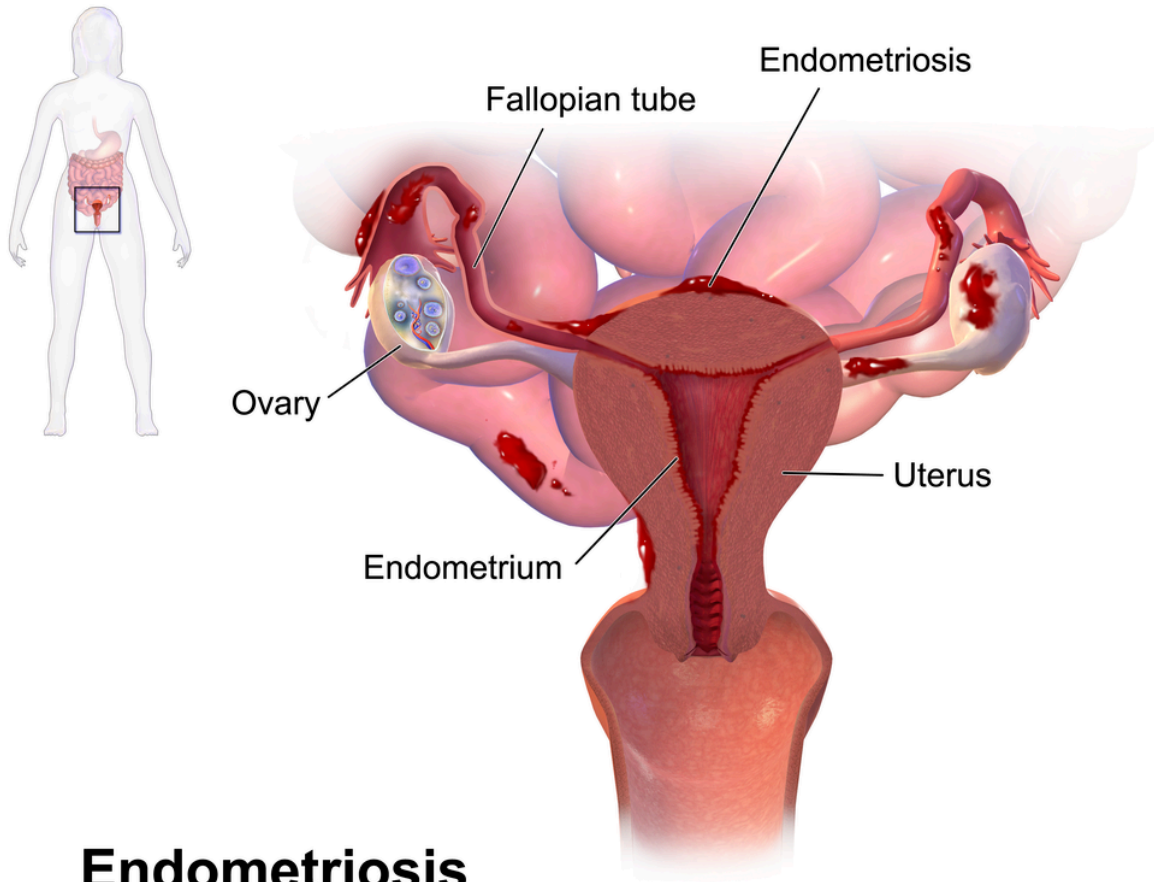
Dysmenorrhea is severe pain caused by menstrual cramps. It is theorized that excess prostaglandin causes smooth muscle contractions, leading to dysmenorrhea. These painful menses are typically observed in the first five years of ovulatory menstrual cycles, and improve with age. Dysmenorrhea affects over 50% of all post-pubescent women. To manage the pain, prostaglandin inhibition or the suppression of cycles is sought. Other methods for managing the pain include the use of heat, mild analgesics, and exercise.

Pelvic Inflammatory Disease PID

Pelvic inflammatory disease (PID) is an infection affecting the female reproductive system, typically resulting from pelvic infections transmitted through sexual contact, such as gonorrhea or chlamydia. The use of an intrauterine device (IUD) for contraception can also elevate the risk of PID. On the other hand, oral contraception may offer some protection, as it disrupts cervical secretions and hinders the attachment of these organisms to endometrial cells. PID, if left untreated, can lead to severe complications, including chronic pain, infertility, ectopic pregnancies, and, in extreme cases, even death.

Endometriosis

Endometriosis is when tissue that normally lines the endometrium grows outside of the uterus, causing pelvic pain (See Figure 1). This can occur at any time throughout female reproductive years.



Endometriosis

Figure 1. Endometriosis.

Endometriosis can cause cyclic pain, dysmenorrhea, and severe dyspareunia, or painful intercourse. If a female has endometriosis, she has a 30-40% chance of being infertile. Endometriosis can cause a female to become infertile by trapping the ovum, or the cytokine and prostaglandin production that may interrupt the ovulation, tubal function, and luteal phase detection. Management of endometriosis typically involves treatment through hormonal therapies or excision surgery.

Reproductive Tumor

Reproductive tumors, such as ovarian (or testicular in males), uterine, or cervical tumors, can lead to pelvic pain. Several treatment options are available for reproductive tumors, including surgery, chemotherapy, radiation therapy, and targeted therapy. The choice of treatment depends on many factors, like the type and stage of the tumor, the patient's overall health, and individual preferences. It is paramount to stress the significance of early detection via regular screenings, immunization, and vaccination. Additionally, a proactive approach to understanding one's genetic predisposition and making lifestyle choices conducive to overall well-being can considerably reduce the risk of reproductive tumors and enhance long-term health.

Pelvic pain related to pregnancy

Pelvic pain in females related to pregnancy can be attributed to conditions such as abortions or ectopic pregnancies.

Abortions (Miscarriage)

Miscarriage, also referred to as pregnancy loss, is the spontaneous termination of a pregnancy before reaching the 20th week of gestation. It affects approximately 10-20% of known pregnancies and can occur due to various factors, including chromosomal irregularities, hormonal imbalances, and specific health conditions.

Symptoms of a miscarriage often include pelvic discomfort, which may range from mild to severe and is frequently accompanied by bleeding. Bleeding is a prevalent indicator of a miscarriage, varying in intensity from light spotting to heavy discharge. In some instances, the body naturally expels the pregnancy tissue without the need for medical intervention, a practice known as expectant management, commonly employed for early miscarriages.

In situations where the miscarriage is incomplete or presents complications, a healthcare provider may recommend medication to facilitate the expulsion of the remaining tissue. Alternatively, a surgical procedure, such as dilation and curettage (D&C) or aspiration, may be necessary to remove the pregnancy tissue.

To help individuals and couples navigate the emotional impact of pregnancy loss, grief counseling and participation in support groups can provide valuable assistance.

Ectopic Pregnancy

An ectopic pregnancy occurs when the implantation of a zygote takes place outside of the uterus or in an abnormal location within the uterus (See Figure 2). In 95% of ectopic pregnancies occur in the fallopian tubes, but they can also occur in the abdomen or cervix. The pain may be characterized as unilateral or generalized, crampy or sharp. Vaginal bleeding and spotting can also occur. Certain individuals may also encounter nonspecific symptoms, such as an unusual urge to defecate, which can occasionally overlap with common pregnancy signs.

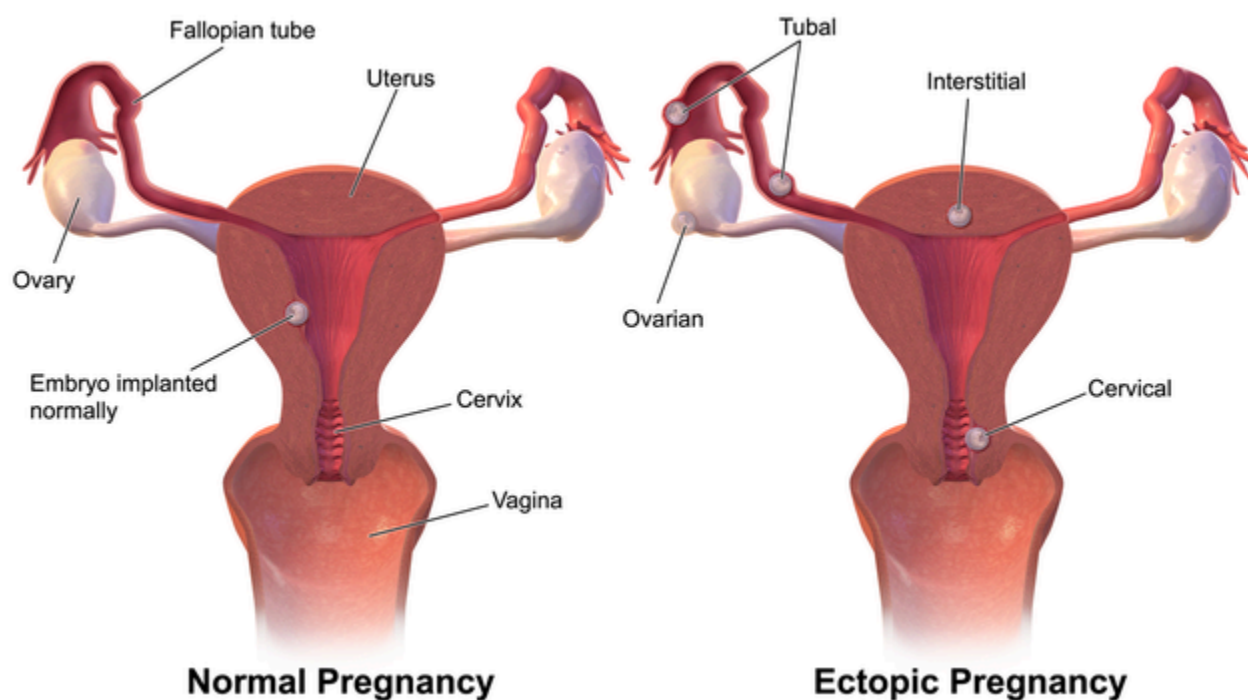


Figure 2. Ectopic Pregnancy.

The risk of an ectopic pregnancy is elevated in cases of a previous ectopic pregnancy, a history of pelvic infection (e.g., chlamydia and gonorrhea), the use of an intrauterine device (IUD), the presence of endometriosis, or factors that impede ovum transport, including the use of oral contraceptive pills (OCP) or smoking.

Image Sources

- **Figure 1.** “Endometriosis” is from [Bruce Blaus via Wikimedia Commons](#), licensed [CC BY 3.0](#).
- **Figure 2.** “Ectopic Pregnancy” is from [Bruce Blaus via Wikimedia Commons](#), licensed [CC BY SA 4.0](#).

About the Author

Hala F. Bastawros, M.D.

Dr. Bastawros, the primary author of this volume, earned her M.D. from Cairo University School of Medicine, Cairo, Egypt, in 1992, and obtained her USA Medical Certificate in 1999. With extensive experience in internal medicine, she has practiced in numerous teaching facilities. Dr. Bastawros is well-versed in instructing clinical signs, pathophysiology, and the effective management of various diseases. Since 2008, Dr. Bastawros has been an esteemed faculty member at Iowa State University, dedicating her efforts to educating pre-health professional career students. Over the years, she has provided guidance to numerous pre-medical students during their rotations and has also delivered courses on basic science with clinical orientation, emphasizing at Human Anatomy and Human Reproduction.

Reviewers

This book underwent an internal peer review process with input from subject matter experts from Iowa State University. Reviewers structured their feedback around a rubric, rating the text on various aspects of its organization and content. The rubric was adapted from the [Open Textbook Library's Review Rubric](#).

Peer Reviewers

Renu Srivastava

Renu Srivastava is an Assistant Teaching Professor in Genetics, Development, and Cell Biology at Iowa State University. She instructs introductory Human Biology courses, and her teaching and research interests converge on integrating student-centered pedagogy with contemporary techniques of biological research within the classroom setting.

Eric R. Henderson

Eric R. Henderson is a Professor in Genetics, Development, and Cell Biology at Iowa State University. He is an educator specializing in introductory biology courses, where his passion for fostering a foundational understanding of biological principles shines. Beyond the classroom, his research explores the dynamic intersection between biology and nanotechnology, commonly recognized as bionanotechnology or synthetic biology. This research delves into the intricate relationship between life and technology, reflecting a commitment to pushing the boundaries of scientific exploration.